

OCT & RETINA

Marie-Bénédicte Rougier, MD, PhD, FEBO
Prof. Marie-Noëlle Delyfer, MD, PhD, FEBO
Prof. Jean-François Korobelnik, MD, FEBO
Bordeaux University Hospital, France



Edition

Edited by:

Laboratoires Théa
12 Rue Louis Blériot
63000 Clermont-Ferrand
Tel: +33 (0)4 73 98 14 36

Carl Zeiss Meditec France SAS
100 Route de Versailles
78160 Marly-le-Roi
Tel: +33 (0)1 34 80 21 00

The content of this brochure presents the views of the authors and does not necessarily reflect the opinions of Théa Pharmaceuticals and Carl Zeiss.

Design/Production: Elwood

All rights of translation, modification and reproduction, by any means whatsoever, reserved for all countries.

Any reproduction or representation, in whole or in part, by any means whatsoever, of the pages published in this work, done without the prior written consent of the publisher is prohibited and unlawful and constitutes copyright infringement. Solely reproductions intended strictly for the private use of the copier and not intended for collective use, as well as short analyses and citations justified by the scientific or informational nature of the work in which they appear, are permissible (French Law of 11 March 1957, articles 40 and 41 and French Penal Code article 425).

PREFACE

It is not excessive to say that retinal imaging has enjoyed a revolution in the last 15 years. The arrival and widespread use of optical coherent tomography (OCT) have revolutionised the diagnosis and follow-up of macular diseases. This revolution has been made possible thanks to technological advances [time-domain OCT (TD-OCT), then spectral-domain OCT (SD-OCT)] and thanks to the fact that they have become accessible to a large number of centres and physicians worldwide. This revolution has been driven by substantial progresses in treatments, especially with the arrival of corticosteroids and anti-VEGF administered by intravitreal (IVT) injections.

Almost 10 years have now past since the initial widespread use of IVT injections and almost 7 years since the marketing of SD-OCT. We thought that it would be of interest to produce a book depicting a number of characteristic images of macular diseases. In collaboration with Marie-Bénédicte ROUGIER, MD, PhD and Marie-Noëlle DELYFER, MD, PhD we have collected the most typical and interesting cases, without seeking to include all of the possible macular diseases. The reader will browse this book and will easily be able to recognise some diseases, keeping in mind that an accurate and complete analysis of all OCT images is required. In fact, in everyday practice, it is easier just to quickly study one single OCT scan, which is a potential source of error. Indeed, it is not one single OCT image but numerous sections that need to be analysed, together with retinal mapping and “en-face” OCT images. These OCT images must be carefully correlated with the fundus examination (posterior pole and periphery), the visual acuity, and the patient's medical history in order to make the correct diagnosis and the appropriate treatment decision. Depending on the case, other imaging techniques may complement OCT, such as retinal fluorescein and indocyanine green angiographies, or autofluorescence retinal imaging.

We are grateful to ZEISS and Laboratoires Théa who supported this initiative and permitted the free distribution of this book. We hope that it will help refresh your knowledge of diseases of the retina.

We hope you will enjoy reading this book.

Jean-François KOROBNIK, MD, FEPO

Professor of Ophthalmology

Head of the Department of Ophthalmology of Bordeaux University Hospital

jean-francois.korobelnik@chu-bordeaux.fr



We would like to thank Brigitte Gontier (orthoptist), France Combillet and Marion Blaizeau (fellows) as well as Yona Geismar, Marion Gilles, Camille Seguy and Antoine Robinet-Perrin (residents) for their help in producing these images.

Table of Contents

1. Optical coherence tomography in healthy subjects	p. 13
2. Diseases of the vitreoretinal interface	p. 17
2.1. Vitreomacular traction	p. 18
2.2. Macular hole	p. 20
2.3. Lamellar hole	p. 26
2.4. Epimacular membrane	p. 28
3. Macular oedemas	p. 33
3.1. Diabetes	
3.1.1. Focal macular oedema	p. 34
3.1.2. Mixed macular oedema	p. 40
3.1.3. Diffuse macular oedema	p. 42
3.1.4. Tractional macular oedema	p. 44
3.1.5. Mixed maculopathy (oedematous and ischaemic)	p. 46
3.2. Retinal vein occlusion	
3.2.1. Central vein occlusion	p. 48
3.2.2. Branch vein occlusion	p. 50
3.3. Retinal artery occlusion	
3.3.1. Central artery occlusion	p. 52
3.3.2. Branch artery occlusion	p. 54
3.4. Inflammation	
3.4.1. Uveitis	p. 56
3.4.2. Irvine-Gass syndrome	p. 60
4. Macular telangiectasia	p. 63
5. AMD	p. 69
5.1. Early onset AMD or ARM	
5.1.1. Serous drusen	p. 70
5.1.2. Reticular drusen	p. 76
5.1.3. Cuticular drusen	p. 80
5.2. Atrophic AMD	p. 82
5.3. Exudative or neovascular AMD	
5.3.1. Typical forms	
5.3.1.1. Active forms	p. 90
5.3.1.2. Cicatricial forms	p. 96
5.3.1.3. Retinal pigment epithelial tear	p. 102
5.3.2. Polypoidal vasculopathy	p. 104
5.3.3. Chorioretinal anastomoses	p. 106
6. Other degenerative macular disorders	p. 109
6.1. Pseudovitelliform dystrophy	p. 110
6.2. Angioid streaks	p. 112

7. Hereditary retinal dystrophies	p. 115
7.1. Stargardt's maculopathy	p. 116
7.2. Retinitis pigmentosa	p. 118
7.3. Cone dystrophy	p. 122
7.4. Best's disease	p. 124
7.5. Central areolar choroidal sclerosis	p. 130
7.6. X-linked retinoschisis	p. 132
8. Myopia	p. 137
8.1. Choroidal thinning	p. 138
8.2. Dome-shaped macula	p. 140
8.3. Bruch's membrane rupture	p. 142
8.4. High myopia neovascularisation	p. 144
8.5. High myopia foveoschisis	p. 146
9. Central serous chorioretinopathy (CSCR) and other serous retinal detachments	p. 149
9.1. Typical CSCR	p. 150
9.2. Chronic CSCR and diffuse retinal pigment epitheliopathy	p. 156
9.3. Other causes of serous retinal detachment	
9.3.1. Hypertension	p. 160
9.3.2. Purtscher's retinopathy	p. 162
9.3.3. Colobomatous pit	p. 164
9.3.4. Iatrogenic causes	p. 166
9.3.5. Rhegmatogenous retinal detachment	p. 168
9.3.6. Postoperative causes	
9.3.6.1. Episcleral surgery outcomes	p. 170
9.3.6.2. Subretinal perfluorocarbon liquids	p. 172
10. Inflammatory diseases	p. 175
10.1. Multiple evanescent white dot syndrome (MEWDS)	p. 176
10.2. Acute multifocal placoid pigment epitheliopathy (AMPPE)	p. 178
10.3. Serpiginous choroiditis	p. 180
10.4. Harada's disease	p. 182
11. Chloroquine-induced maculopathy	p. 185
12. Tumours	p. 189
12.1. Choroidal naevus	p. 190
12.2. Choroidal melanoma	p. 192
12.3. Choroidal metastasis	p. 194
12.4. Choroidal osteoma	p. 196

1. Optical coherence tomography in healthy subjects

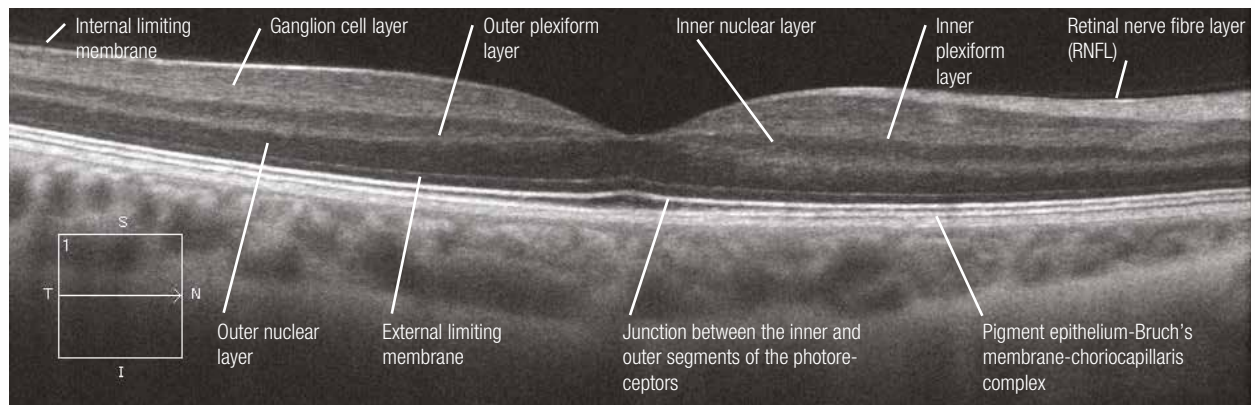
The OCT examination is based on the light-reflecting properties of the retinal tissue. The transverse sections obtained using the latest generation machines have an axial resolution of around 3 to 8 microns and a transverse resolution of 15 to 20 microns. The different retinal layers appear as a grey (or colour) scale that ranges from white to black (or red to blue). The more reflective the tissue is, the whiter the image will be (or redder if a colour scale is used). The less reflective the tissue is, the blacker (or bluer) the image will appear.

The first hyperreflective layer visible in the majority of cases (but not systematically) is the internal limiting membrane. The nerve fibre, inner and outer plexiform layers are also hyperreflective, while the inner nuclear and outer nuclear layers are hyporefective. The ganglion cell layer is moderately reflective. It should be noted that, under normal conditions, the Henle's fibre layer (part of the outer plexiform layer) is not visible.

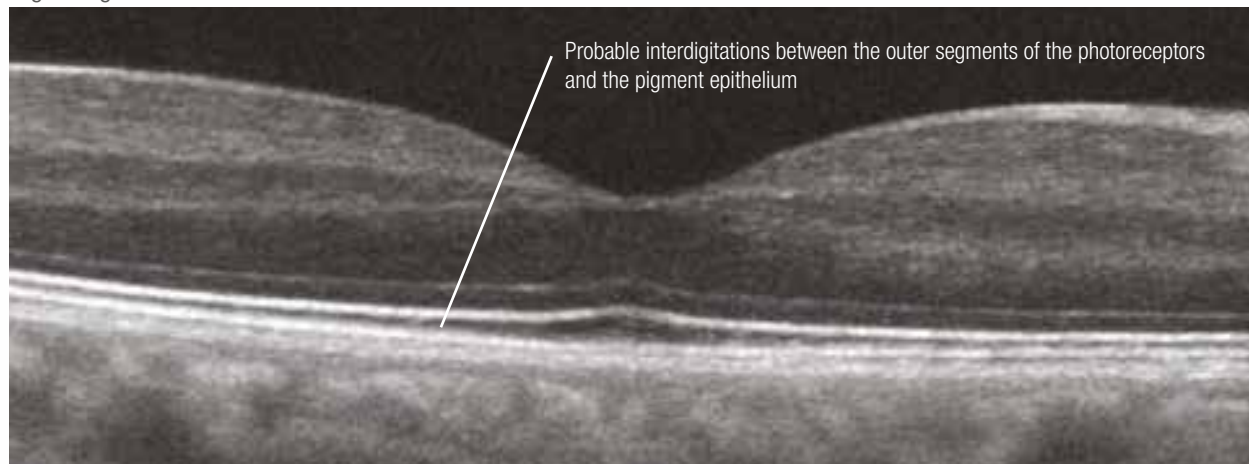
Regarding the outer retina, it is recognised that the most hyperreflective line corresponds to the junction between the inner and outer segments of the photoreceptors (also called the "photoreceptor integrity line"). The weakly reflective line located just above is the external limiting membrane. The outermost and thickest hyperreflective layer corresponds to the pigment epithelium-Bruch's membrane-choriocapillaris complex. In some cases, if the image quality is good, just below the junction between the inner and outer segments of the photoreceptors, it is possible to see interdigitations between the outer segments of the photoreceptors and the apical villi of the retinal pigment epithelium.

In enhanced depth imaging (EDI) mode, the most posterior layers are more visible and the Haller's layer (corresponding to large choroidal vessels) and the Sattler's layer (corresponding to medium-sized vessels) can be distinguished. The choroidoscleral boundary is also visible (blue arrows).

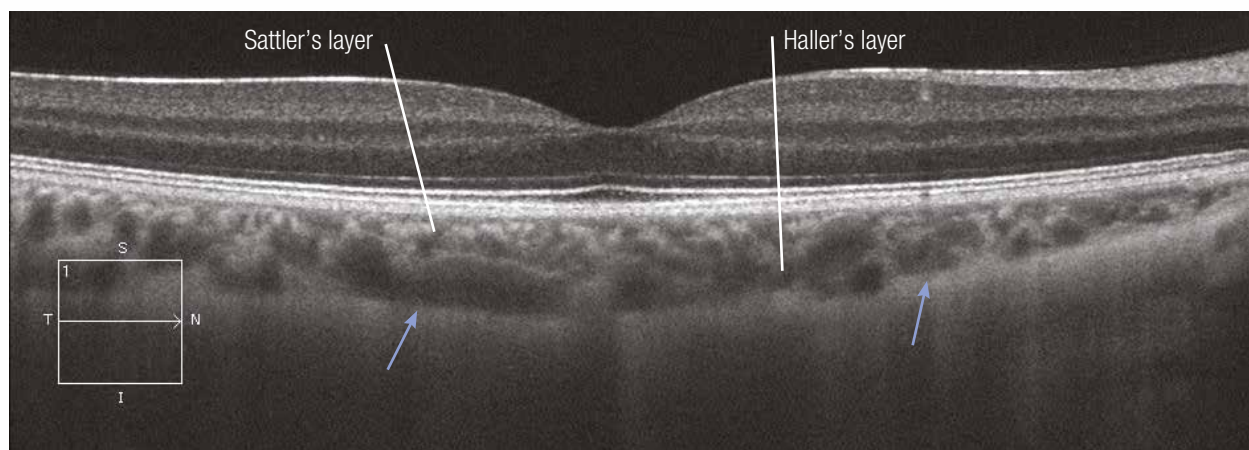
Normal OCT



High-magnification OCT



Normal OCT in EDI mode



2. Diseases of the vitreoretinal interface

- 2.1. Vitreomacular traction**
- 2.2. Macular hole**
- 2.3. Lamellar hole**
- 2.4. Epimacular membrane**

Vitreomacular traction syndrome

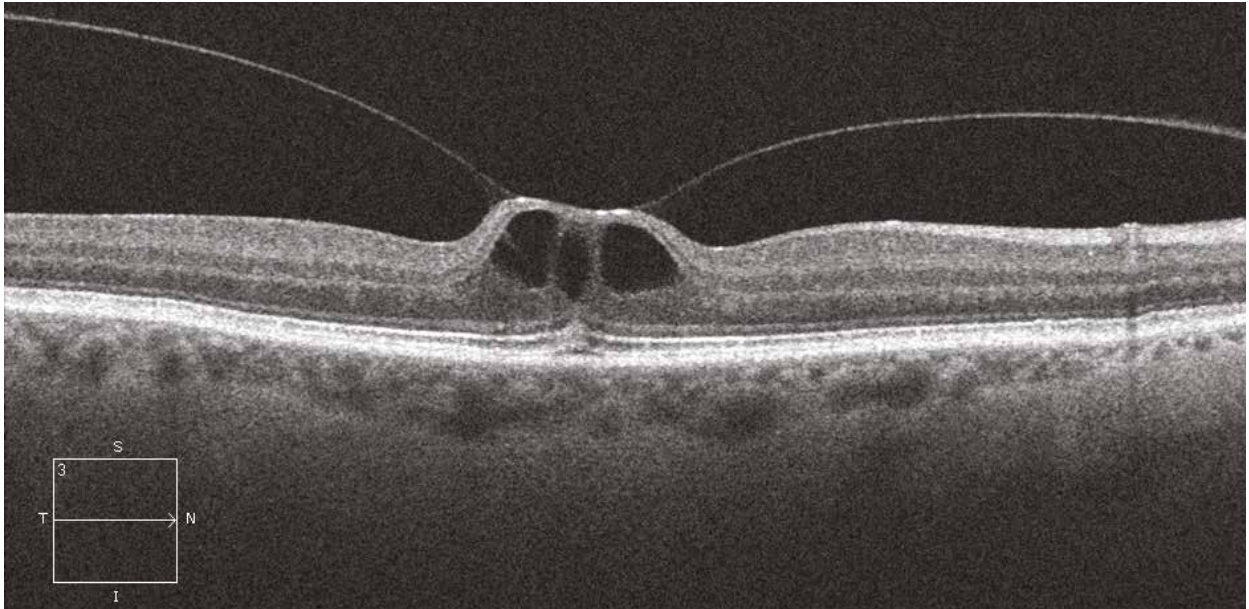
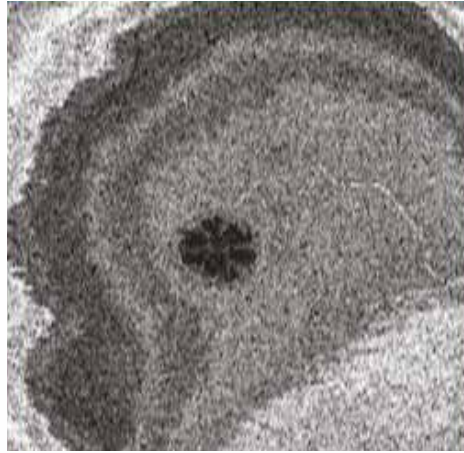
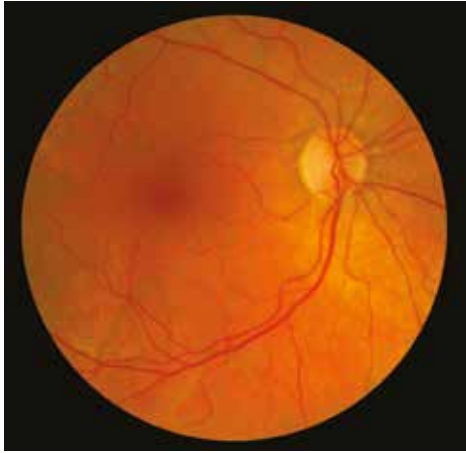Case 1

The colour image is often poorly contributive to explain the patient's metamorphopsia. On the OCT image, the posterior hyaloid remains attached to the macular region where it appears hyperreflective. The adjacent fovea is elevated and microcystic. The "en-face" OCT section reveals the petaloid appearance of the retinal cysts.

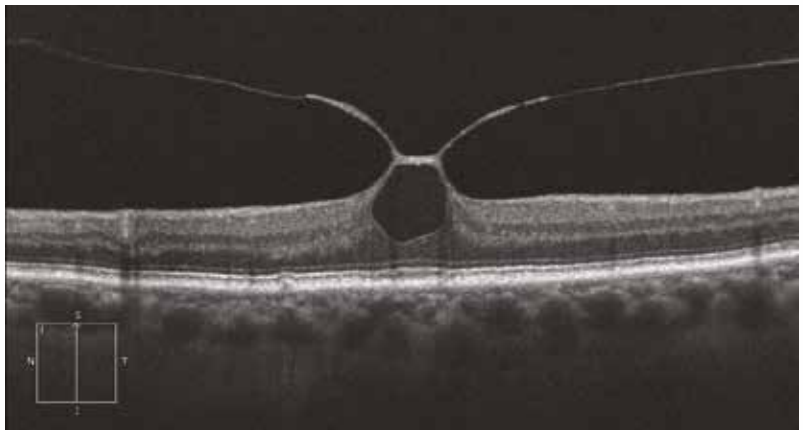
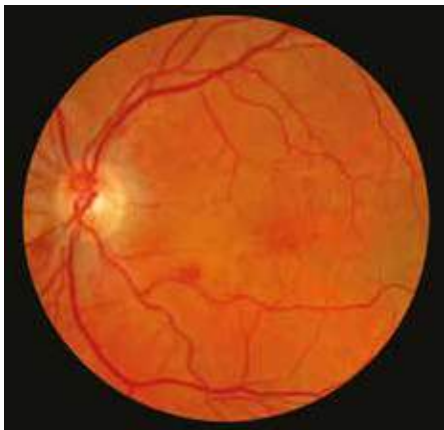Case 2

The posterior hyaloid adjacent to the macular region is greatly thickened and hyperreflective. The vitreomacular traction is even more pronounced with a marked elevation of the central vitreomacular adhesion zone. The outer retinal layer is intact.

Case 1



Case 2



Macular holes

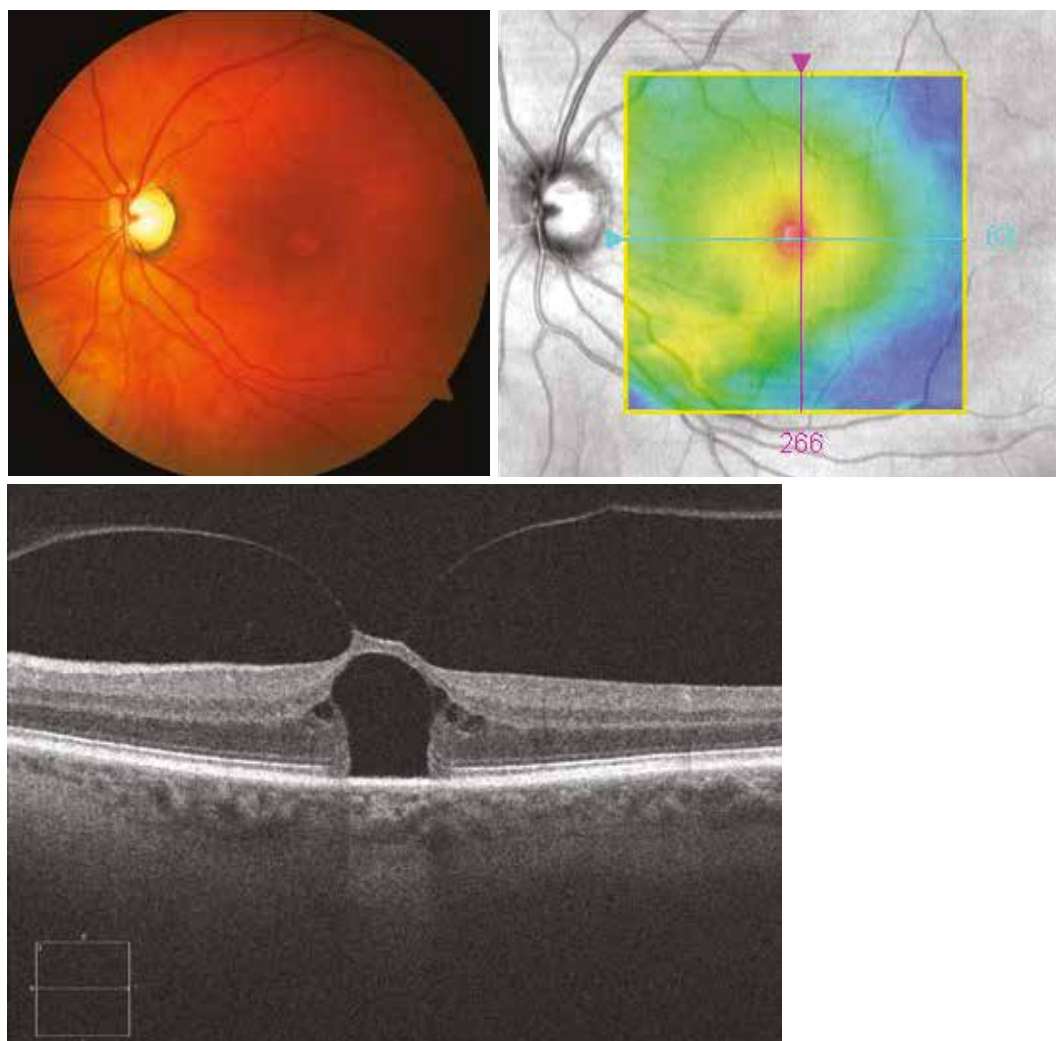
Case 1 - Stage 1B macular hole: impending macular hole

On the colour image, there is a central, rounded lesion, slightly discoloured in comparison to the perilesional zone rich in macular pigment. The retinal mapping reveals centrofoveal thickening, which corresponds to a marked vitreomacular traction on the OCT section. In contrast to the “simple” vitreomacular traction, the macular cyst adjacent to the traction is associated with an opening of the outer retinal layers, thus forming a stage 1B macular hole or an impending macular hole.

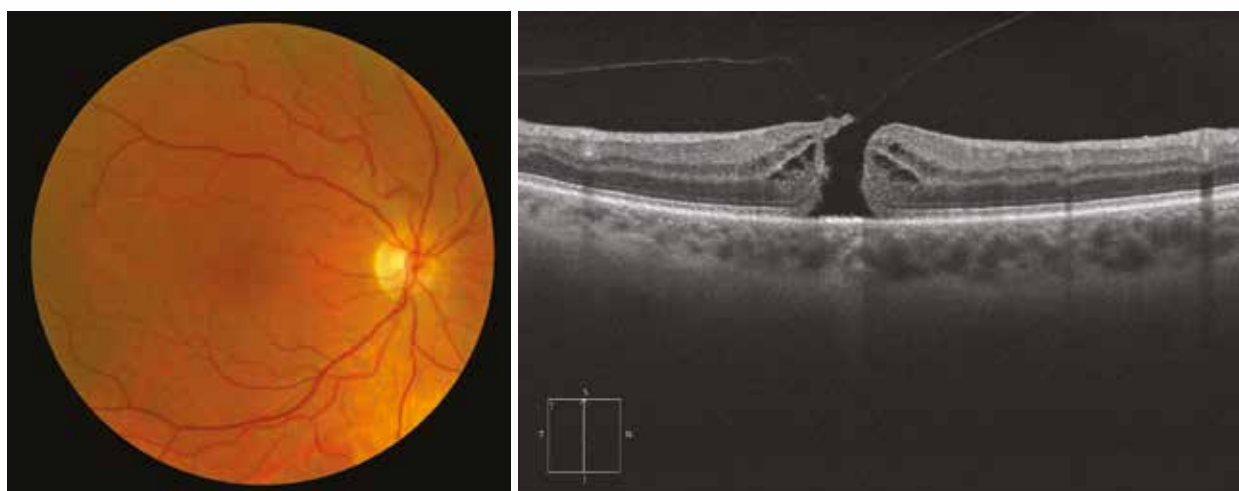
Case 2 - Stage 2 macular hole

In this case, the small-sized, rounded lesion on the colour image corresponds to a full-thickness macular hole. In fact, the OCT section reveals the break of the cyst roof, with adhesion of the posterior hyaloid still present at the edge of the hole. The edges of the macular hole are thickened with hyporeflective cysts.

Case 1



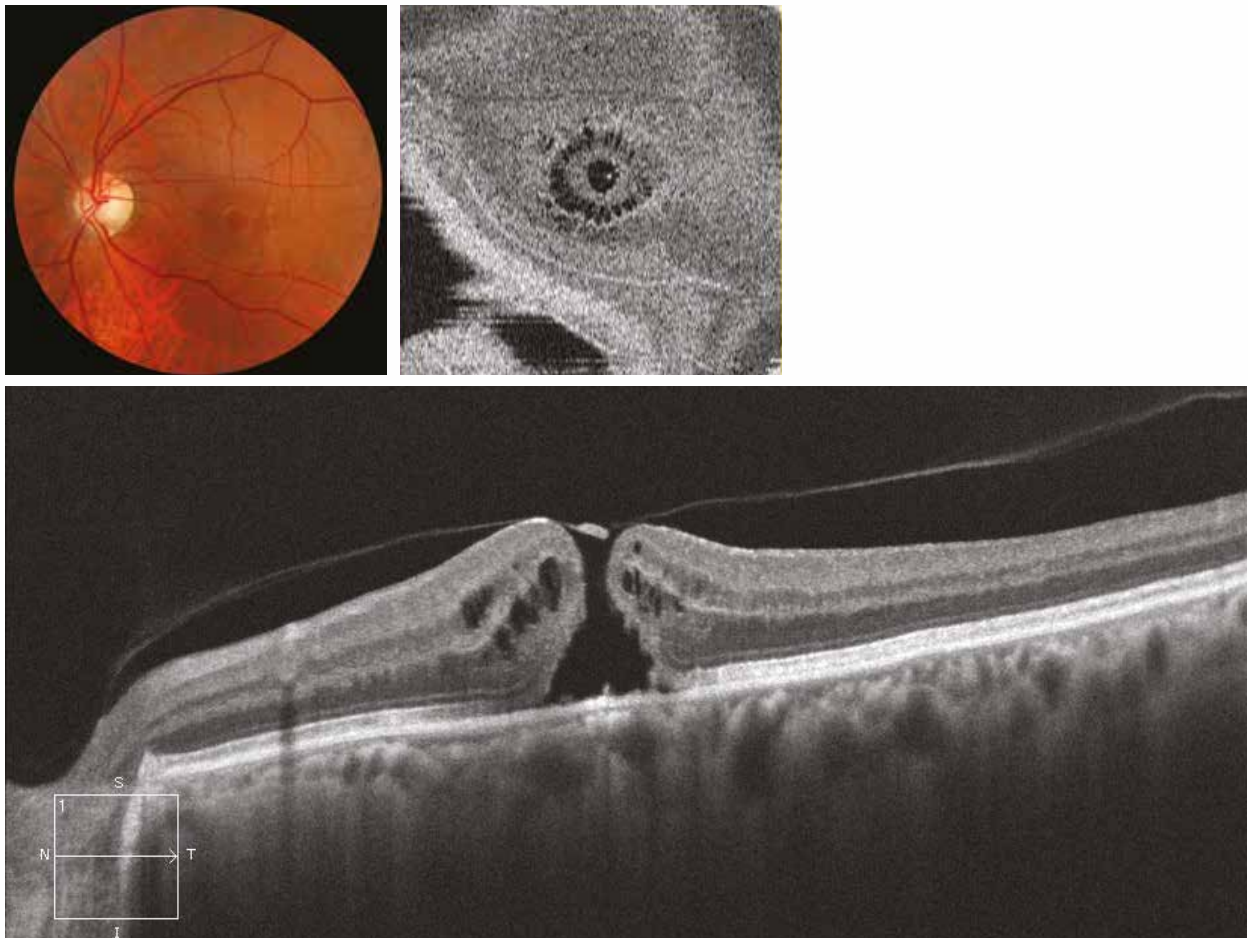
Case 2



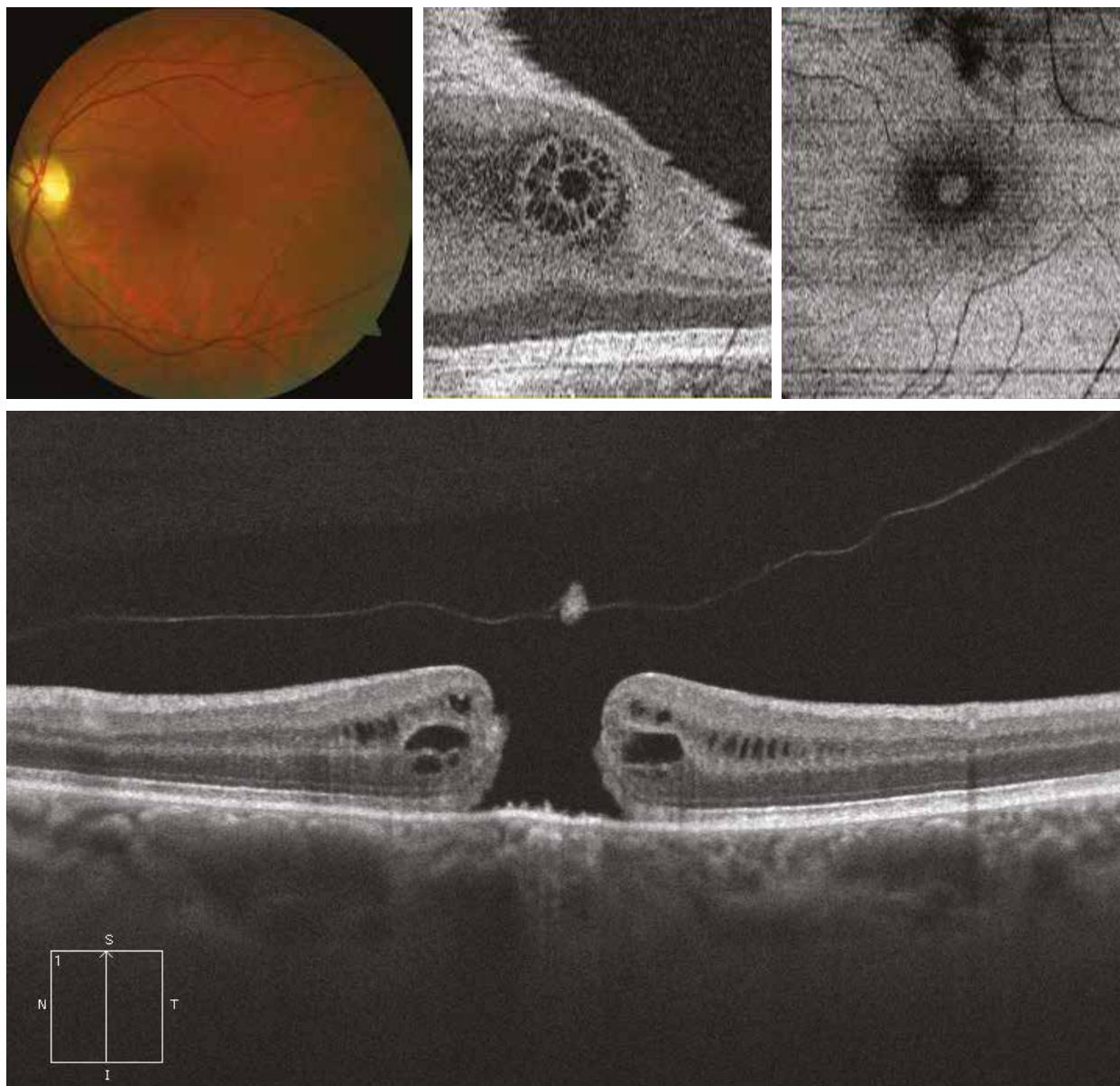
Cases 3 and 4 - Stage 3 macular hole

The posterior hyaloid is detached from the edges of the macular hole forming an operculum. The vitreous is not yet detached from the optic disc. These stage 3 macular holes may be small ($< 250 \mu\text{m}$) as in case 3 or larger ($500 \mu\text{m}$) as in case 4. Small, yellowish-white deposits may be visible in the centre of the macular hole (as shown on the colour image of case 4). These correspond to proliferations of the retinal pigment epithelium visible on the OCT section. Here, the edges are still thickened by cystic cavities, giving a petaloid appearance on the “en-face” OCT image. By changing the depth of focus of the “en-face” OCT of patient 4, the fundoscopic appearance of the macular hole is shown.

Case 3



Case 4



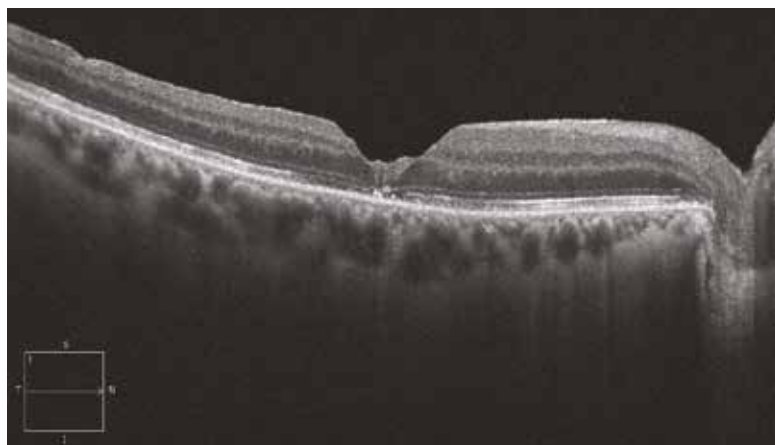
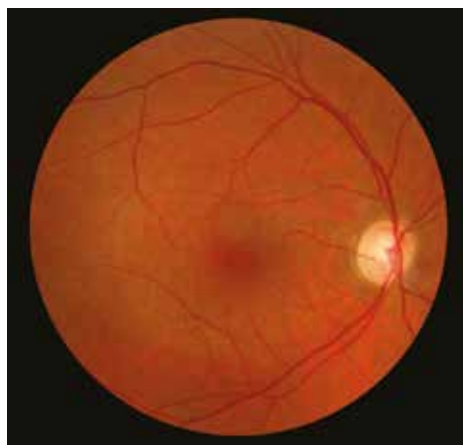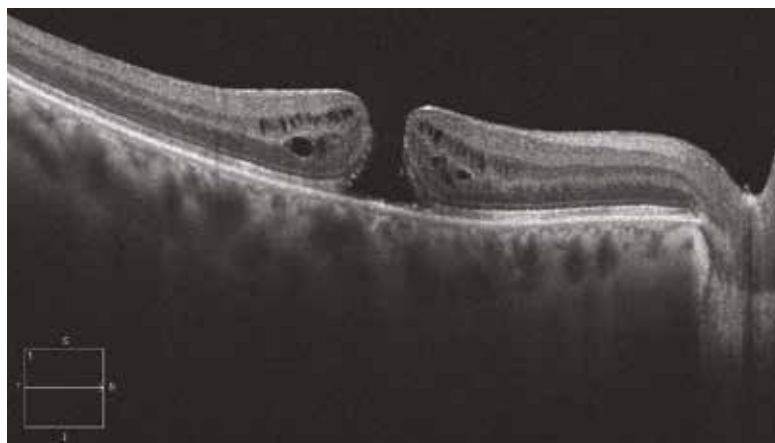
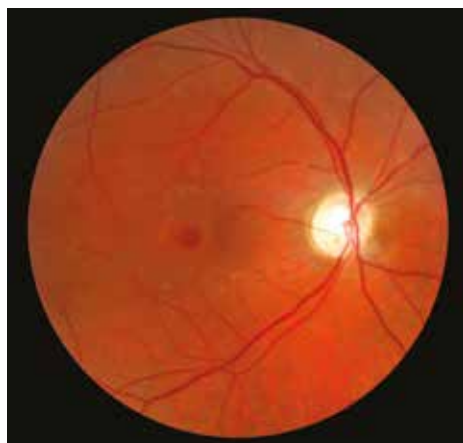
Case 5

When the posterior hyaloid is completely detached, it is a stage 4 macular hole. The edges of the hole are still thickened with multiple cystic cavities but the hyaloid is no longer visible. One month after surgery, the macular hole is closed with reorganisation of the centrofoveal tissue visible on the OCT section.

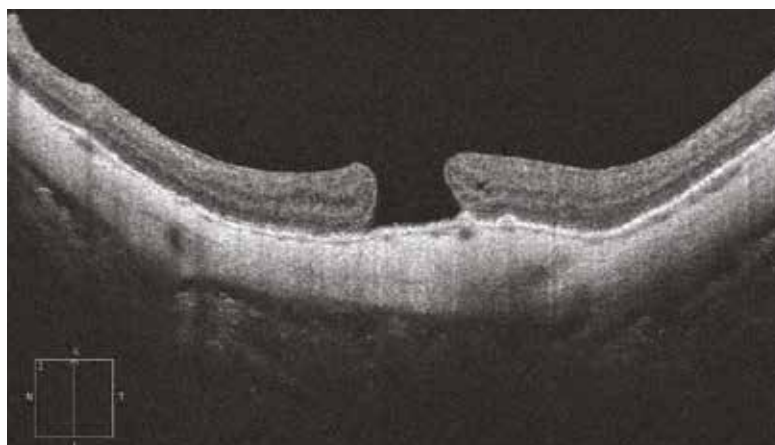
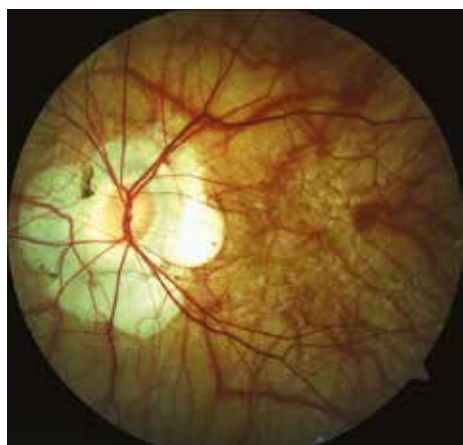Case 6

Old macular hole in a highly myopic patient, barely visible at ocular fundus examination due to the choroidosis. Here, the hole is very large and the edges are flattened. Surgery is no longer indicated.

Case 5

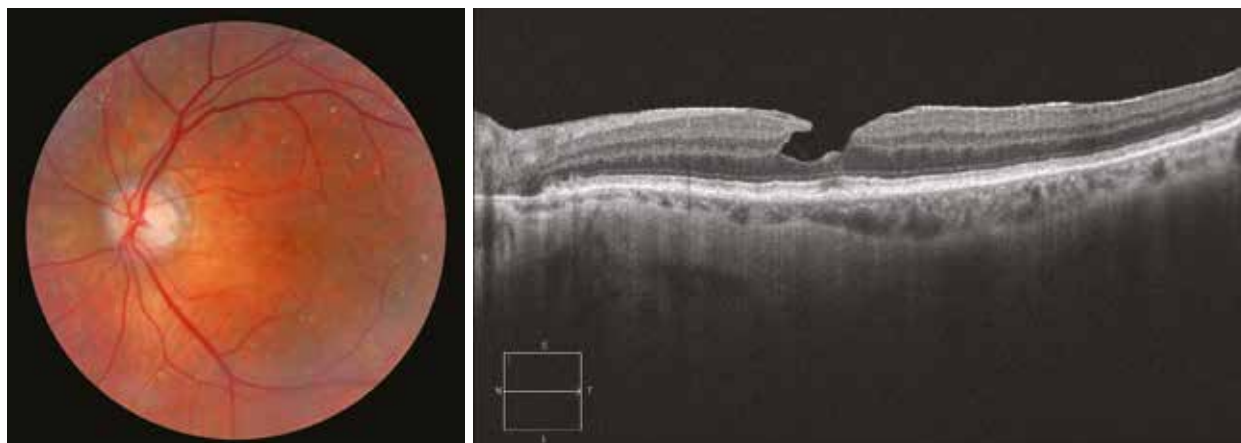

Case 6



Lamellar hole

The colour image reveals a macular pseudohole. On the OCT section, there is a defect in the fovea, which appears thin in some areas, and a characteristic sharp cleavage between the outer retina and the inner retina on the edge of the fovea.



Epimacular membranes

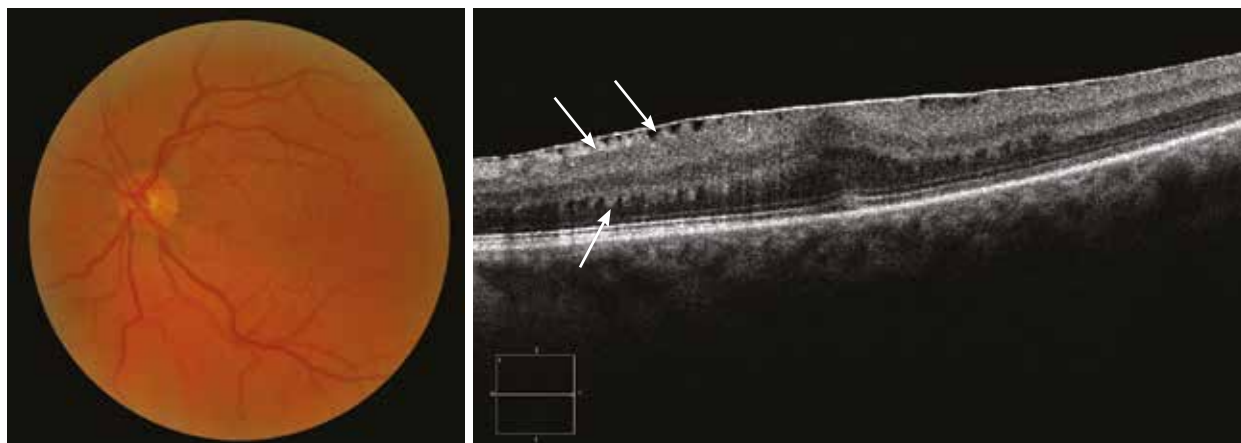
Case 1

On the colour image, there is a fold in the macular area with a cellophane-like reflection suggestive of an epimacular membrane. On the OCT section, a hyperreflective stretched line can be seen at the surface of the retina, causing tangential contractions responsible for the loss of the foveal pit and wrinkling of the retina (arrows).

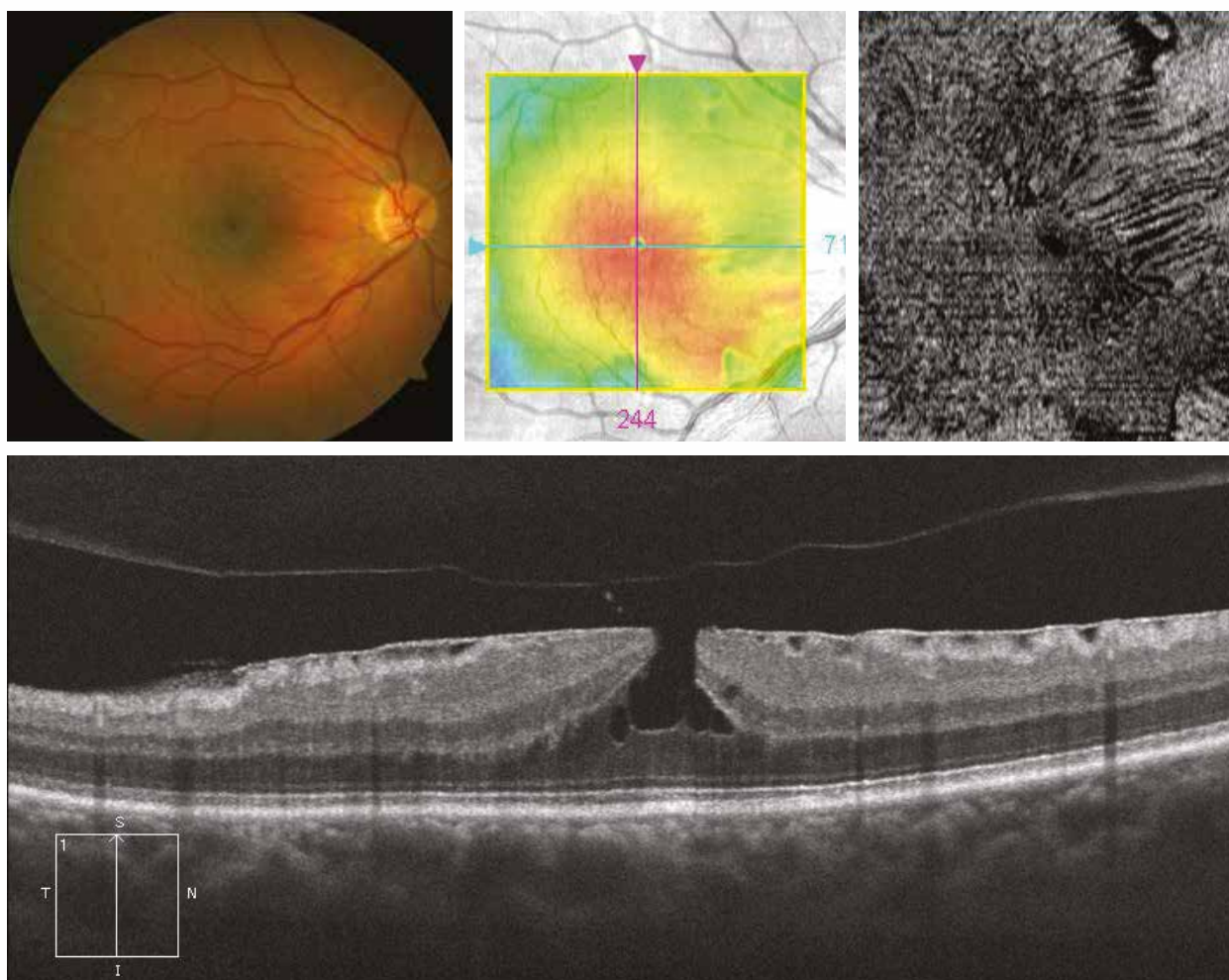
Case 2

In this case, the fundus examination reveals a cellophane-like reflection associated with an aspect of macular pseudohole. The retinal mapping confirms the retinal thickening centred on the fovea. On the OCT section, there is a hyperreflective line on the macular surface with superficial retinal folds. The edges of the foveal pit are verticalised, explaining the macular pseudohole aspect at fundus examination. The posterior hyaloid is detached. On the “en-face” OCT, the macular wrinkling is clearly visible.

Case 1



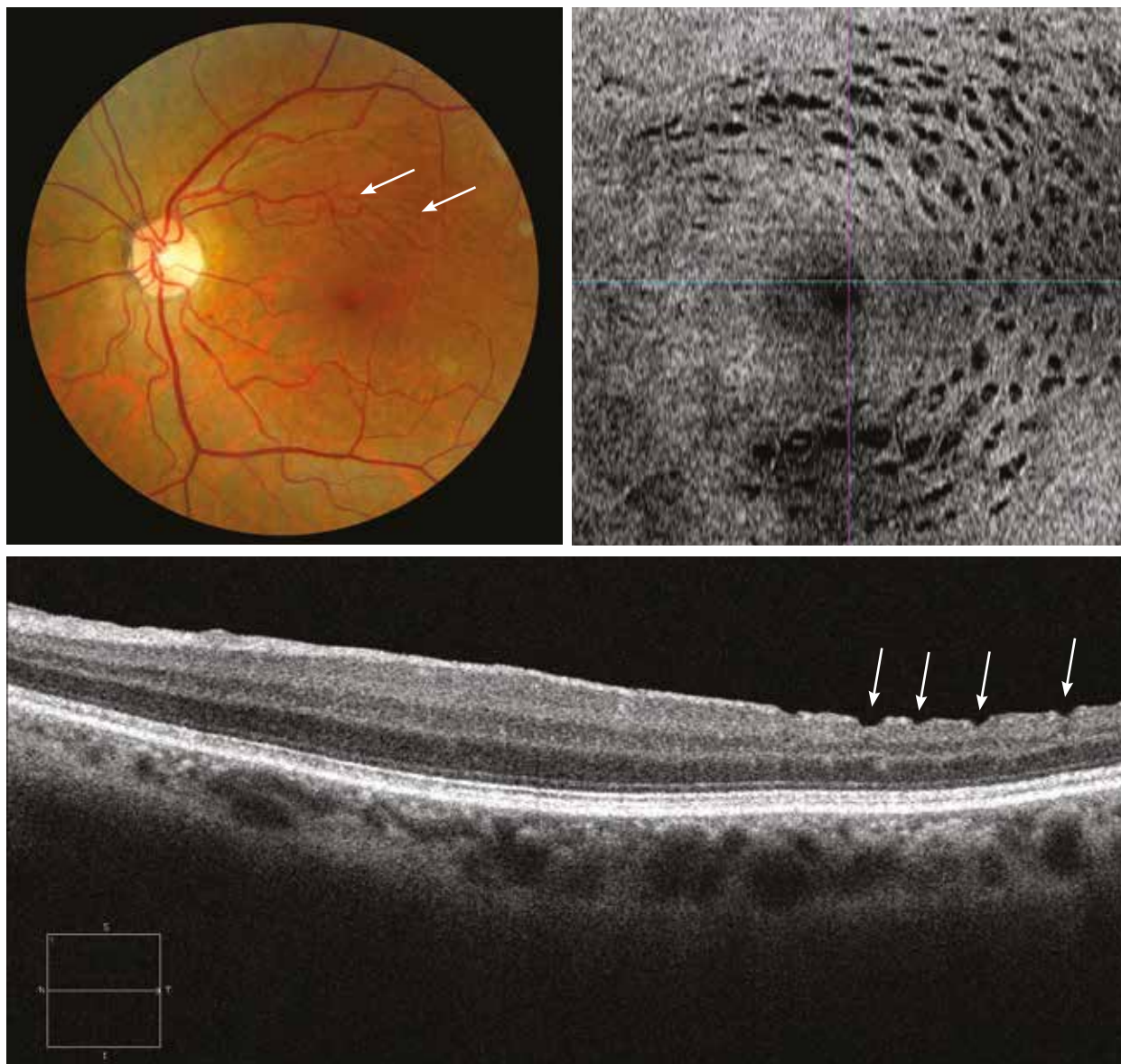
Case 2



Case 3 - Postoperative appearance of dissociated optic nerve fibre layer (DONFL)

On the colour image, in the superior temporal region, there is an alveolate appearance of optic nerve fibres (arrows), resulting from the extensive peeling of the internal limiting membrane. On the OCT section, centred on the superior temporal region, this alveolate pattern corresponds to gaps at the surface of the optic nerve fibre layer (arrows). These gaps are very clearly visible in the “en-face” OCT.

Case 3



3. Macular oedemas

3.1. Diabetes

- 3.1.1. Focal macular oedema
- 3.1.2. Mixed macular oedema
- 3.1.3. Diffuse macular oedema
- 3.1.4. Tractional macular oedema
- 3.1.5. Mixed maculopathy (oedematous and ischaemic)

3.2. Venous occlusion

- 3.2.1. Central vein occlusion
- 3.2.2. Branch vein occlusion

3.3. Arterial occlusion

- 3.3.1. Central artery occlusion
- 3.3.2. Branch artery occlusion

3.4. Inflammation

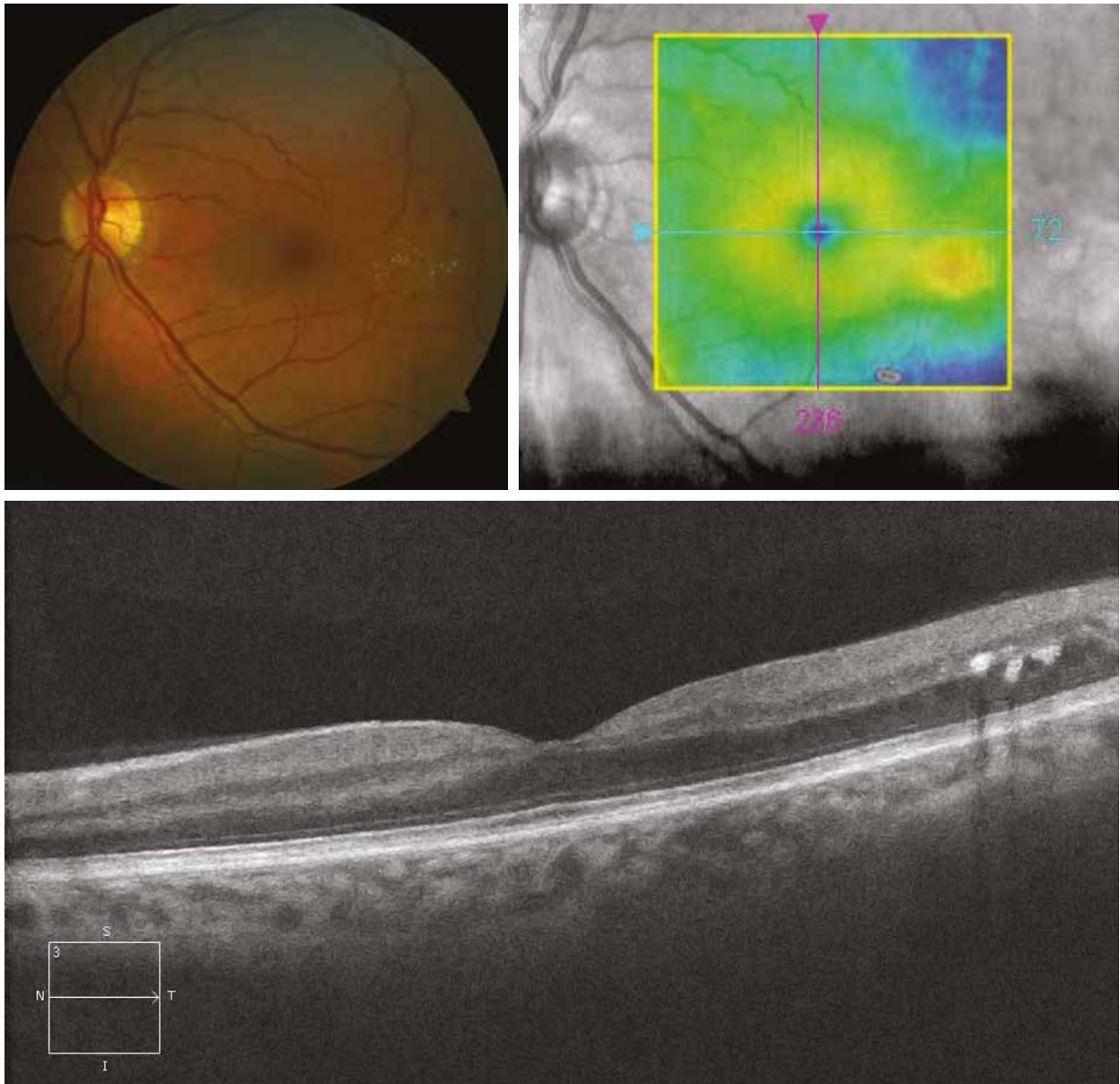
- 3.4.1. Uveitis
- 3.4.2. Irvine-Gass syndrome

Focal macular oedema

Case 1

On the colour image, microaneurisms and/or microhaemorrhages are observed in the temporomacular region associated with exudates disposed as a circinate ring very far away from the fixation point and, therefore, “not clinically significant”. The retinal thickening remains very far away from the fixation point and is visible on the retinal mapping. The OCT shows exudates as hyperreflective rounded intraretinal lesions.

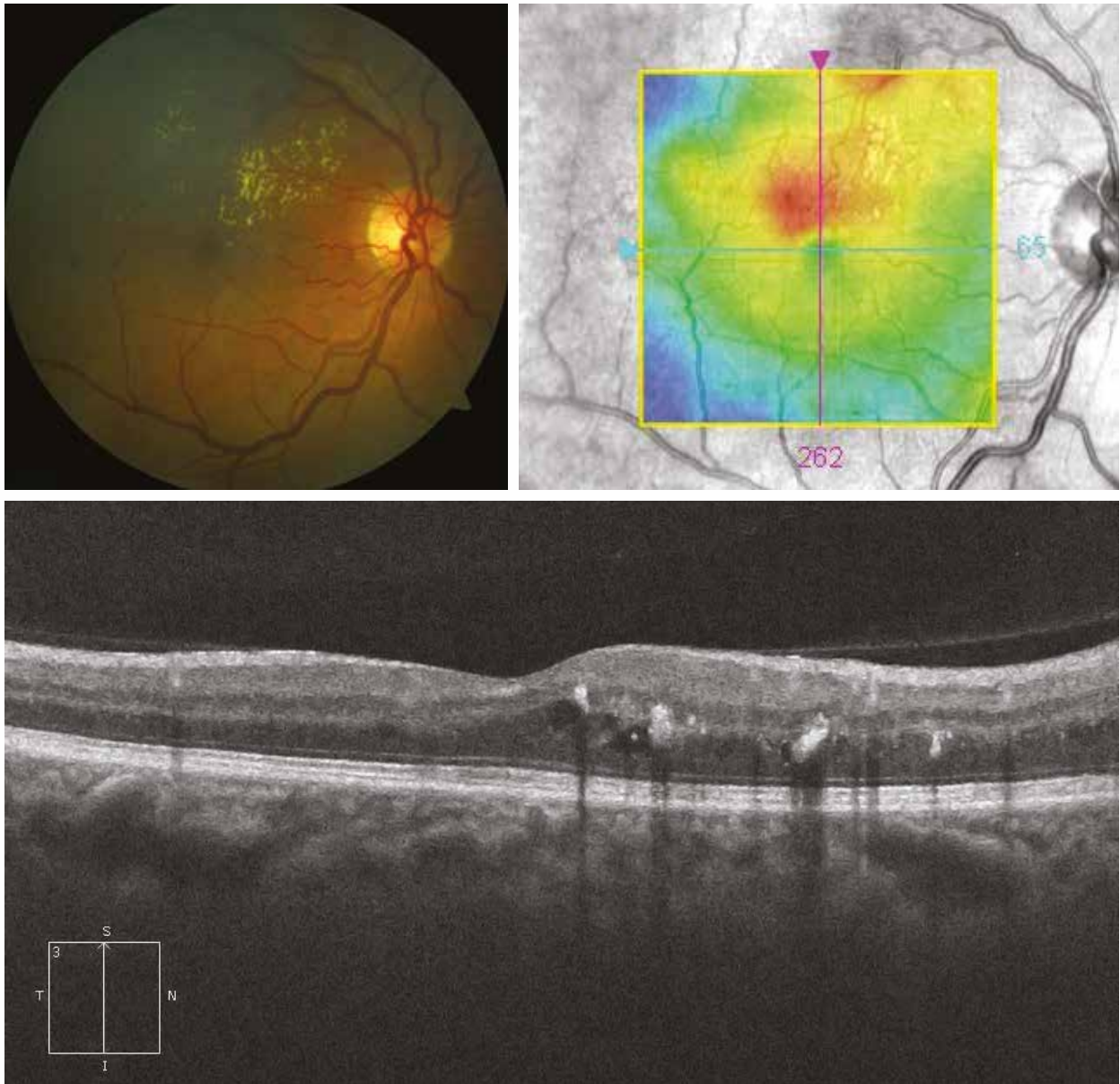
Case 1



Case 2

In this case, the exudates are more numerous under the superotemporal arcade and threaten the fixation point. The retinal mapping shows a moderately thickened retina in the central region (350 μm). On the OCT, early alteration of the foveal pit is visible with the presence of hyperreflective exudates and intraretinal cysts.

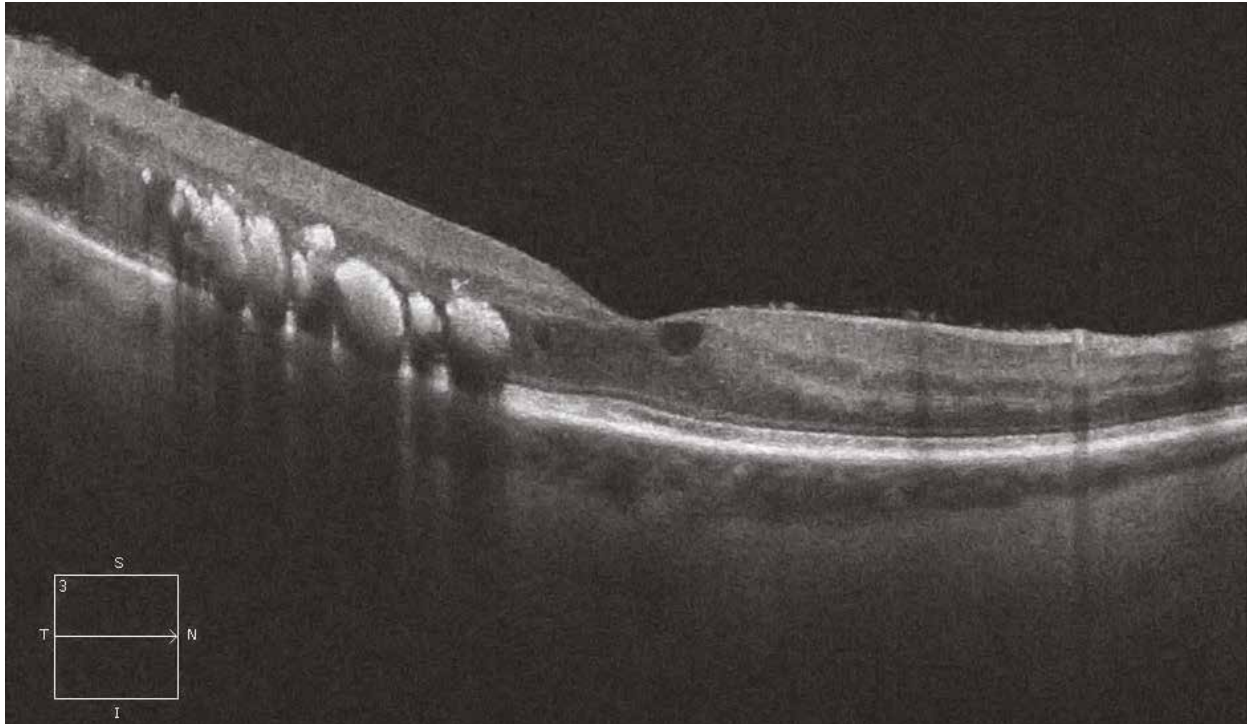
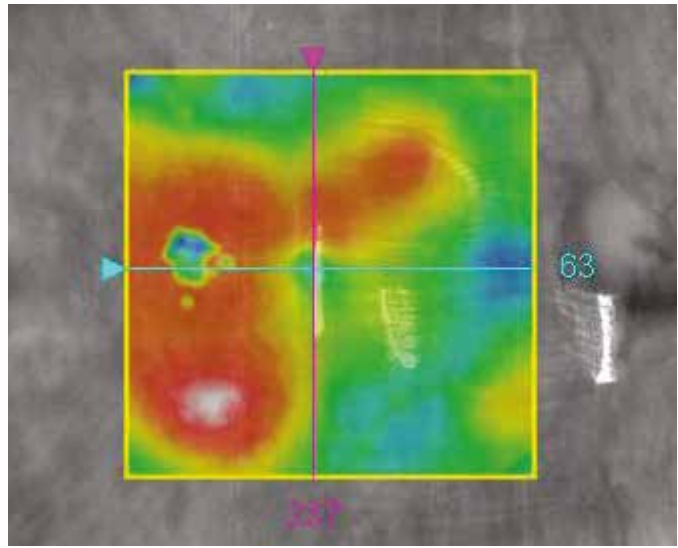
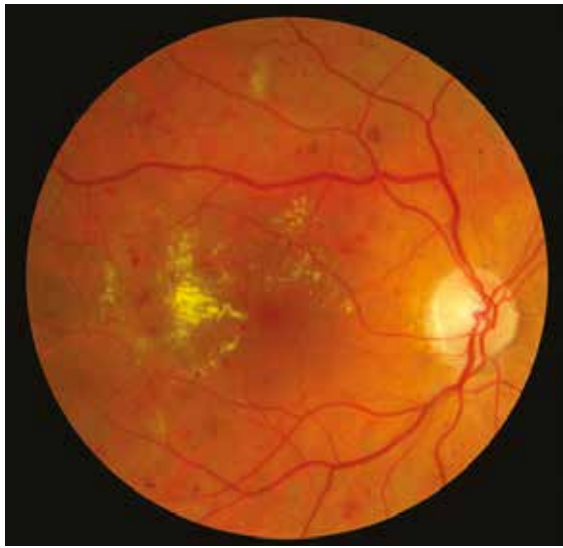Case 2



Case 3

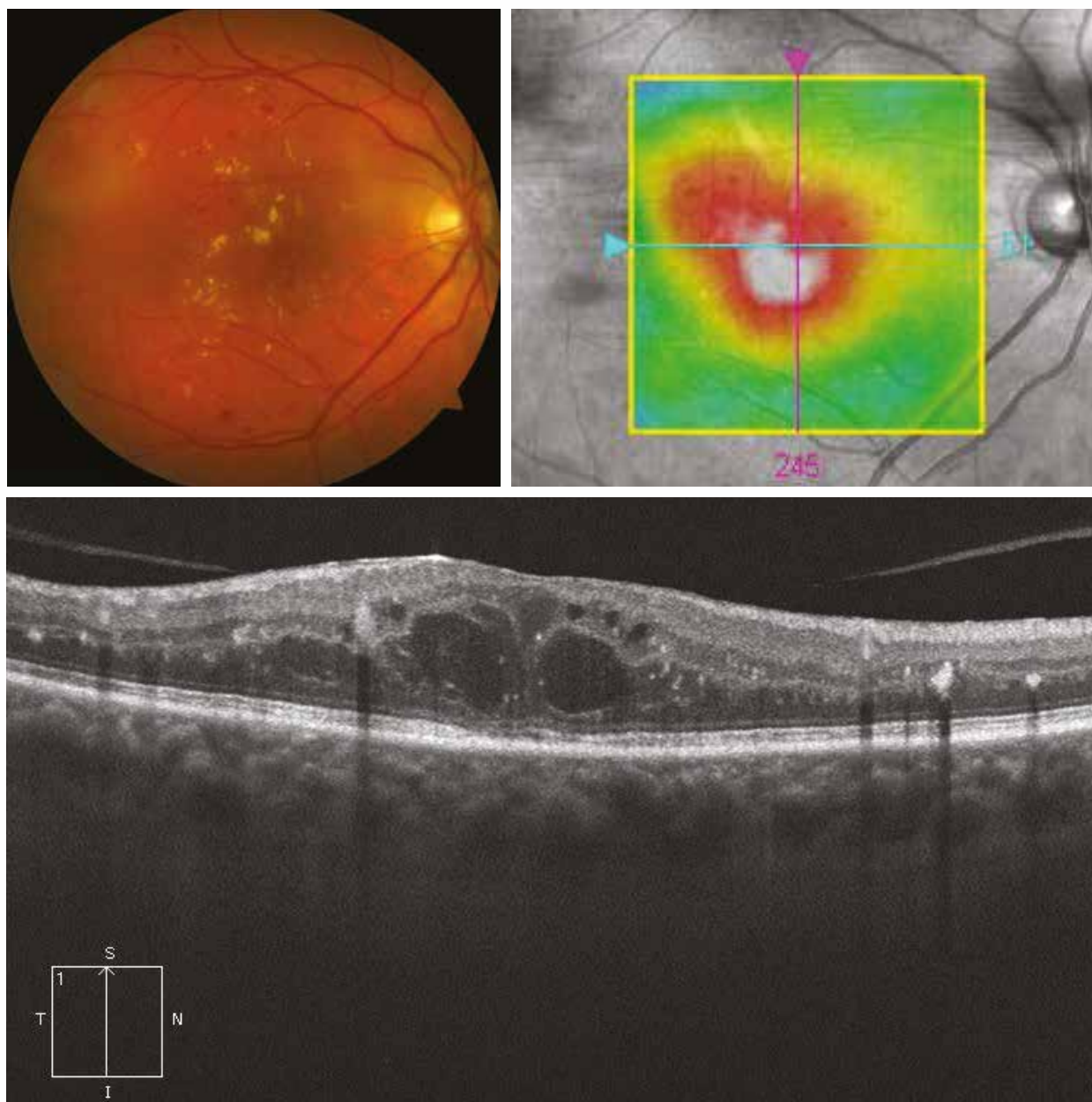
At an even more advanced stage, the vascular abnormalities and exudates are even more numerous and more dense in the macular region. The retinal mapping reveals major thickening, with hyperreflective plaques of exudates on the OCT section causing retinal masking to the rear.

Case 3



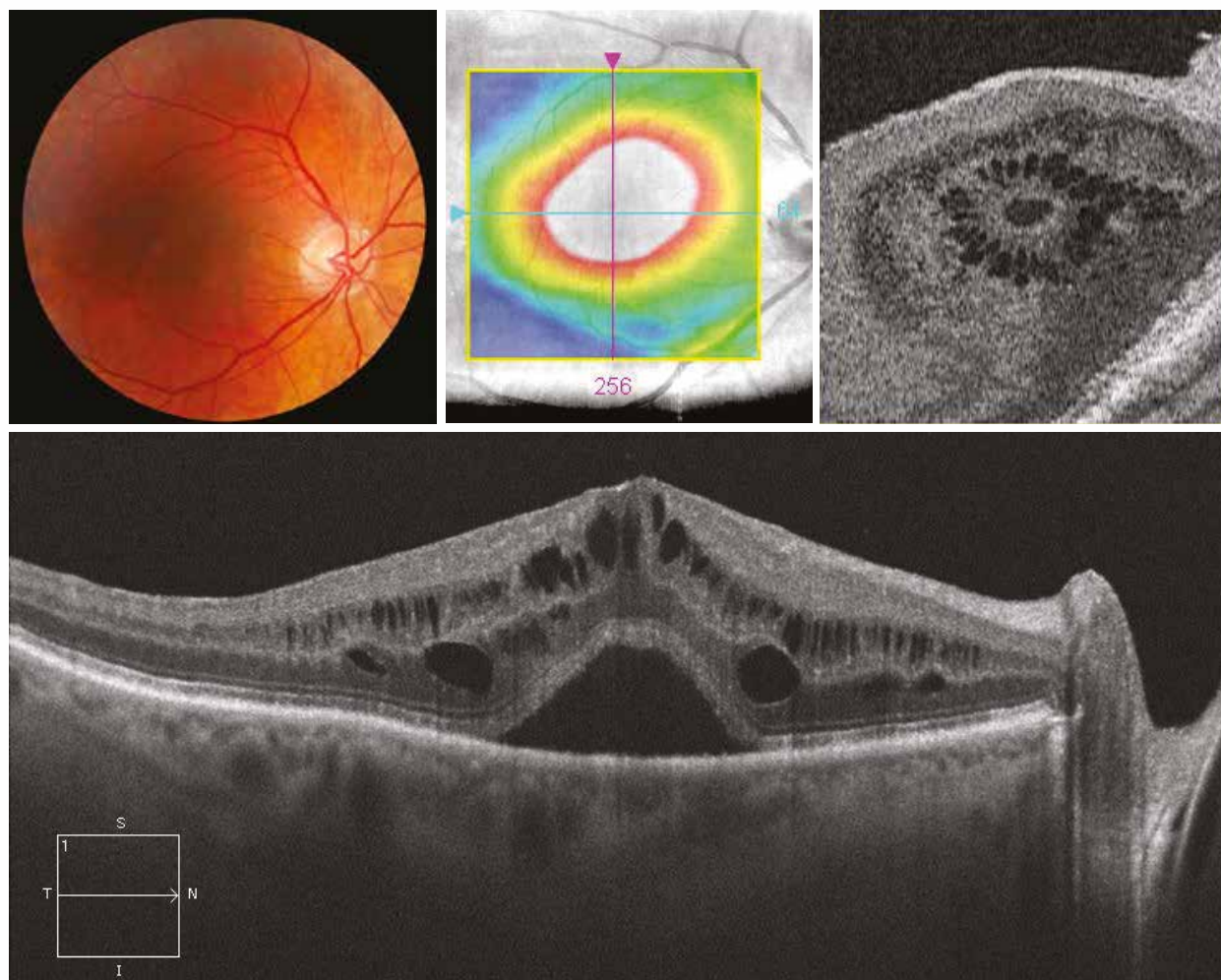
Mixed macular oedema

The colour image shows microaneurysms, microhaemorrhages and multifocal exudates. The extensive retinal thickening is visible on the retinal mapping. The OCT section reveals a macular thickening with loss of the foveal pit, intraretinal hyporeflective cystic cavities and hyperreflective exudates.



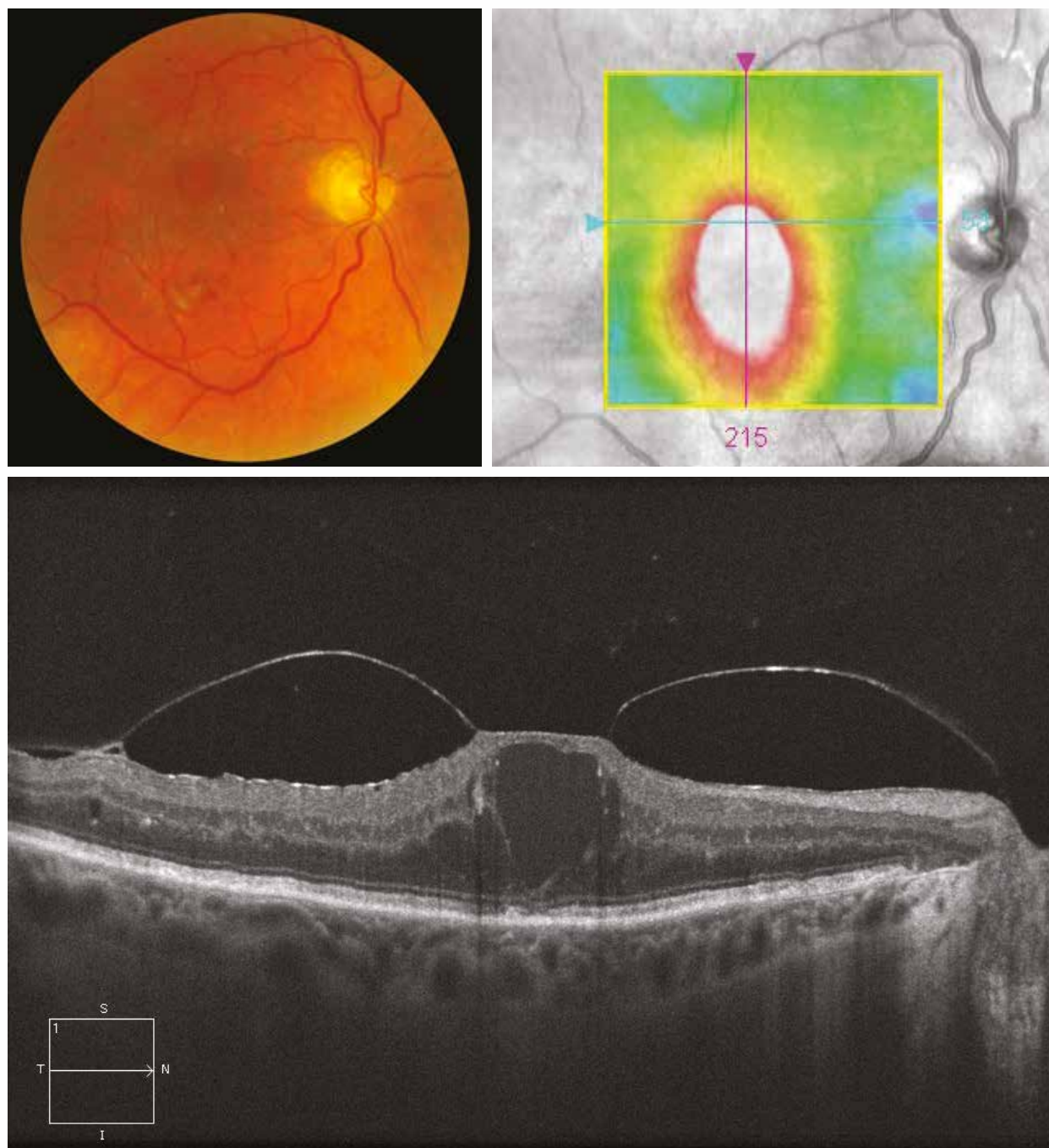
Diffuse macular oedema

Here, the colour image is not very contributive. There is no exudate. The macular thickening is revealed on the retinal mapping (700 μm). The OCT section shows multiple intraretinal cystic cavities within the outer and inner nuclear layers as well as a retrofoveal detachment. The “en face” OCT achieves the typical petaloid appearance of cystoid macular oedema.



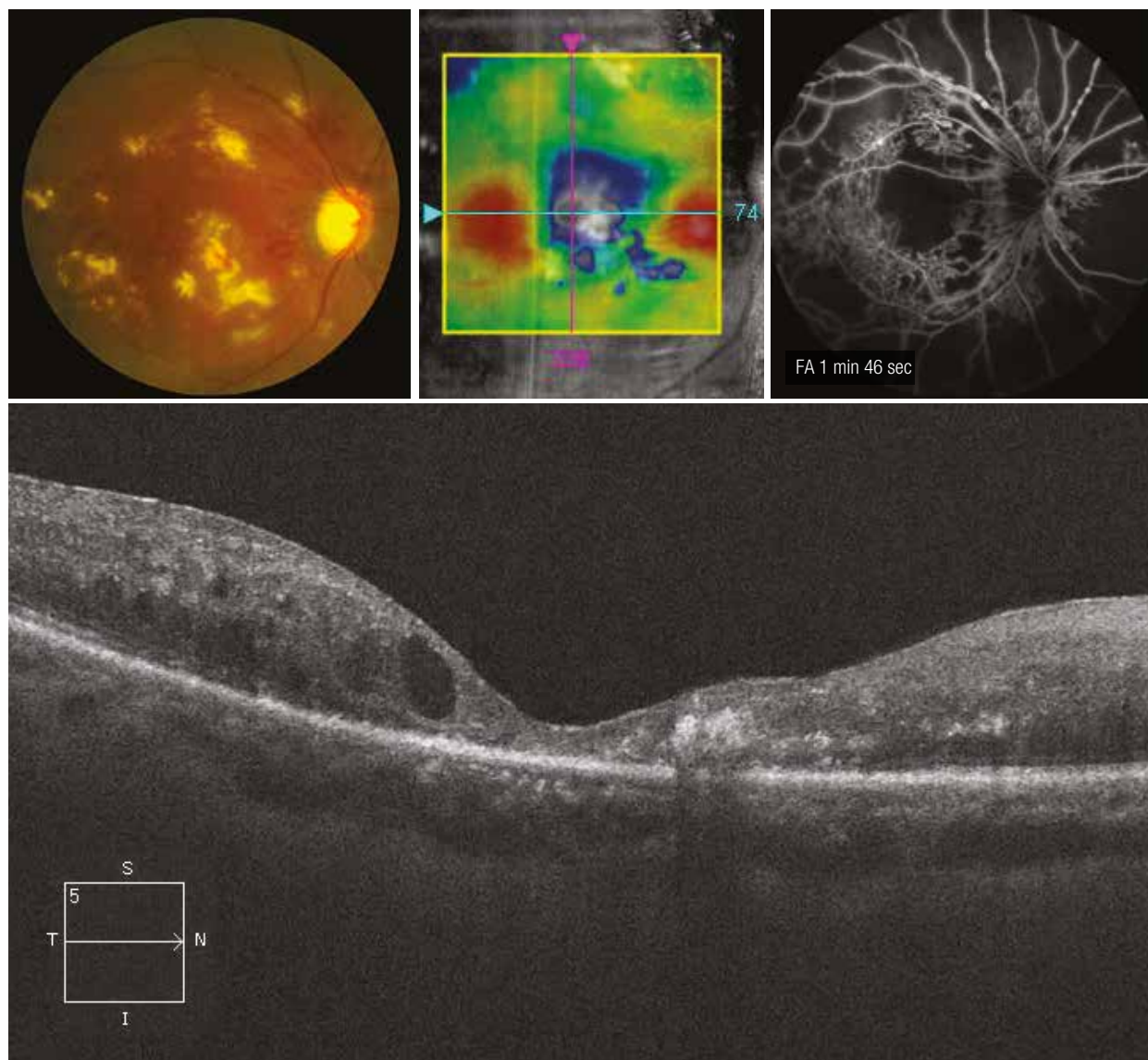
Tractional macular oedema

On the colour image, microaneurysms and/or microhaemorrhages are visible as well as few exudates in the macular region. The centromacular thickening is clearly visible on the retinal mapping. The OCT shows the partial detachment of the posterior hyaloid, greatly thickened and hyperreflective, with a persistent zone of centrofoveal and temporal vitreoretinal adhesion and an epimacular membrane. The retinal tissue adjacent to the traction is disorganised with a large foveal cystic cavity surrounded by smaller cysts.



Oedematous and ischaemic maculopathy

The colour image reveals numerous exudates, haemorrhages and retinal arterial attenuation. The retinal mapping shows areas of perifoveal thickening contrasting with a central thinning. The OCT section confirms the central thinning and the retinal disorganisation. The outer foveal layers are atrophied and the coexistence of hyperreflective cysts and exudates is noted. Macular ischaemia is demonstrated by angiography.



Central retinal vein occlusion (CRVO)

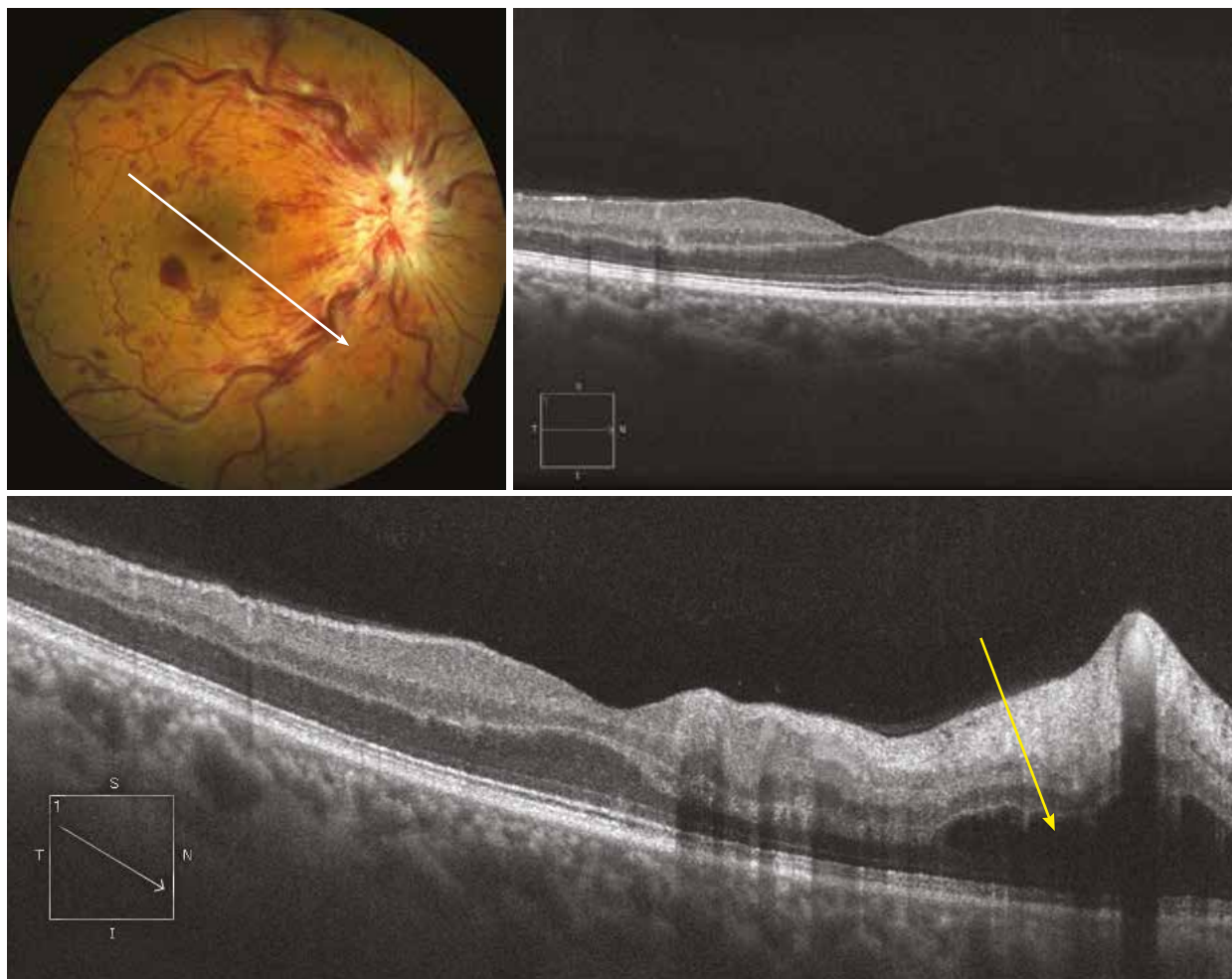
Case 1

Typical CRVO appearance on the colour image with papillary oedema, perivenular dilations and diffuse retinal haemorrhages. Venous whitening is also observed. The horizontal OCT section does not show any associated macular oedema, while the oblique section reveals a voluminous perivenular ischaemic retinal oedema (yellow arrow), corresponding to the perivenular whitening.

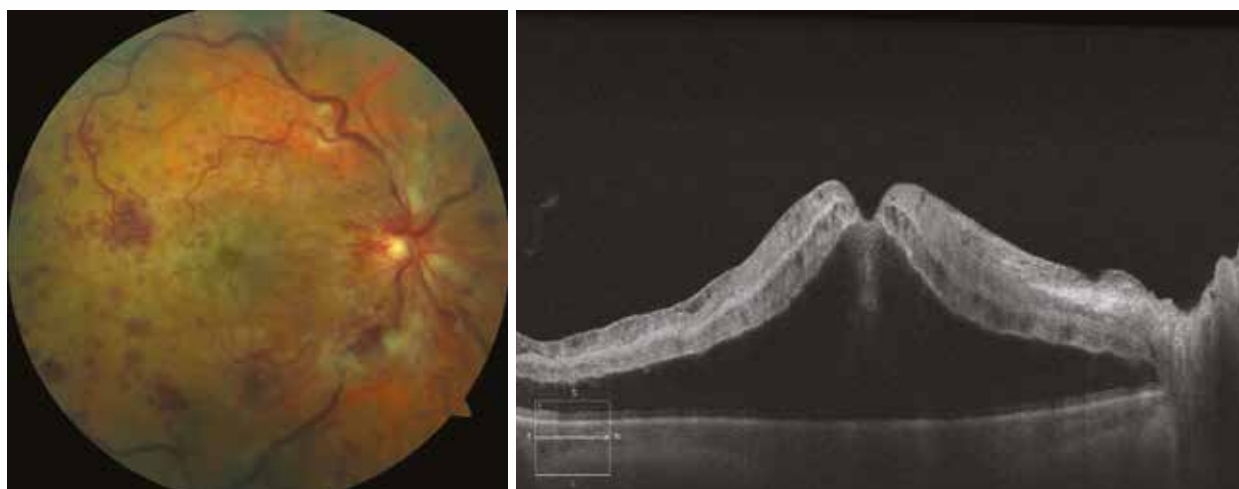Case 2

In this other typical case of CRVO, the macular oedema is severe, involving a large serous retinal detachment (SRD) with intraretinal cysts.

Case 1

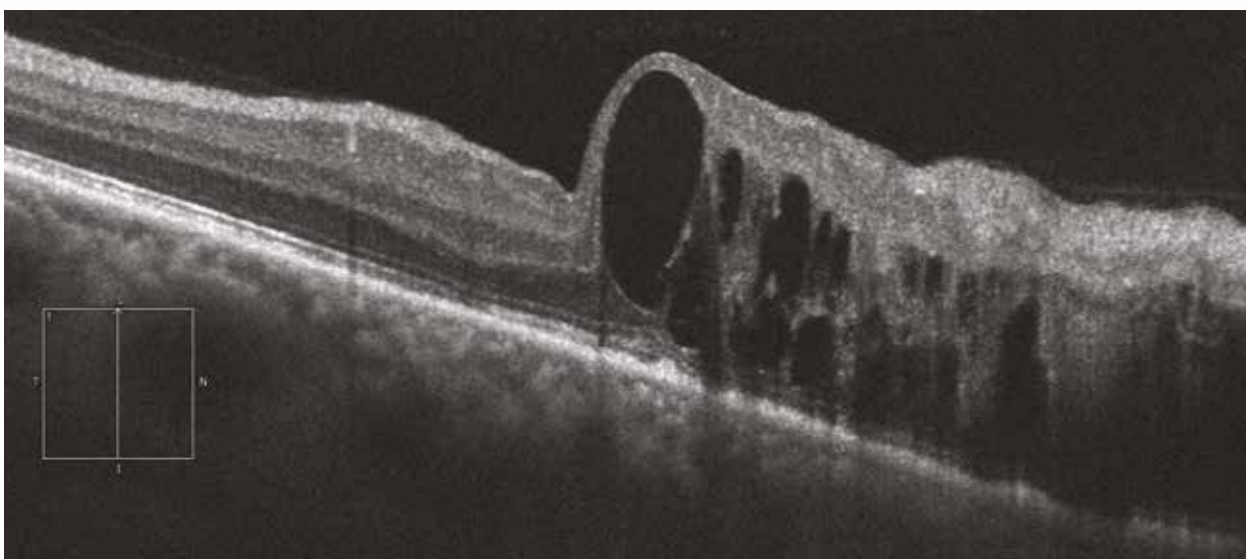
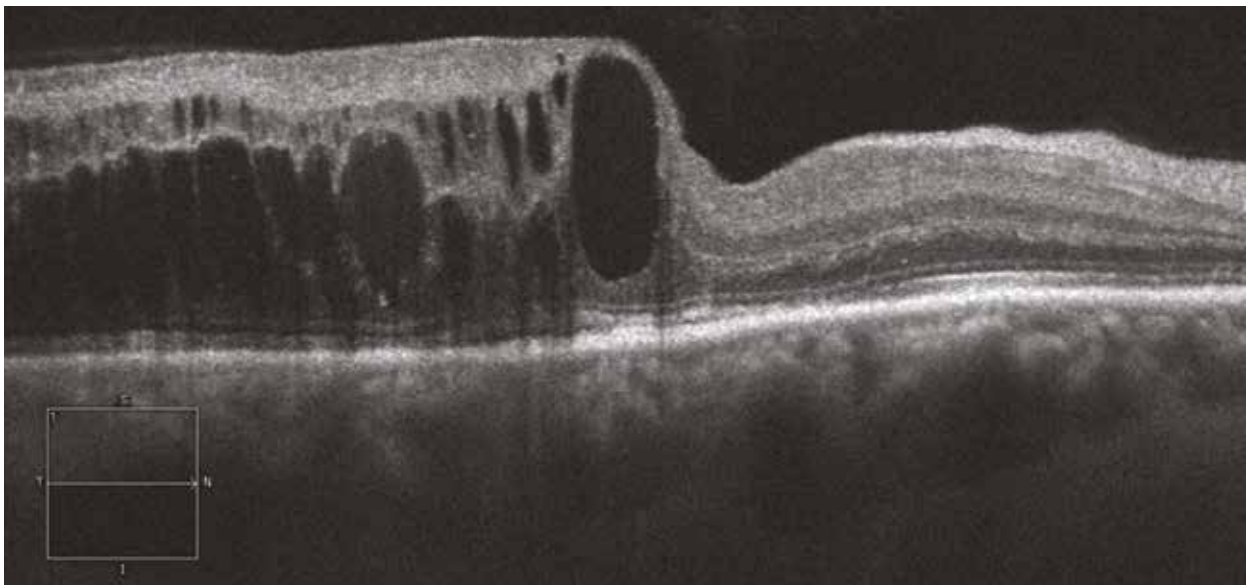
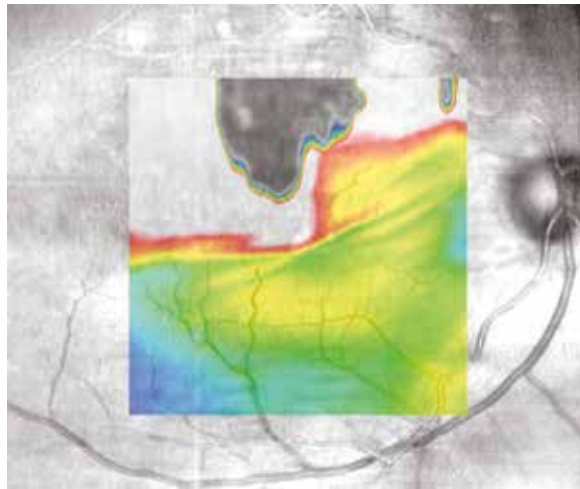
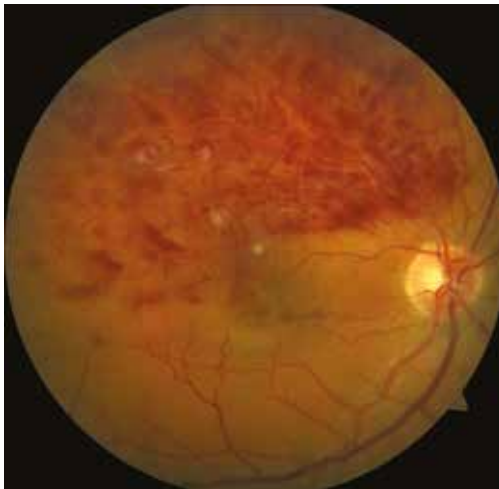

Case 2



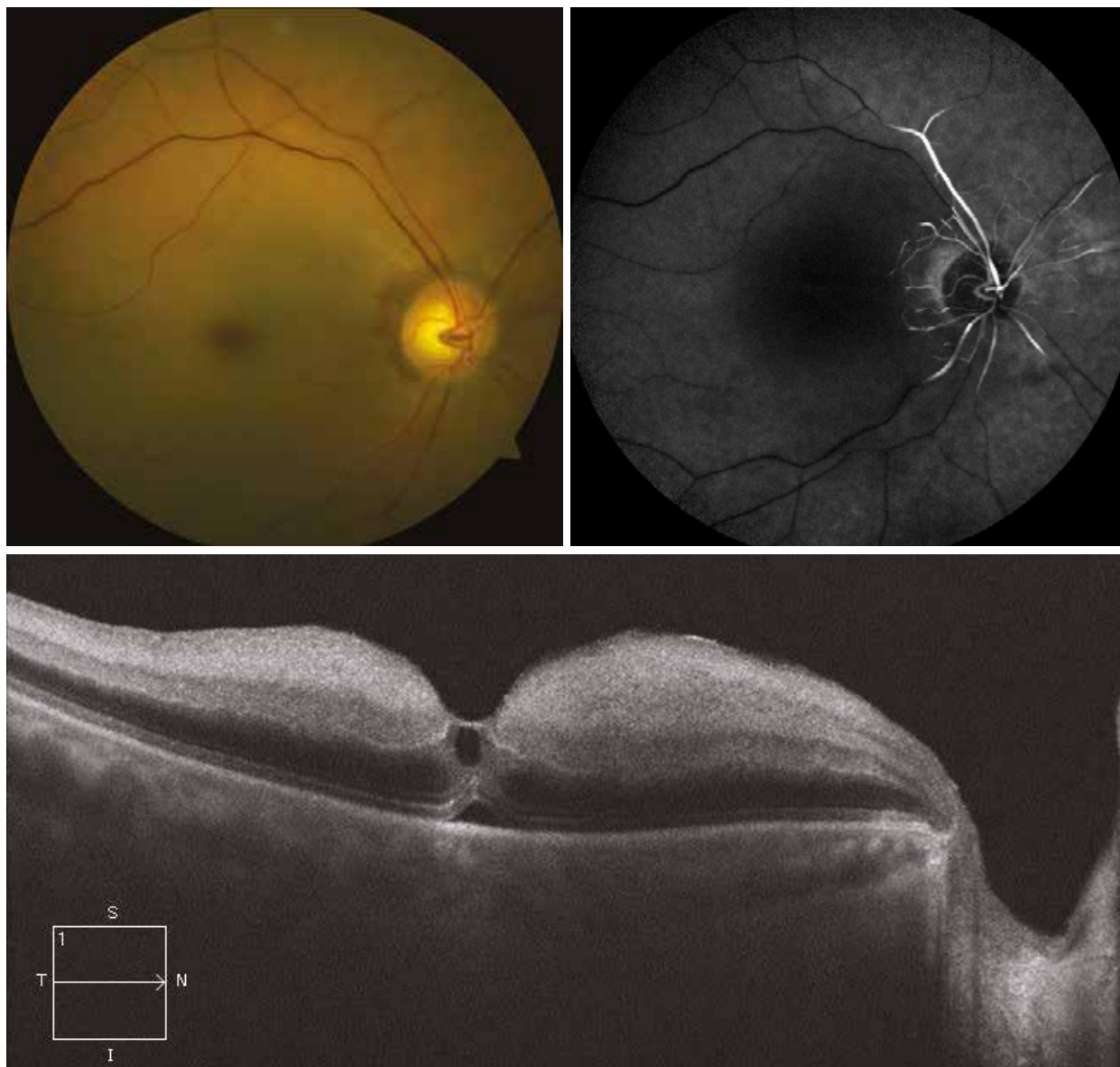
Branch retinal vein occlusion

Aspect of superotemporal branch vein occlusion with a large number of retinal haemorrhages and few cotton wool spots. The horizontal and vertical OCT sections show a voluminous intraretinal oedema in contact with the macula and the superior hemiretina. The interpapillomacular region is not damaged. The retinal mapping reveals a systematic thickening in the occluded area.



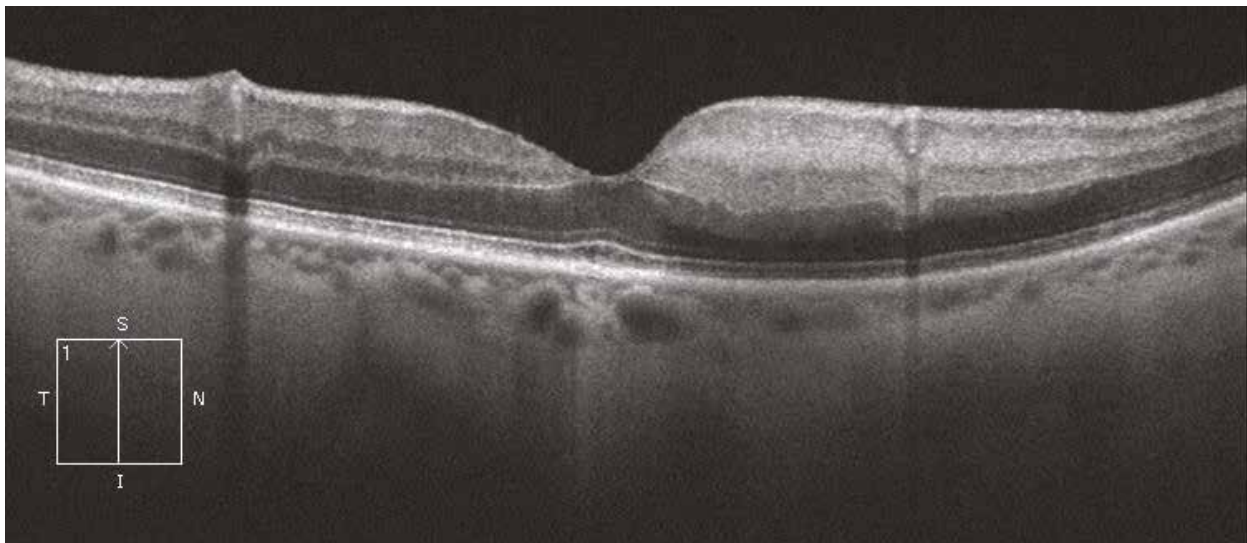
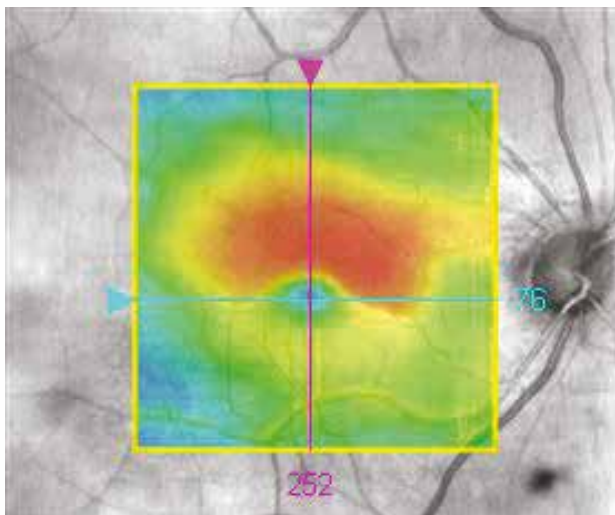
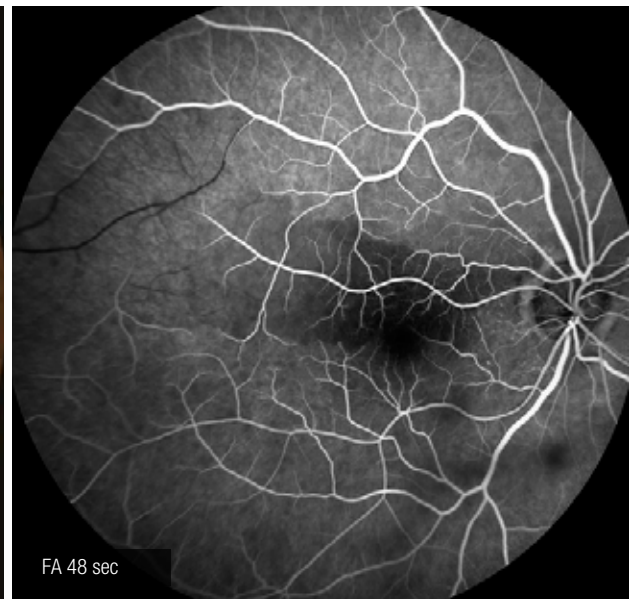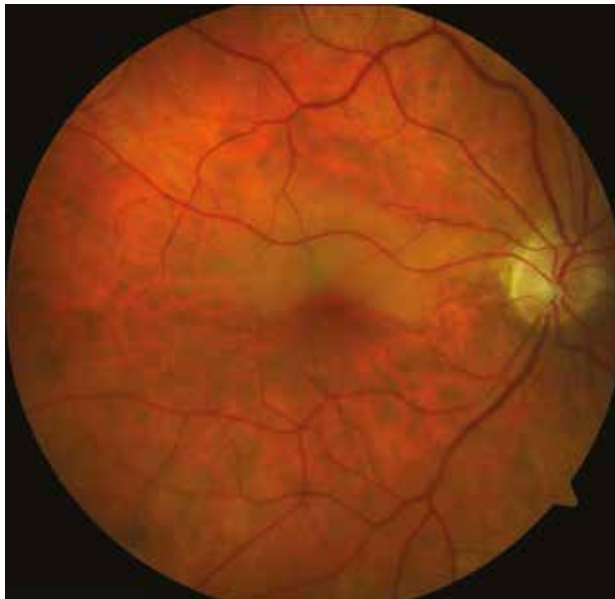Central retinal artery occlusion (CRAO)

Patient with polyvascular diseases and a sudden decrease in visual acuity. The colour image shows an ischaemic retinal oedema contrasting with the foveal region of normal colour and leading to the appearance of the “cherry-red spot”. The OCT shows a hyperreflective thickening of the internal layers of the retina corresponding to the ischaemia of the inner retina. The fluorescein angiography confirms the non-perfusion of the trunk of the central retinal artery.



Branch artery occlusion

The colour image reveals a whitish oedematous region along a temporal branch artery at the level of the superomacular region. The retinal mapping confirms the localised thickening. The OCT reveals the hyperreflective ischaemic and oedematous area of the retinal inner layers in the infarcted area. The fluorescein angiography confirms the poor perfusion of the superotemporal region.



Inflammatory oedema

During uveitis, the macular oedema can take different forms: retinal thickening without fluid, exudative retinal detachment or cystoid oedema, as well as a combination of those forms.

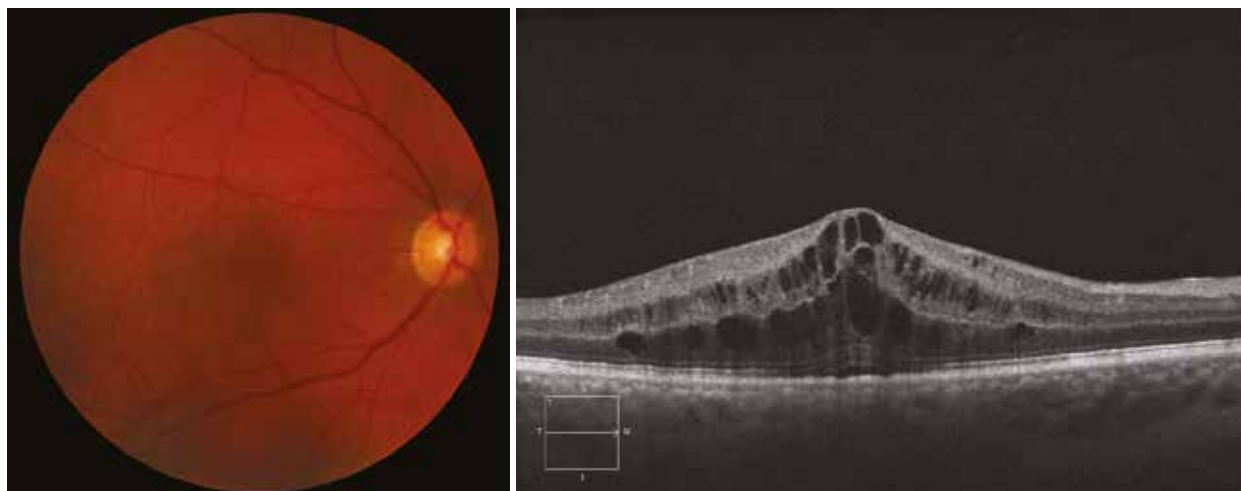
Case 1

This is a case of intermediate uveitis of unknown origin. The colour image does not reveal anything. The OCT section shows a cystoid macular oedema with intraretinal oedema and cystoid cavities.

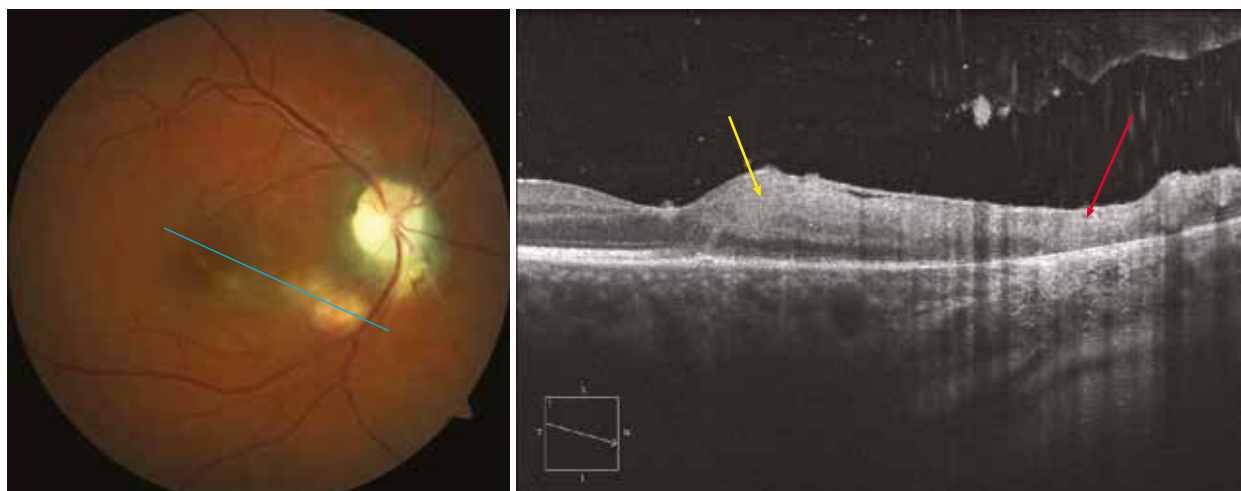
Case 2

In the case of ocular toxoplasmosis, the site of infection is sometimes localised as a slightly hyperreflective area within the inner retina which is globally thickened (yellow arrow). On contact to the active site of infection, there is an atrophied area corresponding to the scar of a former site of infection (red arrow). Also note the hyperreflective points within the vitreous corresponding to inflammatory vitreous condensations.

Case 1



Case 2



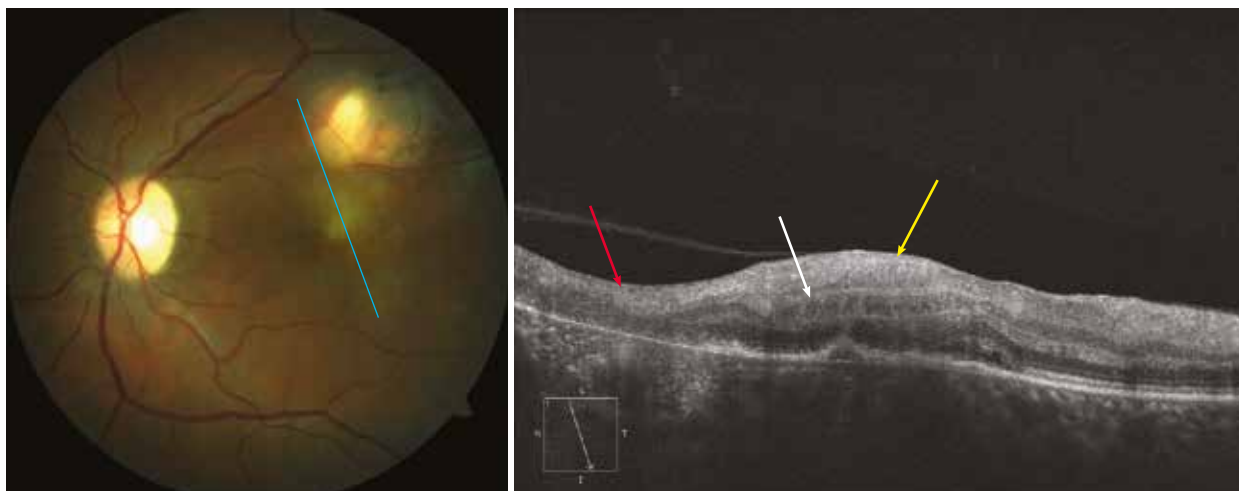
Case 3

A similar case to the above one with, in addition, a discrete intraretinal cystic oedema adjacent to the site of infection (white arrow).

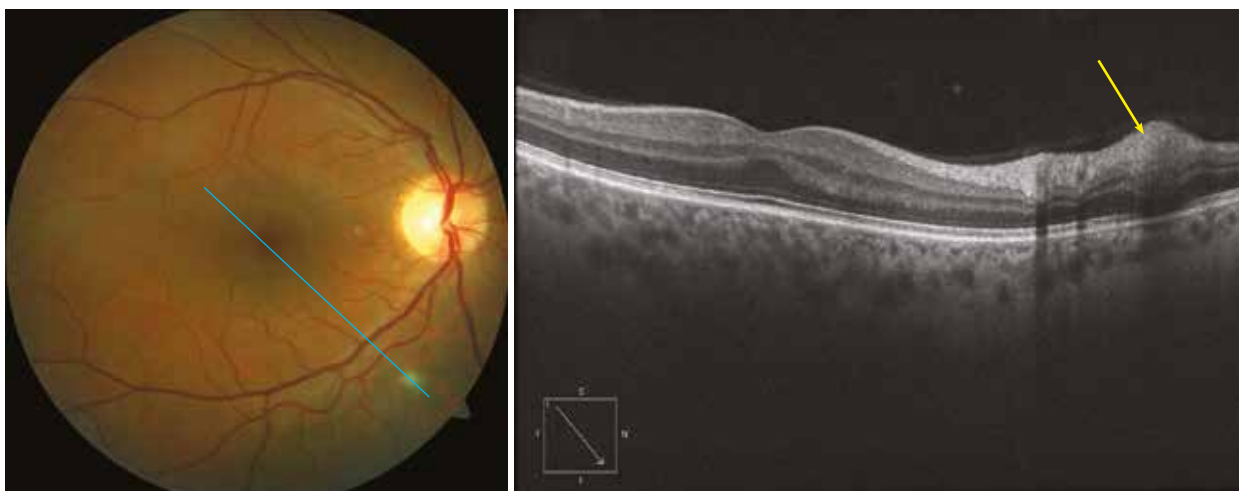
Case 4

In this case of ocular infection due to borreliosis (Lyme's disease), the site of infection is clearly visible within the inner retina (yellow arrow) as a slight rounded hyperreflectivity.

Case 3

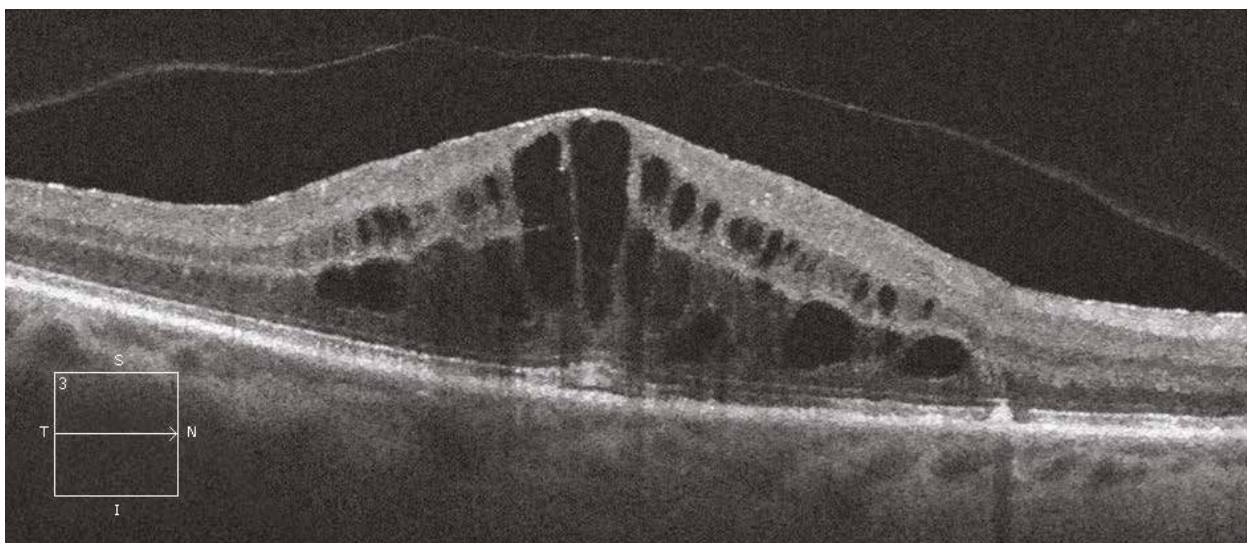
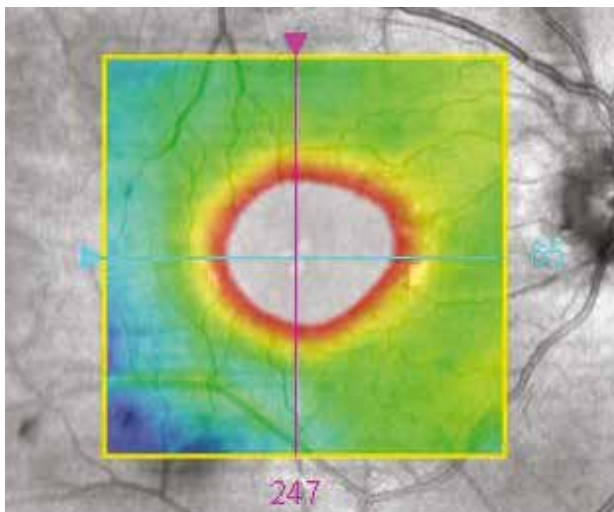
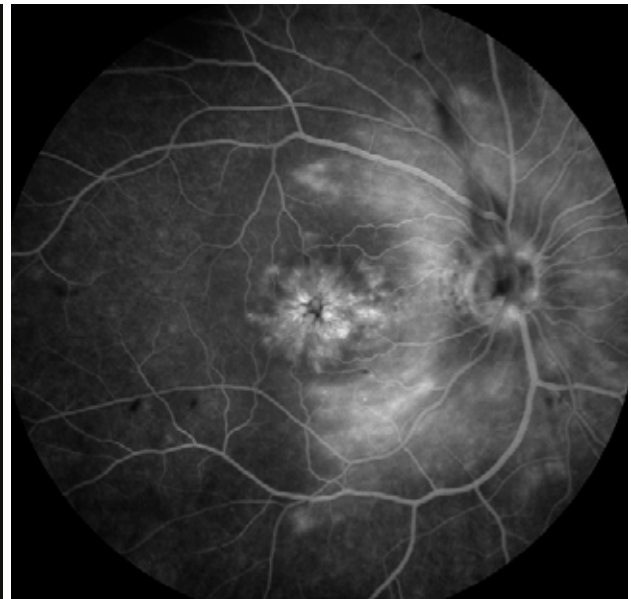
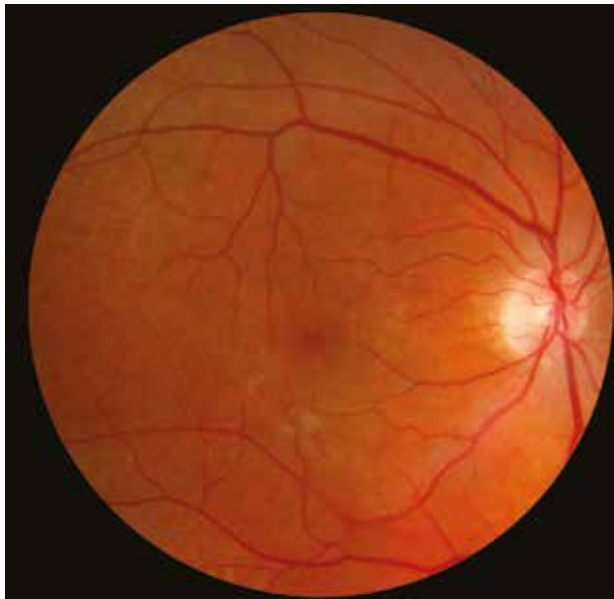


Case 4



Irvine-Gass syndrome

Patient presenting with a decreased visual acuity 4 months after cataract surgery. The colour image shows a change of macular reflection. The OCT reveals a macular thickening clearly visible on the retinal mapping (650 μm), with a cystic appearance on the OCT section in the inner and outer nuclear layers. The angiography shows a macular and papillary diffusion, which strongly supports the diagnosis.



4. Macular telangiectasia

Idiopathic macular telangiectasia

Idiopathic macular telangiectasia corresponds to dilations of the macular capillaries.

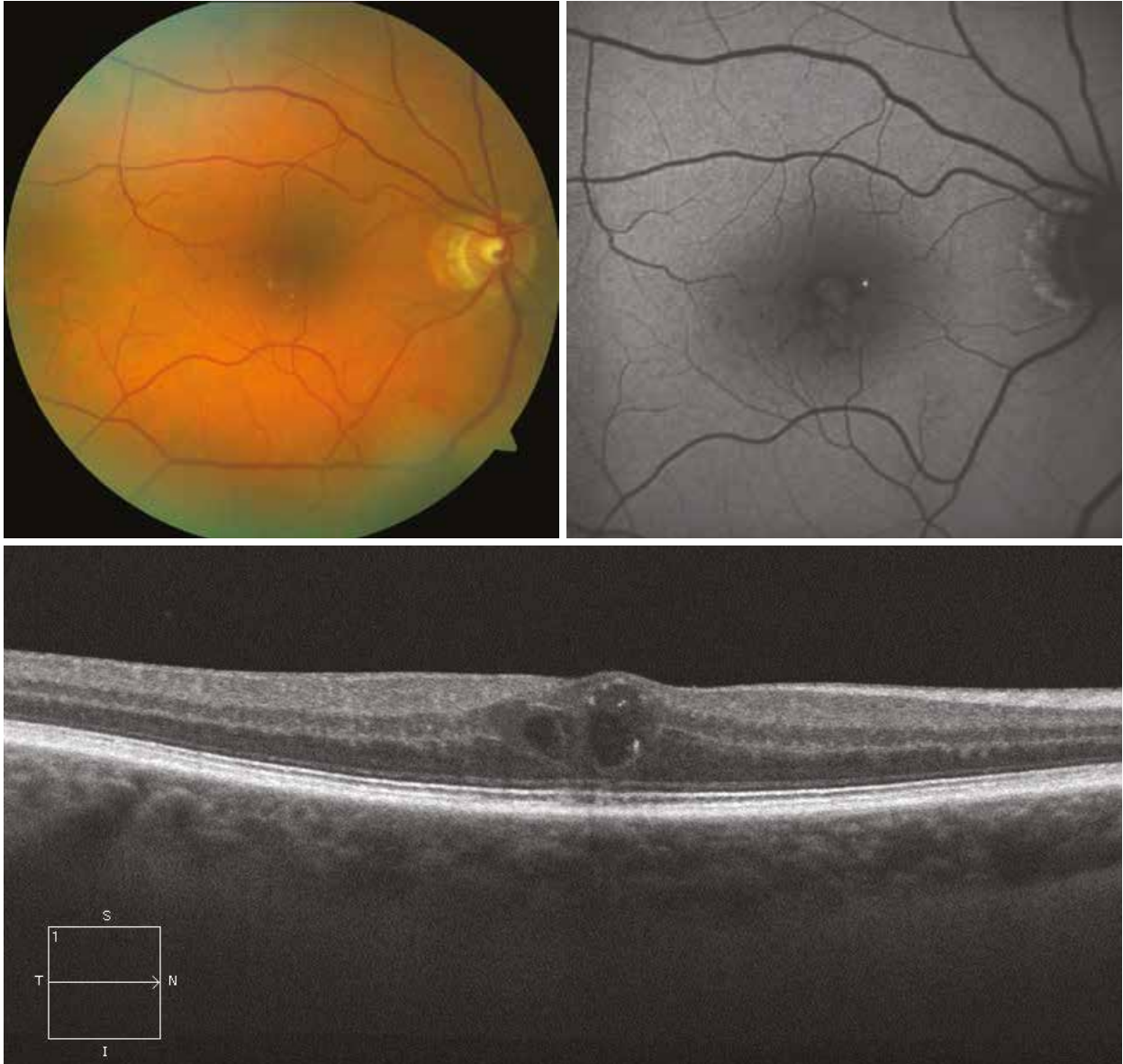Type 1 macular telangiectasia is most often associated with cystoid macular oedema and with Coats-type peripheral telangiectasia. They often lead to the production of exudates. They are unilateral.

Type 2 macular telangiectasia (or Mac Tel 2) is bilateral, poorly visible on the ocular fundus examination and can develop into macular atrophy.

Mac Tel 2 - Case 1

Here, the telangiectasia are presumed on the temporal edge of the macula in the form of small red spots. There are also yellow-coloured refracting spots, which are crystalline deposits of unknown origin. On autofluorescence, the image reveals an almost total disappearance of the macular pigment, as well as of the telangiectasia that appear as small hypoautofluorescent spots. On the horizontal OCT section passing through the fovea, two hyporeflective cavities can be distinguished in the inner retina, which probably correspond to degenerative rather than exudative cysts. The small hyperreflective spots in the inner retina correspond to the yellow crystalline deposits seen on fundus examination. The outer retina is intact, consistently with a recently developed lesion.

Case 1

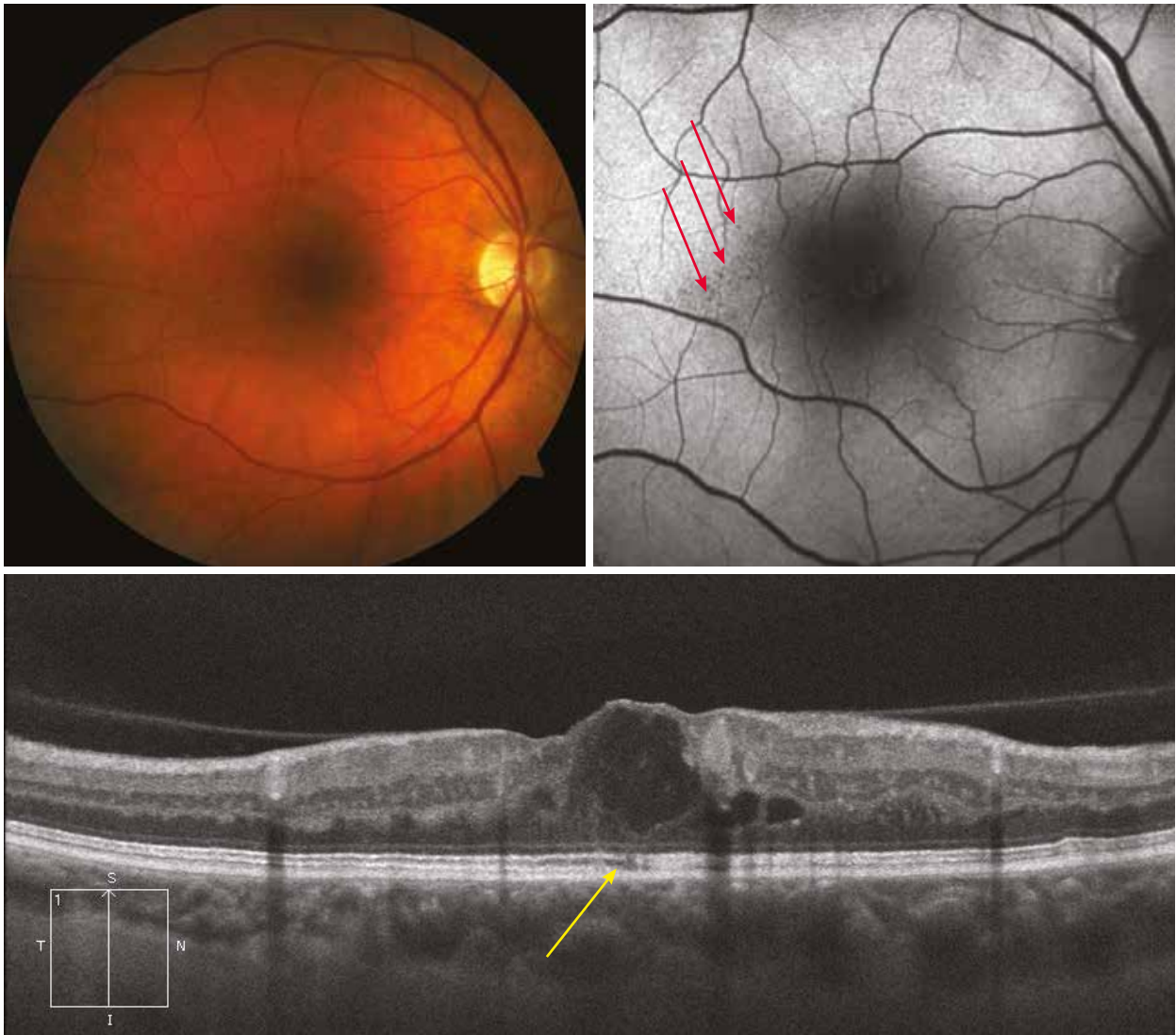


Mac Tel 2 - Case 2

On the colour image, the MacTel 2 is almost invisible. It can be more easily distinguished on the autofluorescence image as small hypoautofluorescent spots (red arrows). Changes in macular pigment distribution are also observed.

A vertical OCT section through the macula reveals a large hyporeflective cavity in the inner retina and two smaller ones. The weakly hyperreflective lesion in contact with the cyst probably corresponds to a migration of altered retinal material. There is a short interruption of the outer retina (yellow arrow), which is consistent with an atrophic lesion.

Case 2



5. AMD

5.1. Early onset AMD or ARM

- 5.1.1. Serous drusen
- 5.1.2. Reticular drusen
- 5.1.3. Cuticular drusen

5.2. Atrophic AMD

5.3. Exudative or neovascular AMD

- 5.3.1. Typical forms
 - 5.3.1.1. Active forms
 - 5.3.1.2. Cicatricial forms
 - 5.3.1.3. Retinal pigment epithelial tear
- 5.3.2. Polypoidal vasculopathy
- 5.3.3. Chorioretinal anastomosis

Serous drusen

Case 1

On the colour image, the drusen can be individualised as deep, small, yellowish lesions spread throughout the posterior pole. There are small- and medium-sized drusen, mostly around the macula, and more peripheral large drusen, so-called serous drusen.

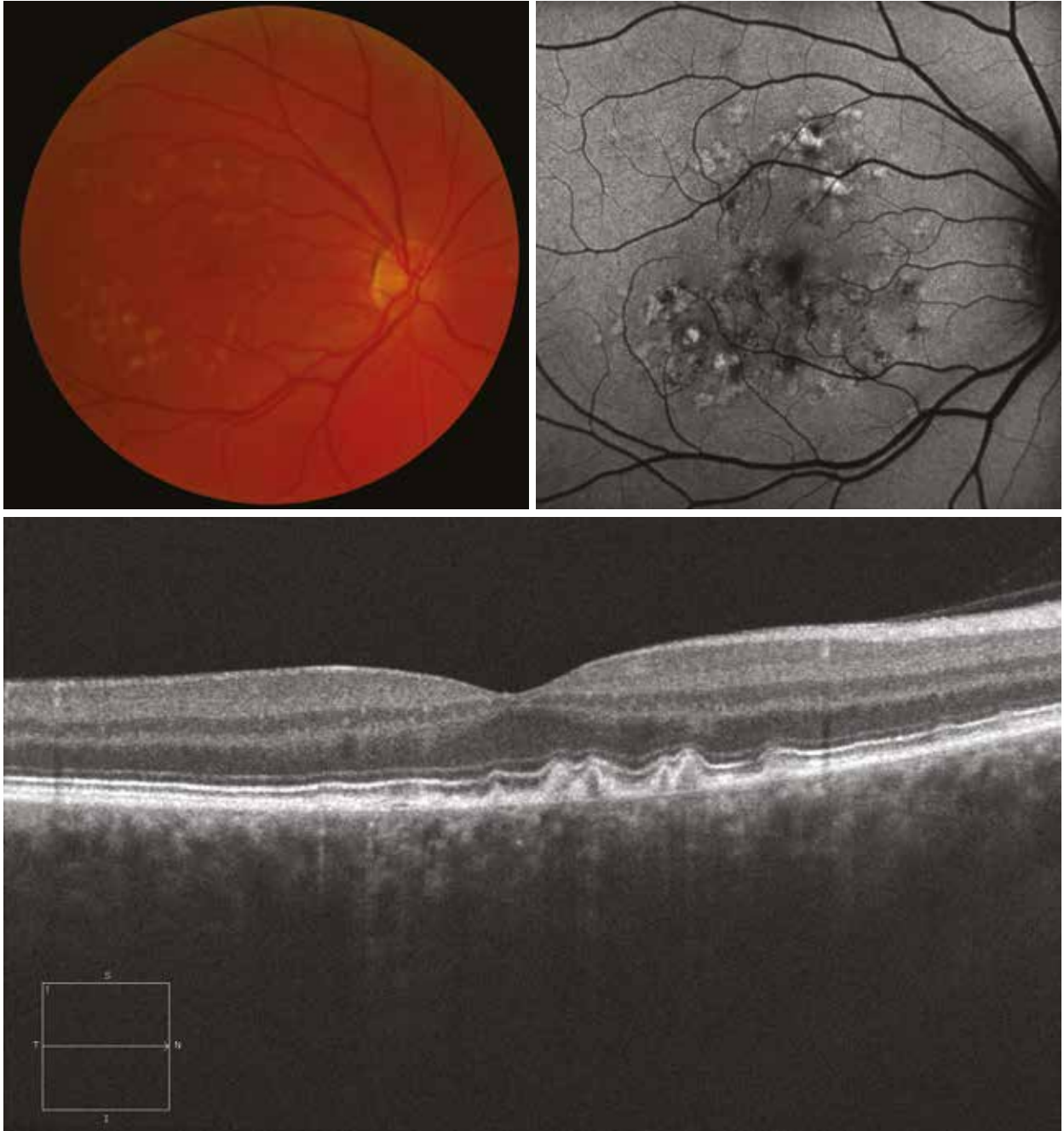
On autofluorescence, the posterior pole is scattered with small hyper- or hypoautofluorescent areas, depending on the rate of lipofuscin which compose the drusen. Finally, there is a narrowing of the macular hypoautofluorescence, indicating a change in the macular pigment distribution.

On the horizontal OCT section, the small- and medium-sized drusen are shown as discrete elevations of the pigment epithelium. The reflectivity of these drusen is variable and attests the variable nature of their components.

The boundary line between the inner and outer segments of the photoreceptors and the external limiting membrane shows the same deformations as the retinal pigment epithelium, without interruption. No large drusen are shown since the section does not pass through the areas where they are found.

The inner retina is unaltered.

Case 1



Case 2

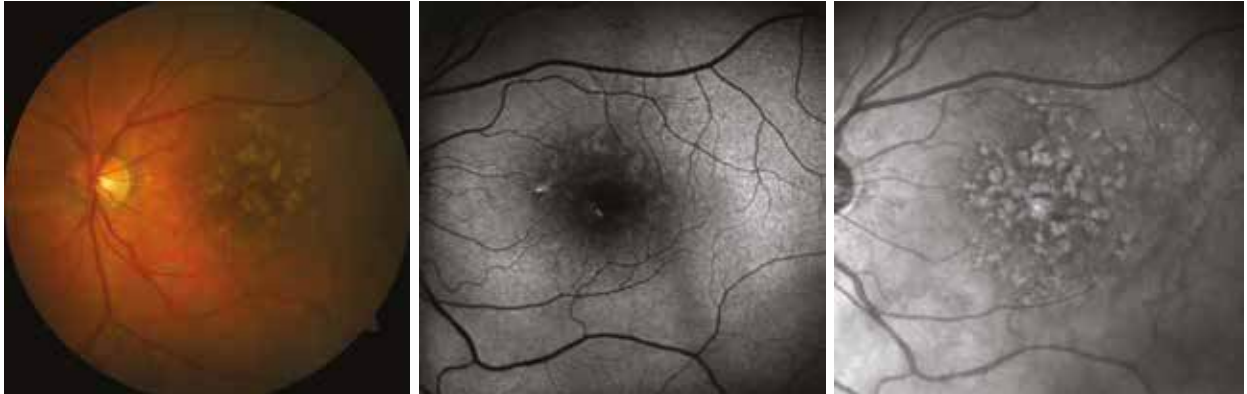On the colour image, numerous drusen are visible in the macular region. Some are confluent. There are also small dark lesions corresponding to pigment migrations.

Here, there is little change on autofluorescence imaging, with some small hyperautofluorescent areas and a preserved macular hypoautofluorescence. Conversely, the infrared image is greatly altered, showing numerous drusen as rounded hyperreflective lesions, indicative of the high content of pigment material in the composition of the drusen.

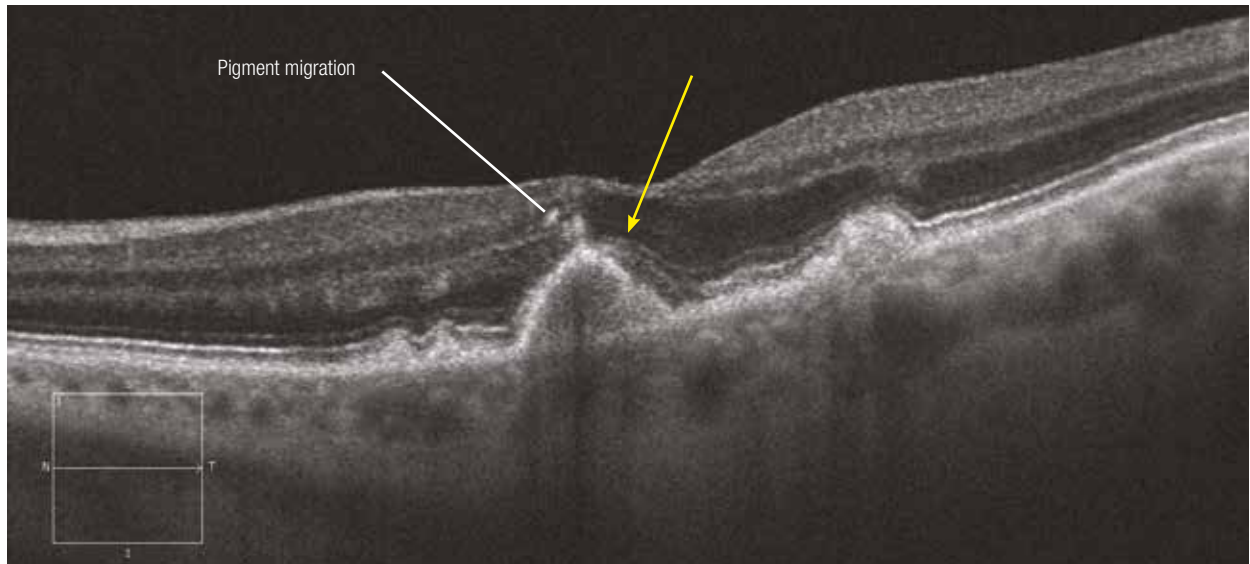
The horizontal OCT section reveals one large drusen (round-shaped), one medium and two small ones. These drusen are associated with an alteration of the neurosensory retina. In fact, at the level of the large drusen, there is a disruption of the photoreceptor layer and of the external limiting membrane, indicating a loss of photoreceptors (yellow arrow). There is also a thinning of the outer nuclear layer. Finally, there are small hyperreflective spots at the apex of the drusen located in the outer nuclear layer. These hyperreflective spots are attributed to the pigment migrations visible on the colour image.

On the vertical section, in addition to the clearly visible hyperreflective spot at the apex of the large drusen, the inner limit of the outer nuclear layer is blurred and irregular. This appearance is attributed to parts of the Henle's fibre layer made visible by the change in the incidence angle of the OCT beam (red arrows). This alteration is related to the change in retinal topology by the drusen.

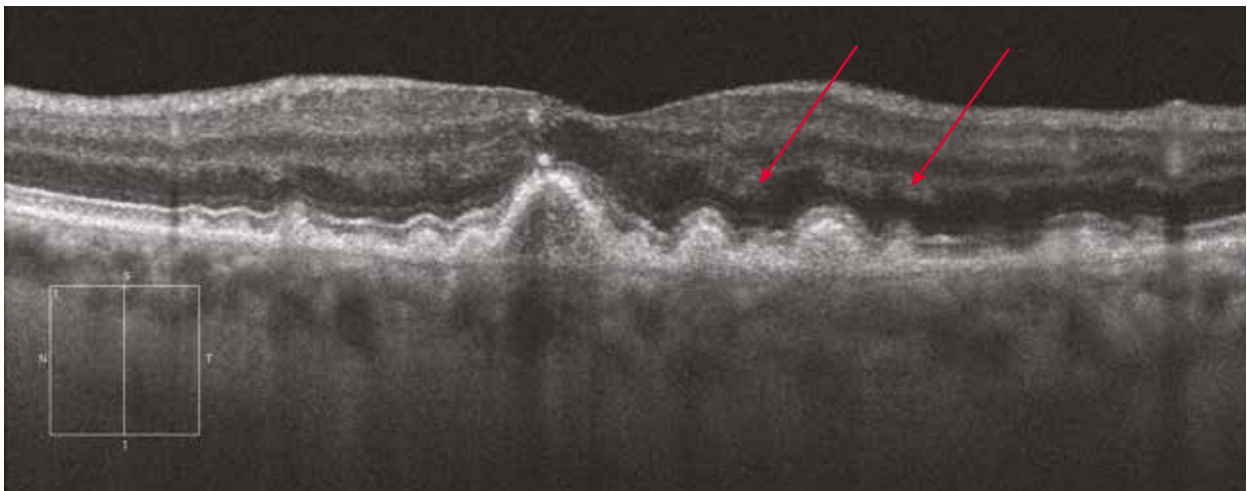
Case 2



Horizontal section



Vertical section



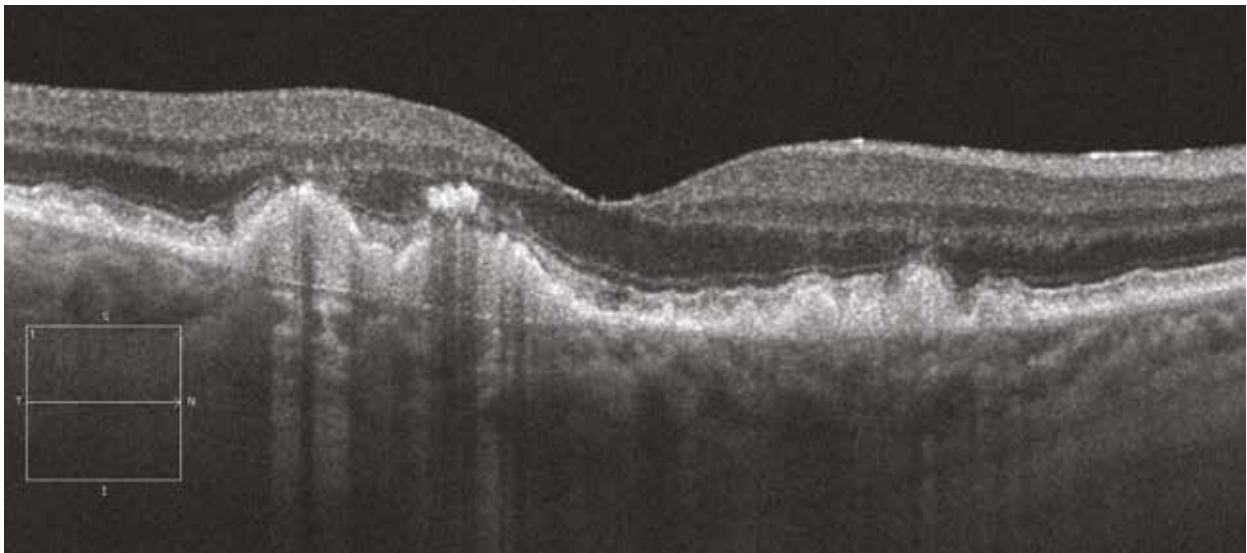

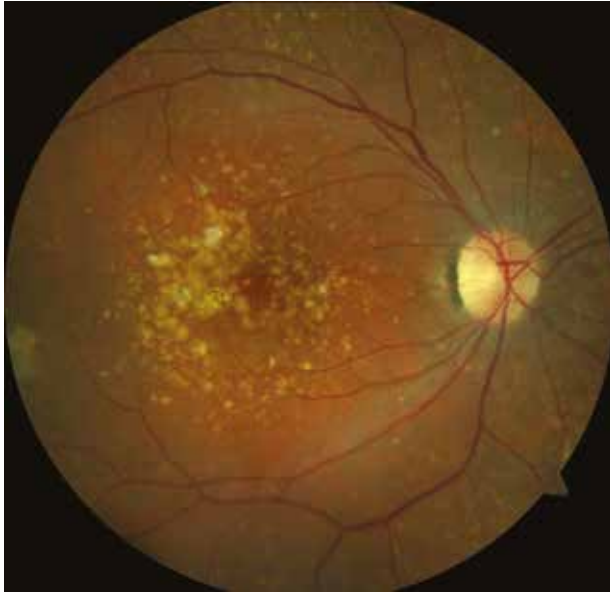
Case 3

On the colour image, note the presence of a large number of drusen of all sizes, some of which being confluent. These drusen are associated with pigment migrations.

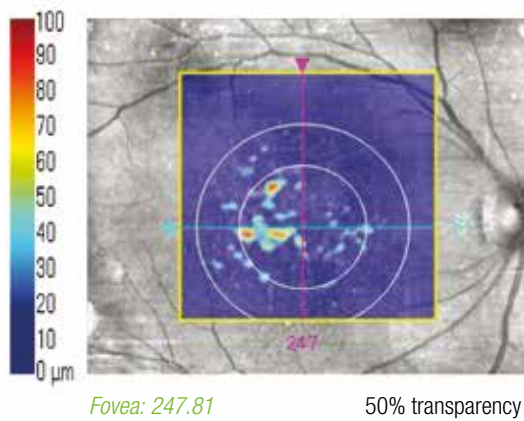
The horizontal OCT section shows a succession of pigment epithelium elevations corresponding to drusen of various sizes. At the level of the two largest drusen, there is a pigment migration at their apex, in the outer nuclear layer. There is also a disruption in the photoreceptor line and the external limiting membrane.

On a longitudinal OCT section, the retinal pigment epithelium (RPE) deformations by the drusen are clearly visible (mapping). It is also possible to calculate the surface and the volume of areas of RPE elevations at different visits. In this case, values were recorded and compared at two visits made two years apart. In the central 3 mm, there is a 100% extension of the drusen surface area during a two-year period and a 160% increase in volume over the same period.

Case 3

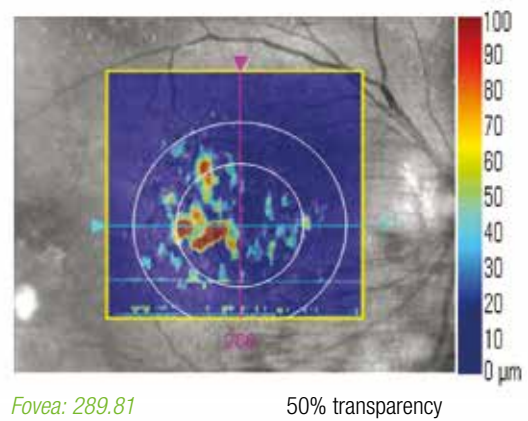


Previous visit



Map of RPE elevations

Current visit



Reticular drusen

Cases 1, 2 and 3

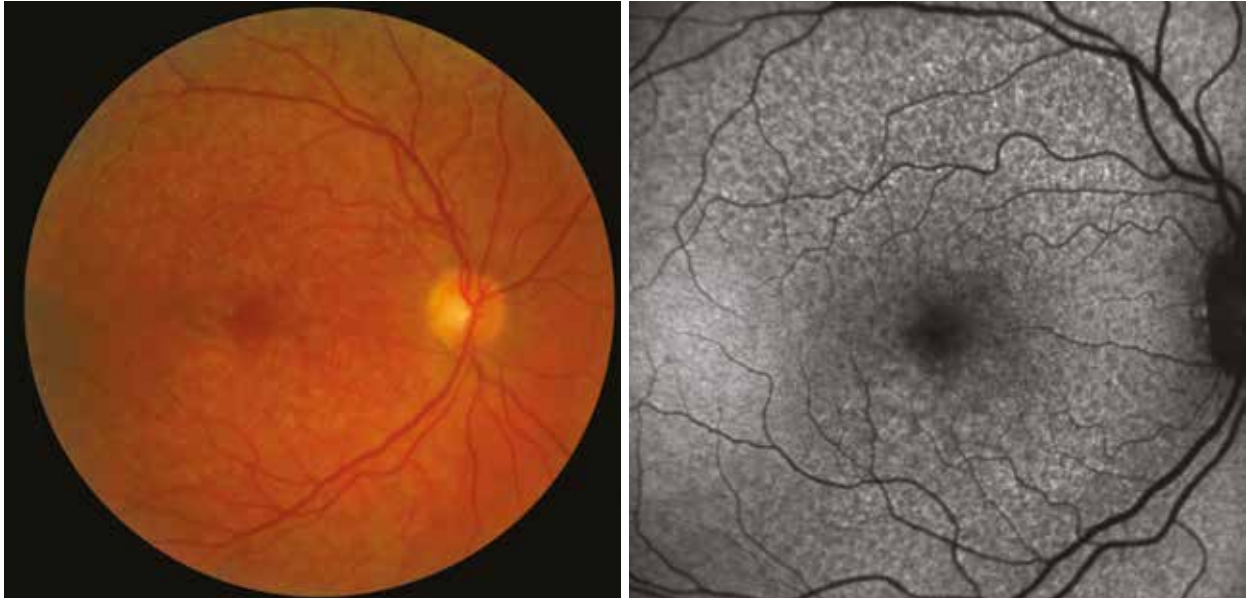It is important to identify these drusen because of their greater risk of neovascular AMD complication compared with large drusen.

In colour, they appear as small, discrete, yellowish deposits. They are most visible under blue light imaging (or autofluorescence). They are seen as hypoautofluorescent areas.

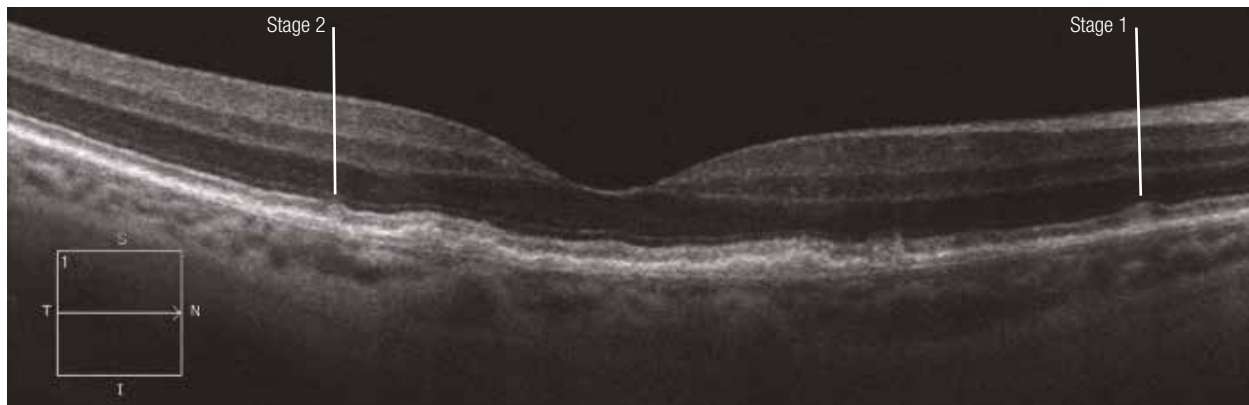
On OCT, these drusen are characterised by the presence of hyperreflective granular material between the RPE and the photoreceptor line. They are, therefore, located in the subretinal space.

There are three stages of progression. Stage 1 corresponds to the deposit of hyperreflective granules in the subretinal space. In stage 2, the accumulation of material is more important and alters the photoreceptor line. Stage 3 is defined by the conical appearance of the drusen with interruption of the photoreceptor line through their apex. In addition, the thickness of the choroid is reduced.

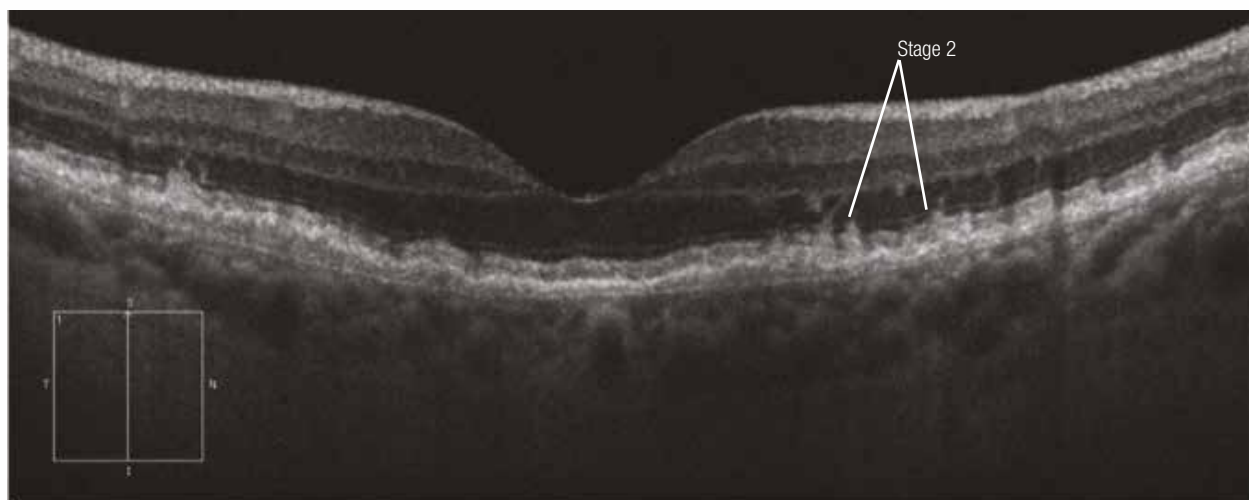
Case 1



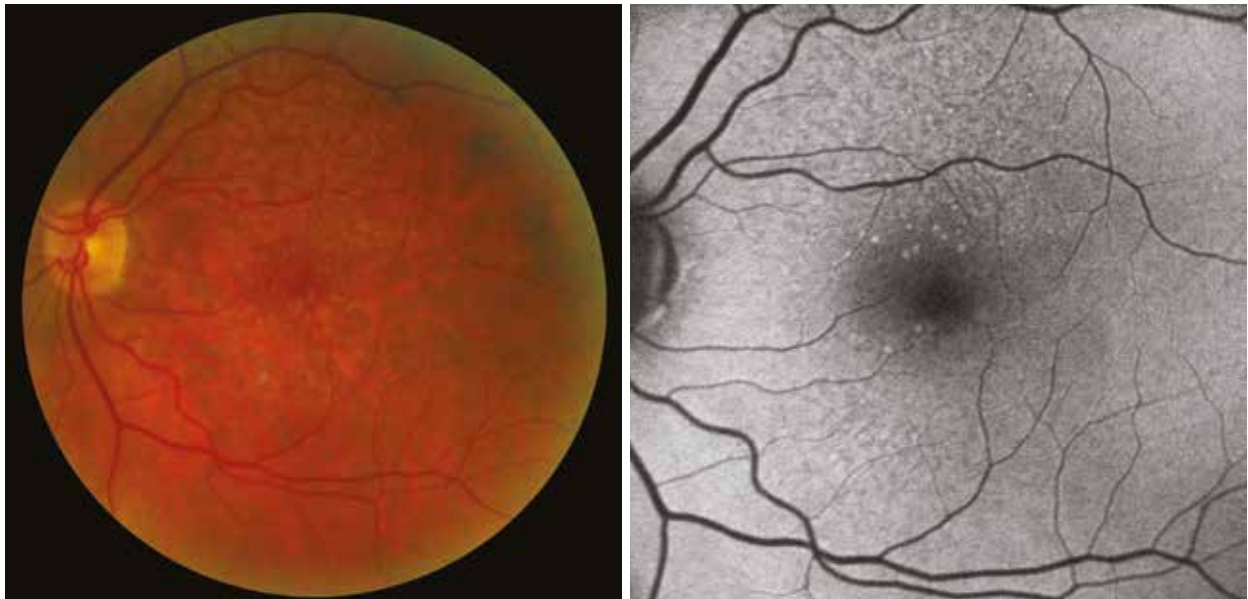
Horizontal section



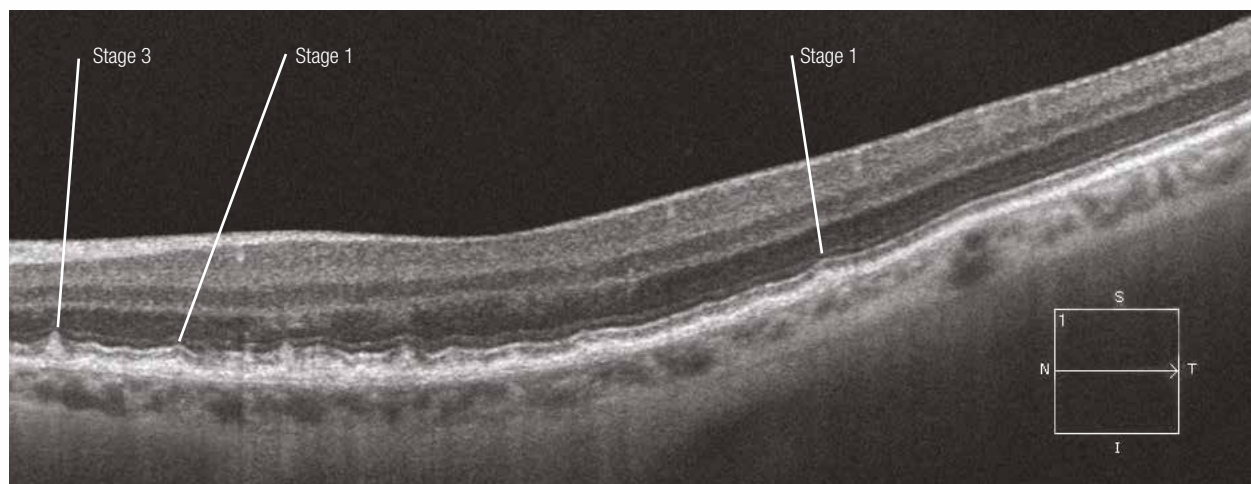Vertical section



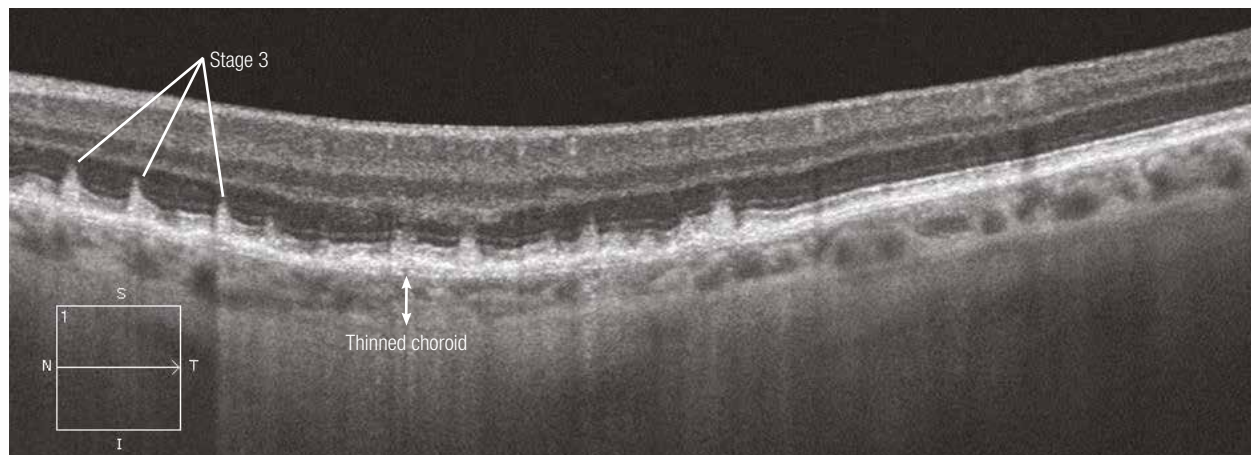
Case 2



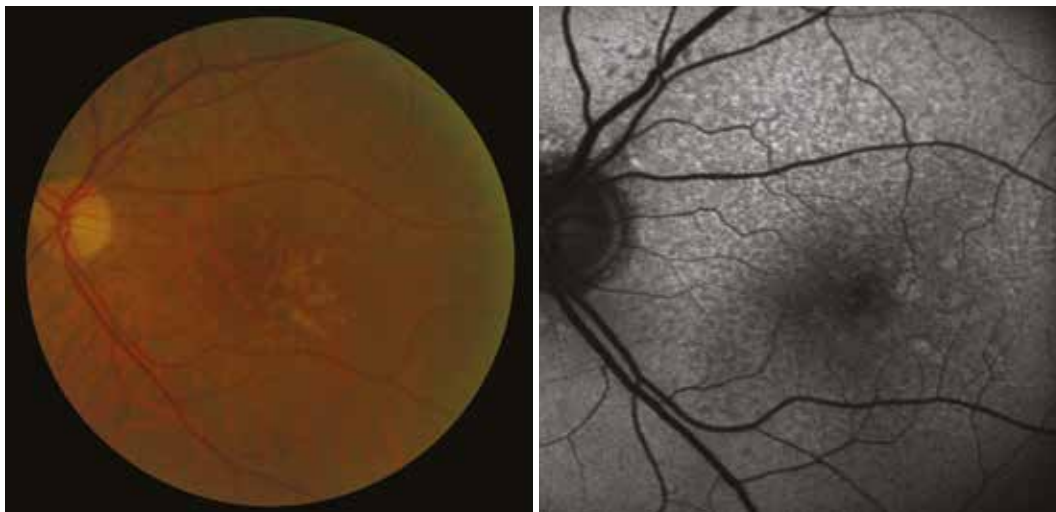
Horizontal submacular section



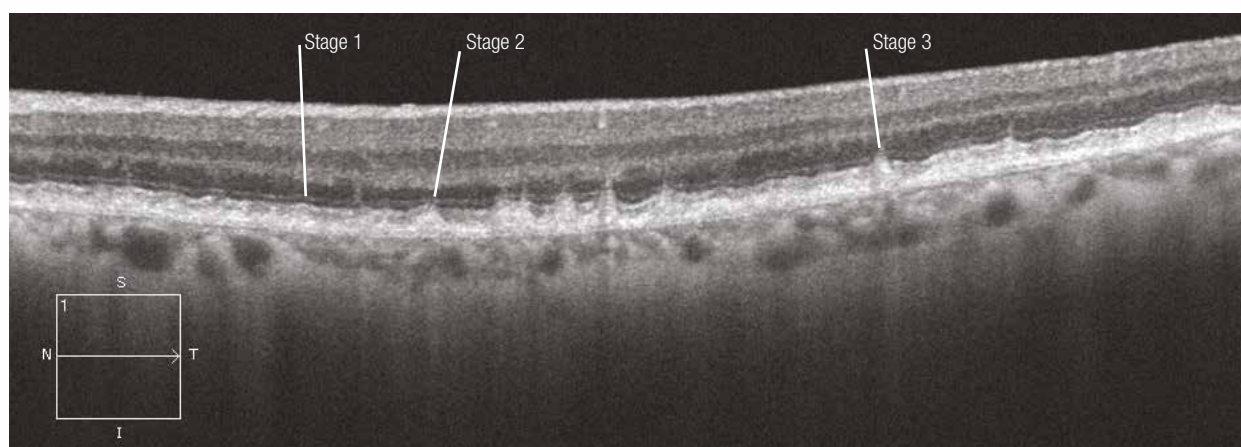
Horizontal submacular section in EDI mode



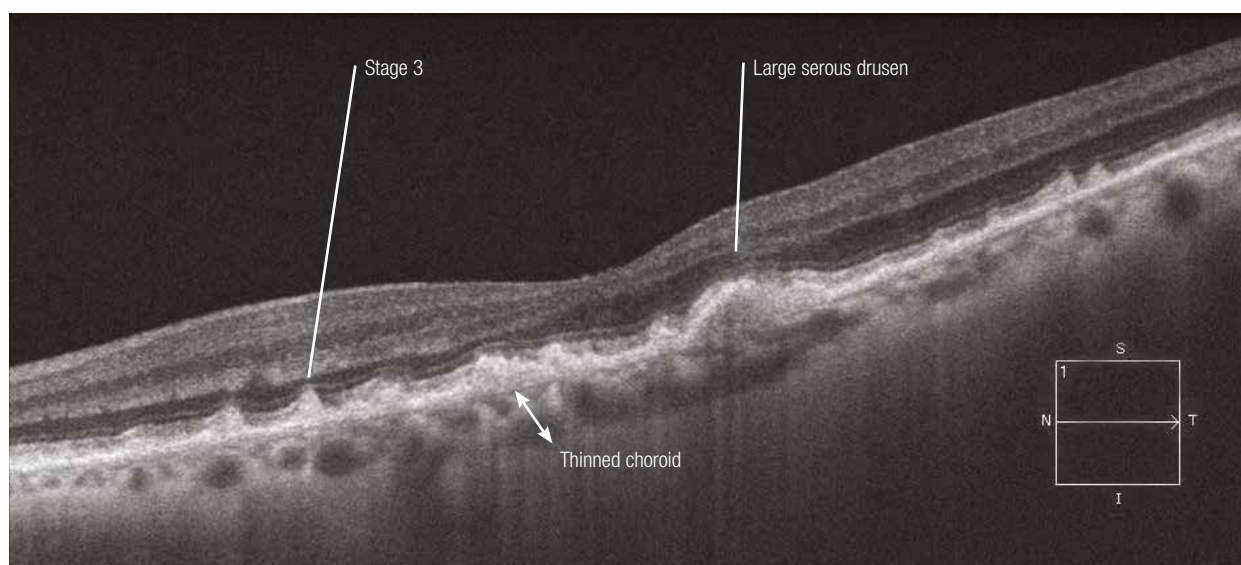
Case 3



Horizontal submacular section



Horizontal submacular section in EDI mode

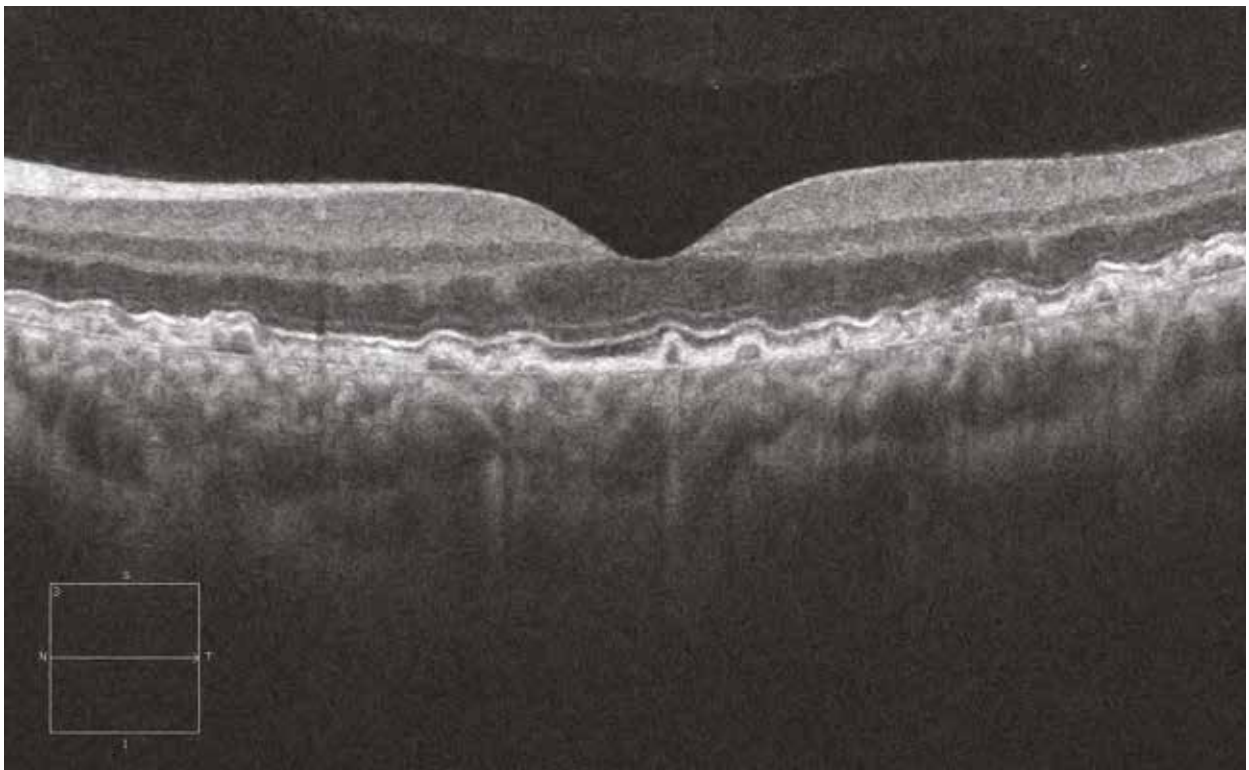
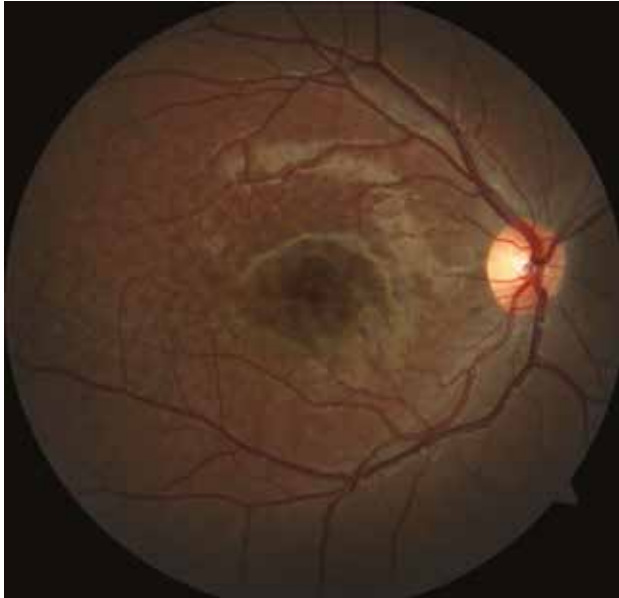


Cuticular drusen

These drusen are always very numerous, small, round and uniform in size. On the OCT, the regular deformations of the RPE have a sawtooth-like appearance, with an undulation (and sometimes interruption) of the photoreceptor line and the external limiting membrane.

They are sometimes associated with pseudovitelliform dystrophy. They have a genetic component.

Opposite image: the fundus examination and OCT of a 15-year-old man with cuticular drusen.



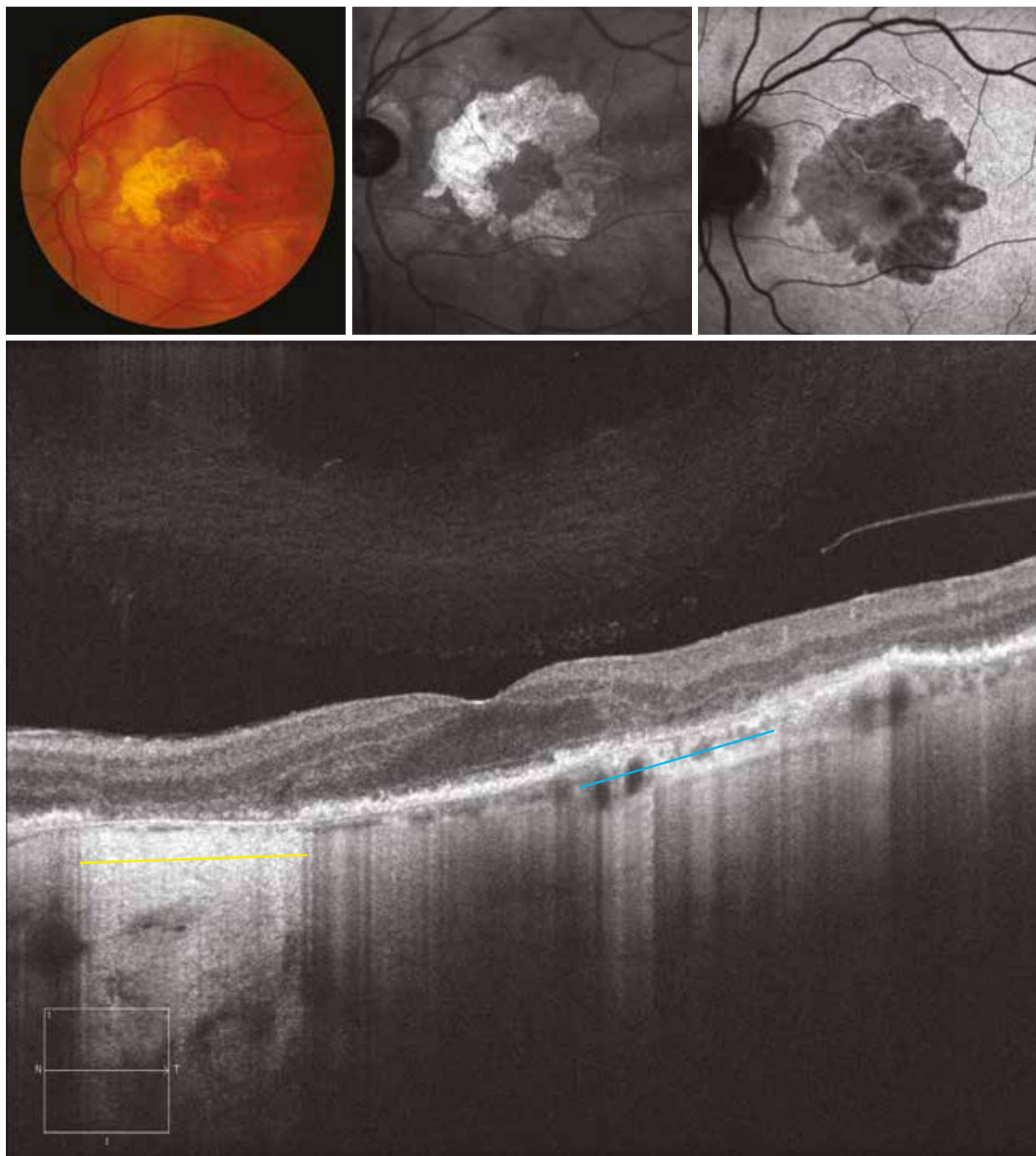
Atrophic AMD

Case 1 - Atrophic AMD

The colour image shows central areolar atrophy with macular sparing. The sparing is more visible on infrared images than on autofluorescence imaging. In fact, on autofluorescence images, the atrophy and the macula are both hypoautofluorescent.

The OCT (horizontal section) shows the macular sparing with all retinal layers being unaffected. On either side of the macular area, the outer retina is either thinned (blue area) or has disappeared (yellow area). Due to the disappearance of the retinal pigment epithelium, the reflectivity of tissues located behind is increased. Note, here, a major thinning of the choroid adjacent to the atrophy.

Case 1

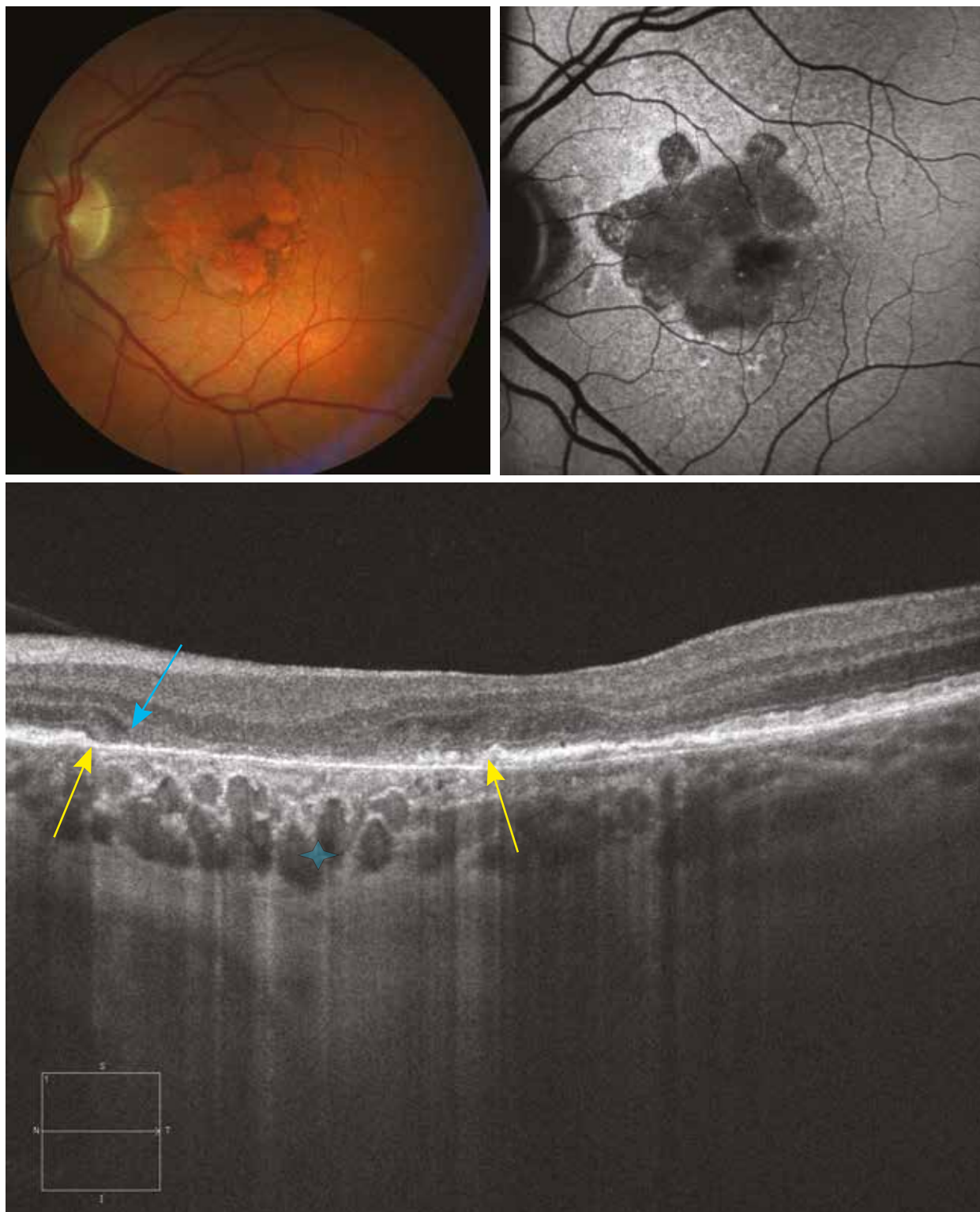


Case 2 - Atrophic AMD

The colour and autofluorescence images are superimposable. On autofluorescence, there is a hyperautofluorescent border around the atrophy, which generally accounts for an increased risk of atrophy progression.

The OCT analysis (horizontal section) in EDI mode allows the choroid to be more easily visualised in the area of retinal atrophy, while it is less visible where the retinal pigment epithelium is preserved. The collapse of the outer retinal layers (blue arrow) on the edges of the atrophy and the interruption of the photoreceptor line and the external limiting membrane (yellow arrows) are seen.

Case 2

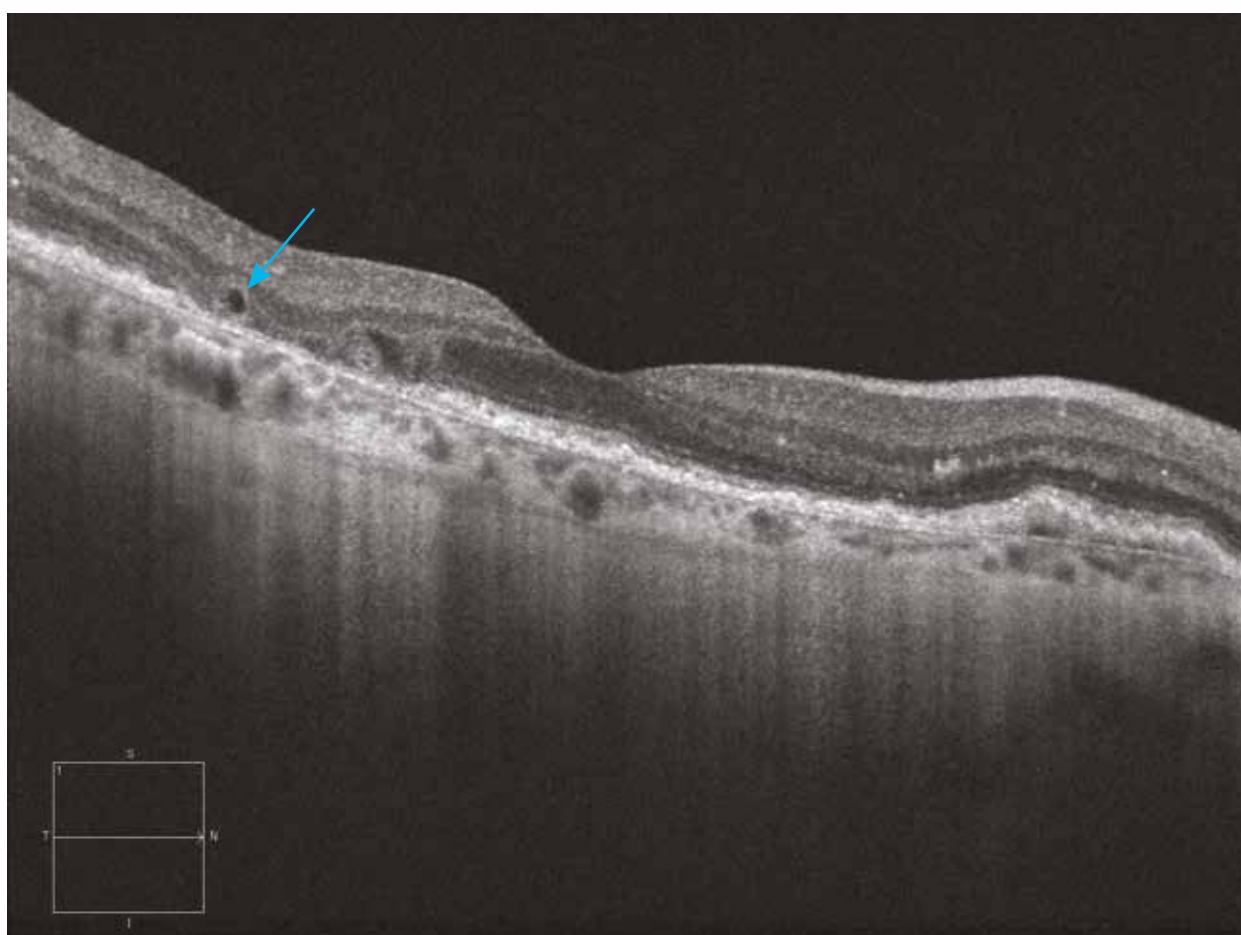
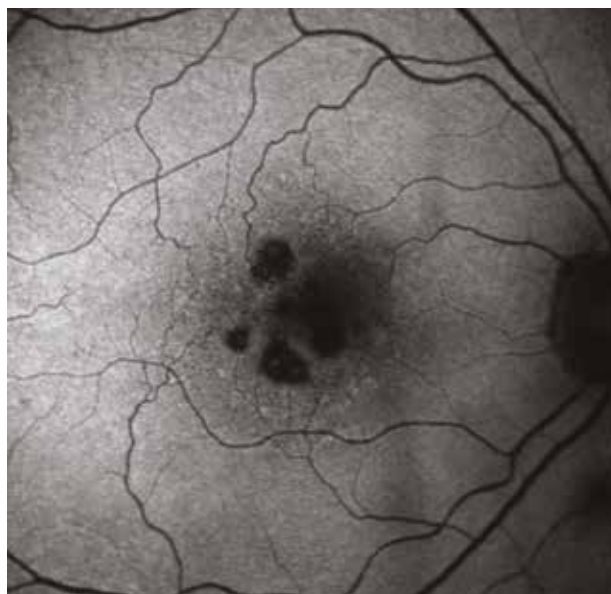
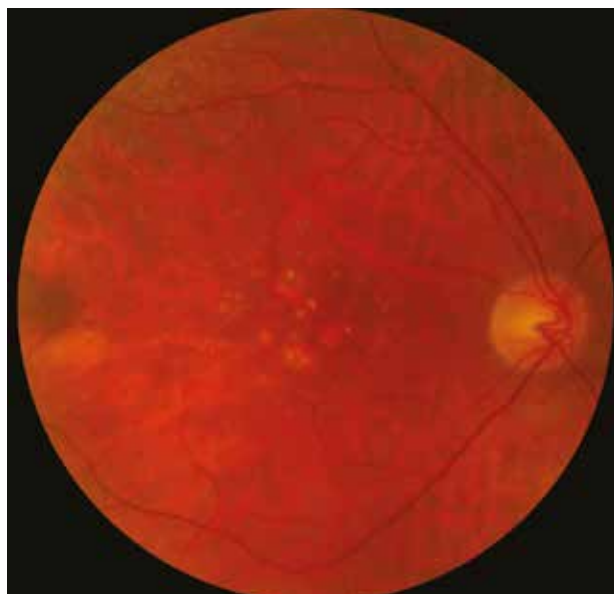
Case 3 - Atrophic AMD and cysts

The colour and autofluorescence images show areas of perimacular retinal atrophy. The central macula appears unaffected.

The OCT section (horizontal) confirms the macular sparing. It also reveals one hyporeflective cavity (blue arrow), perfectly round, located in the outer retina adjacent to atrophied areas. These cysts are part of the OCT pattern of the atrophic AMD; they have been described as cicatricial lesions. These are not cysts associated with a neovascular complication.

Case 3

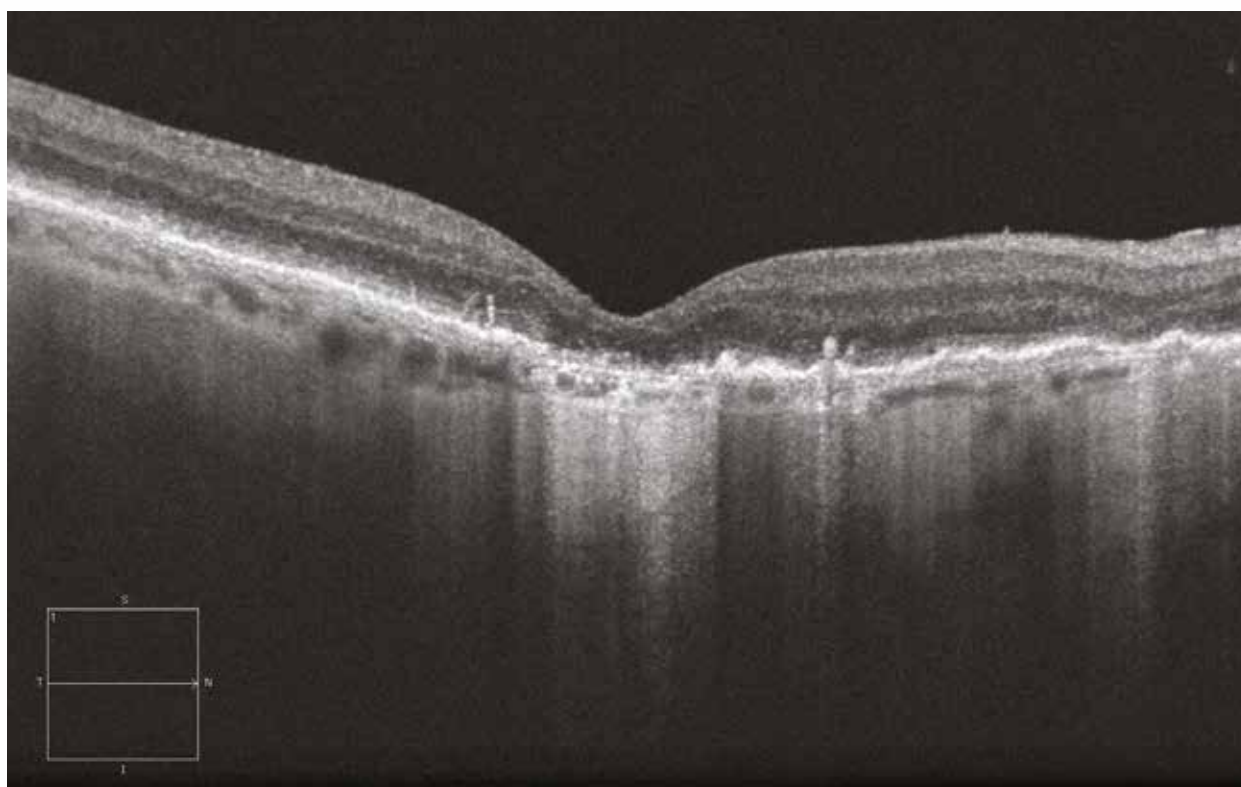
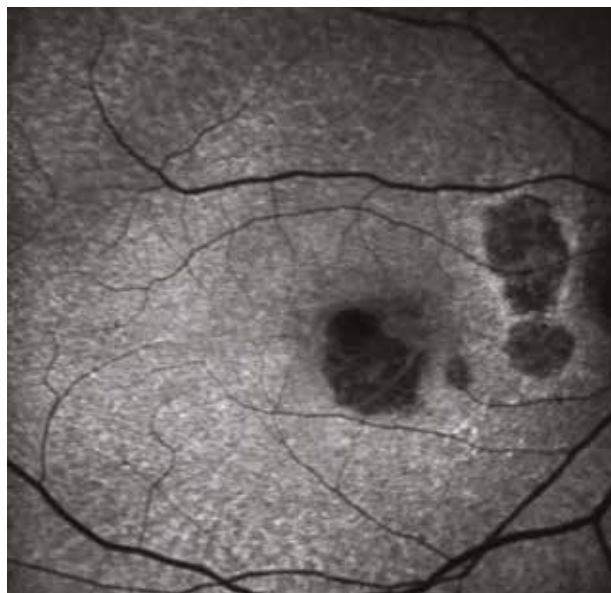
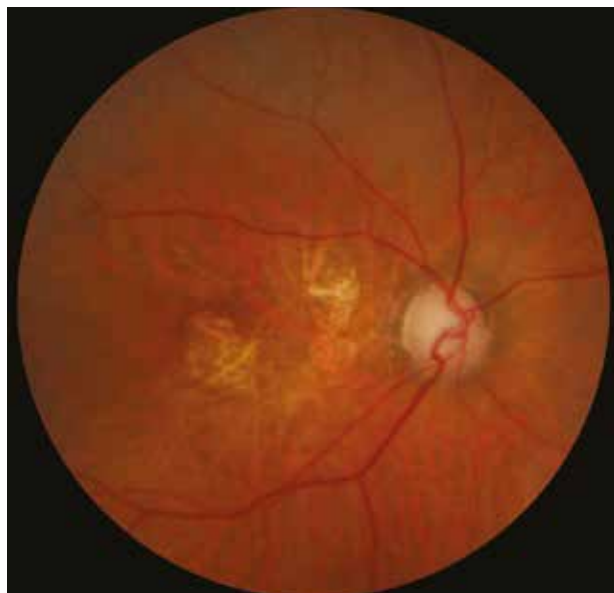

Case 4 - Atrophic AMD and reticular drusen

The colour and autofluorescence images show the characteristics already described for atrophy and reticular drusen.

On the OCT section (horizontal), there is a thinning of the retina with a disappearance of the outer layers, as well as a disappearance of the pigment epithelium and a consequent increased reflectivity of the posterior tissues (choroid and sclera). This feature is typical of central atrophy. The OCT section does not pass through the reticular drusen located more towards the periphery. In contrast, as already described, there are small hyperreflective clusters above the drusen.

Case 4



Neovascular AMD: active forms

OCT examination represents a key-element for both diagnosis and follow-up of neovascular AMD. When referring to the basic scheme of choroidal neovascularisation, it becomes easier to understand the different lesions observed on OCT images.

The choroidal neovessels grow across a rupture in the Bruch's membrane either under the retinal pigment epithelium (RPE) or under the retina. These immature vessels induce a more or less significant exudation as well as haemorrhages, leading to abnormal compartmentalisation under the RPE (and resulting in pigment epithelium detachment [PED]) or under the retina (leading to serous retinal detachment [SRD]). Moreover, invasion of the retina by the neovessels leads to an alteration of central fovea organisation, a remodelling of the extracellular space with infiltration of non-retinal cells such as fibroblasts. All of these alterations culminate in the formation of a disciform scar with destruction of the RPE and the overlying photoreceptors as well as a disruption of the inner retina.

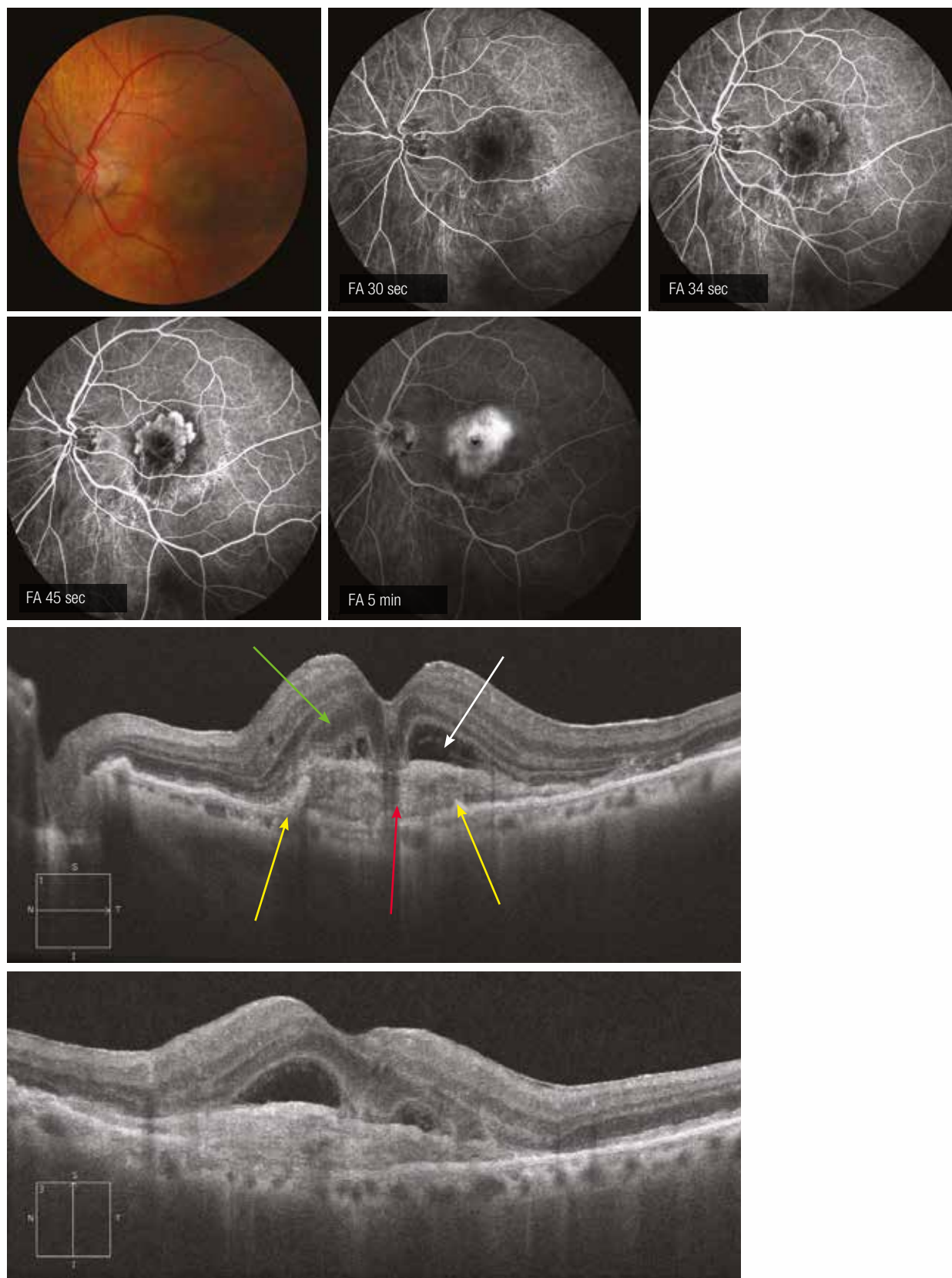
Case 1 - Pre-epithelial neovessels

The colour image reveals a yellowish formation adjacent to the macula and away from fine exudates in temporal of the lesion.

The angiography is characteristic of a so-called "visible" neovascular membrane with early filling phase of the spoke-wheel pattern lesion. In later phases, the lesion is impregnated and a leakage is observed.

On the horizontal OCT section, the neovascular lesion appears as a fusiform hyperreflectivity (red arrow) located above the destroyed RPE (yellow arrows). Above the lesion, there is a moderate SRD (white arrow). There is also a thickening of the outer nuclear layer (green arrow). The same abnormalities are found on the vertical section.

Case 1



Case 2a - Fibrovascular PED

When the neovascular proliferation is located under the RPE, it can induce a PED, the liquid of which appears hyporeflective but may contain moderately hyperreflective elements. The case presented here illustrates the fibrovascular aspect of a PED (red arrow) with an overlying SRD. In addition, the RPE is globally remodelled and, in one area, the photoreceptor line and the external limiting membrane are interrupted (yellow arrow). Finally, because of the PED weak thickness, the Bruch's membrane is distinguished as a fine hyperreflective line (white arrow).

Note that the colour image is normal.

Case 2b - Fibrovascular PED

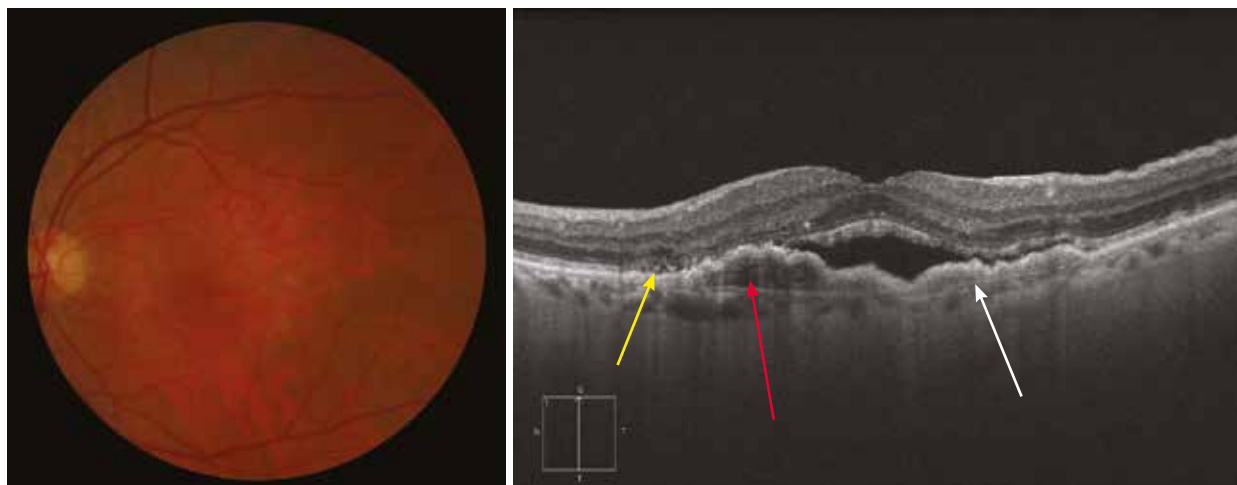
This case is similar, but of very recent diagnosis. The neovascular membrane is subepithelial, leading to SRD containing numerous hyperreflective elements.

Case 3 - Haemorrhagic PED

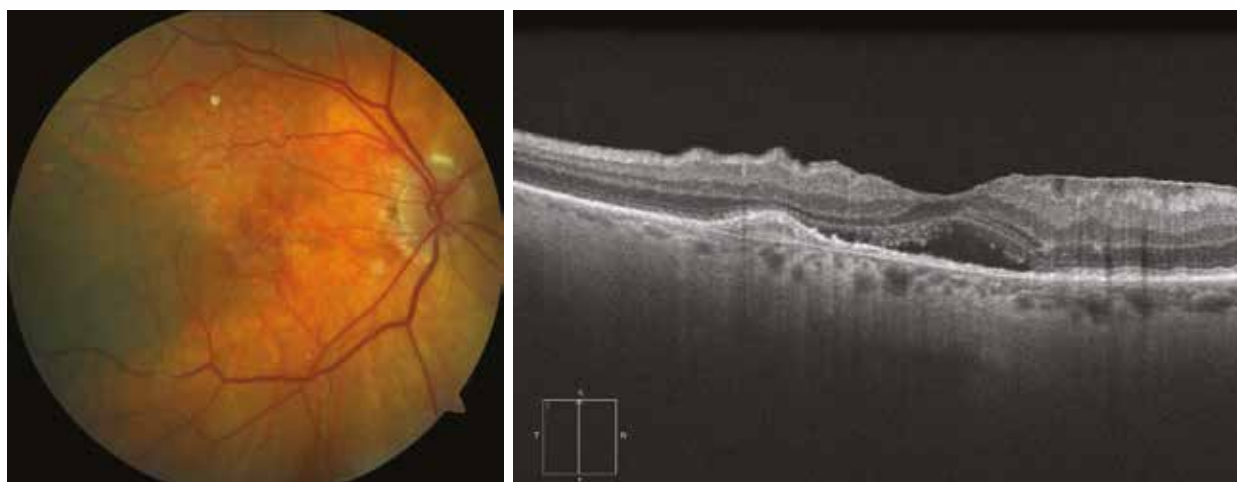This case is almost similar to the previous one, except that some blood, clearly visible on the colour image, appears in the fibrovascular PED (red arrow).

Here, the outer retinal layer is intact.

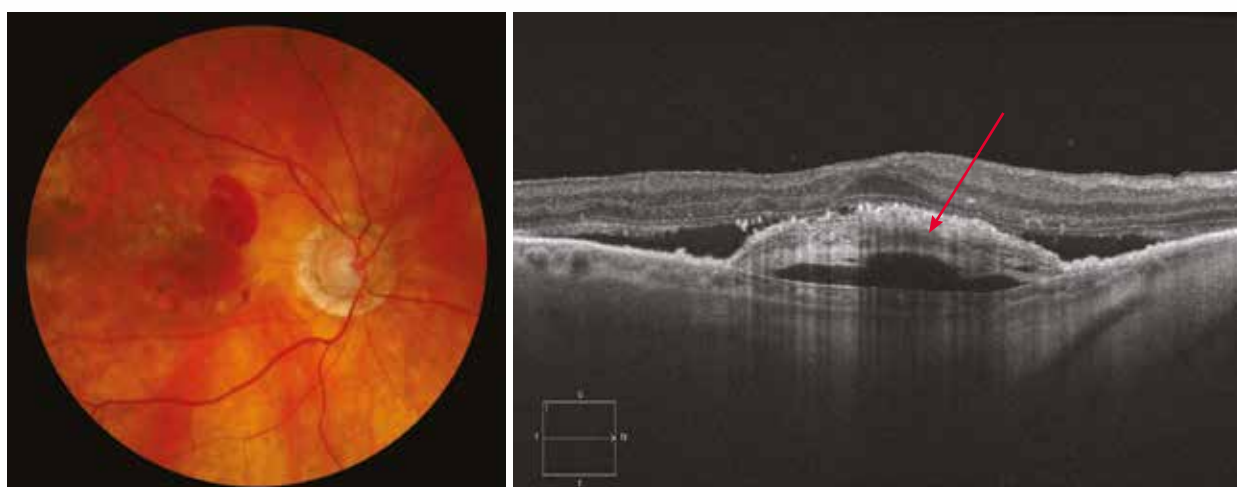
Case 2a



Case 2b



Case 3



Case 4 - Serous PED

Serous PEDs are characterised on OCT by the extent of their exudation, giving them a dome-shaped appearance. These PEDs are readily visible on the fundus examination and fill very early during angiography (here in 18 sec), with sometimes the visualisation of a hot spot, corresponding to the feeder vessel and of a small notch on their margin at the later phase (yellow arrow).

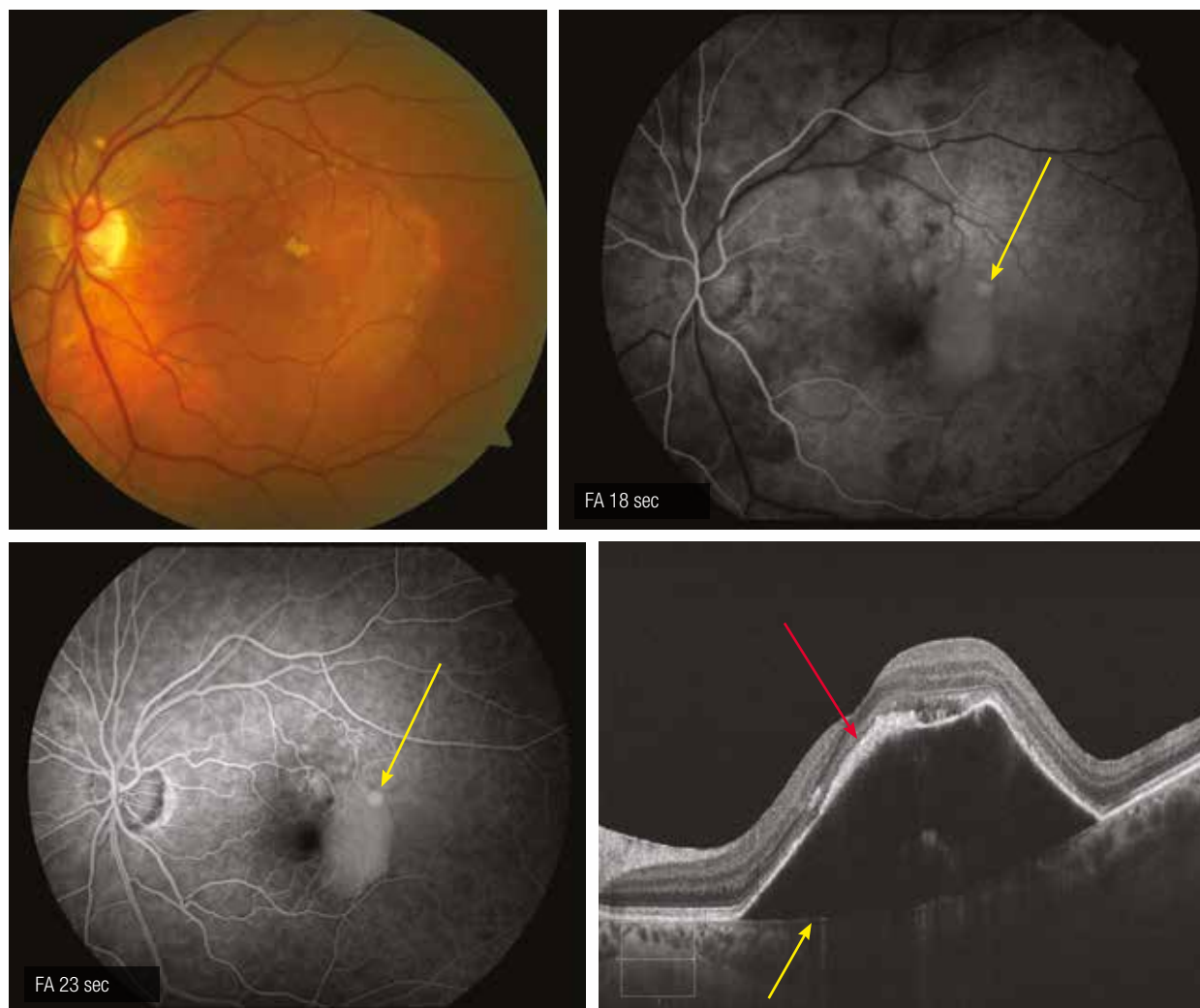
This is illustrated in the present case which also shows moderately hyperreflective elements within the hyporefective fluid. The margins are well defined and the neovascular membrane is fusiform in the retromacular area (red arrow). Bruch's membrane is visible as a thin hyperreflective line (yellow arrow).

Case 5 - Intraretinal fluid

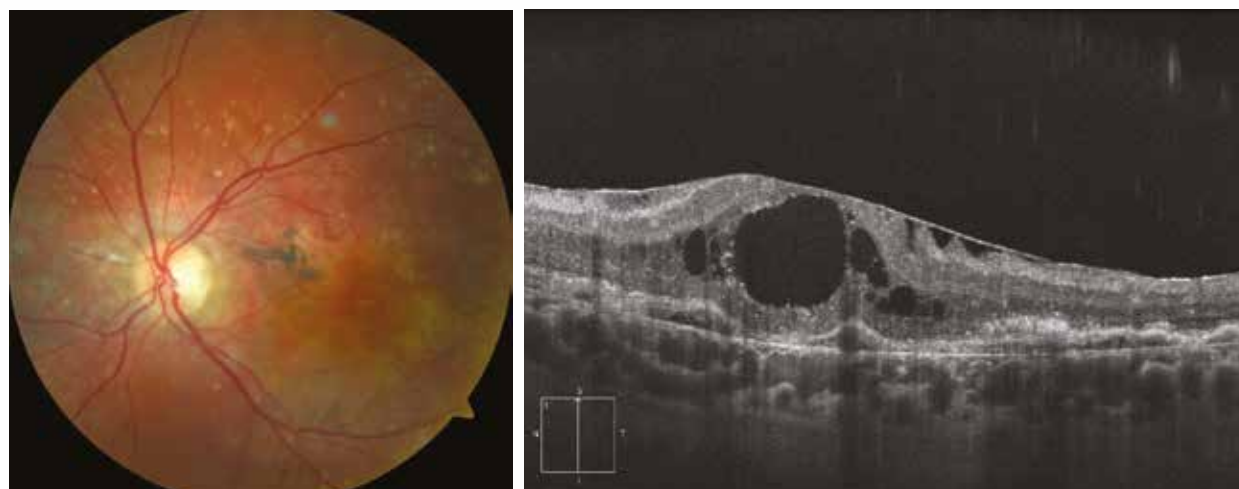
When there is a rupture of the external limiting membrane/photoreceptor complex, the exudation appears at the level of the neurosensory retina. This exudation is also promoted by the production of VEGF, which increases the retinal blood vessels permeability. At first, this exudation induces a thickening of the outer nuclear layer (which may be misinterpreted as a SRD), then intraretinal cysts are formed.

In this case of advanced AMD, the intraretinal cysts are large. The outer retina is completely disorganised and there are thin fibrovascular PEDs. Finally, anecdotally, an epiretinal membrane is seen on the macular surface.

Case 4



Cas 5



Neovascular AMD: cicatricial forms

Some lesions on OCT should be considered as cicatricial. The most frequent are intraretinal tubulations. These are round or oval hyporeflective cystic lesions surrounded by a hyperreflective layer. They are located in the outer nuclear layer, adjacent to a fibrous scar or just above an atrophic area. Tubulations are branched structures that could correspond to a photoreceptor rearrangement.

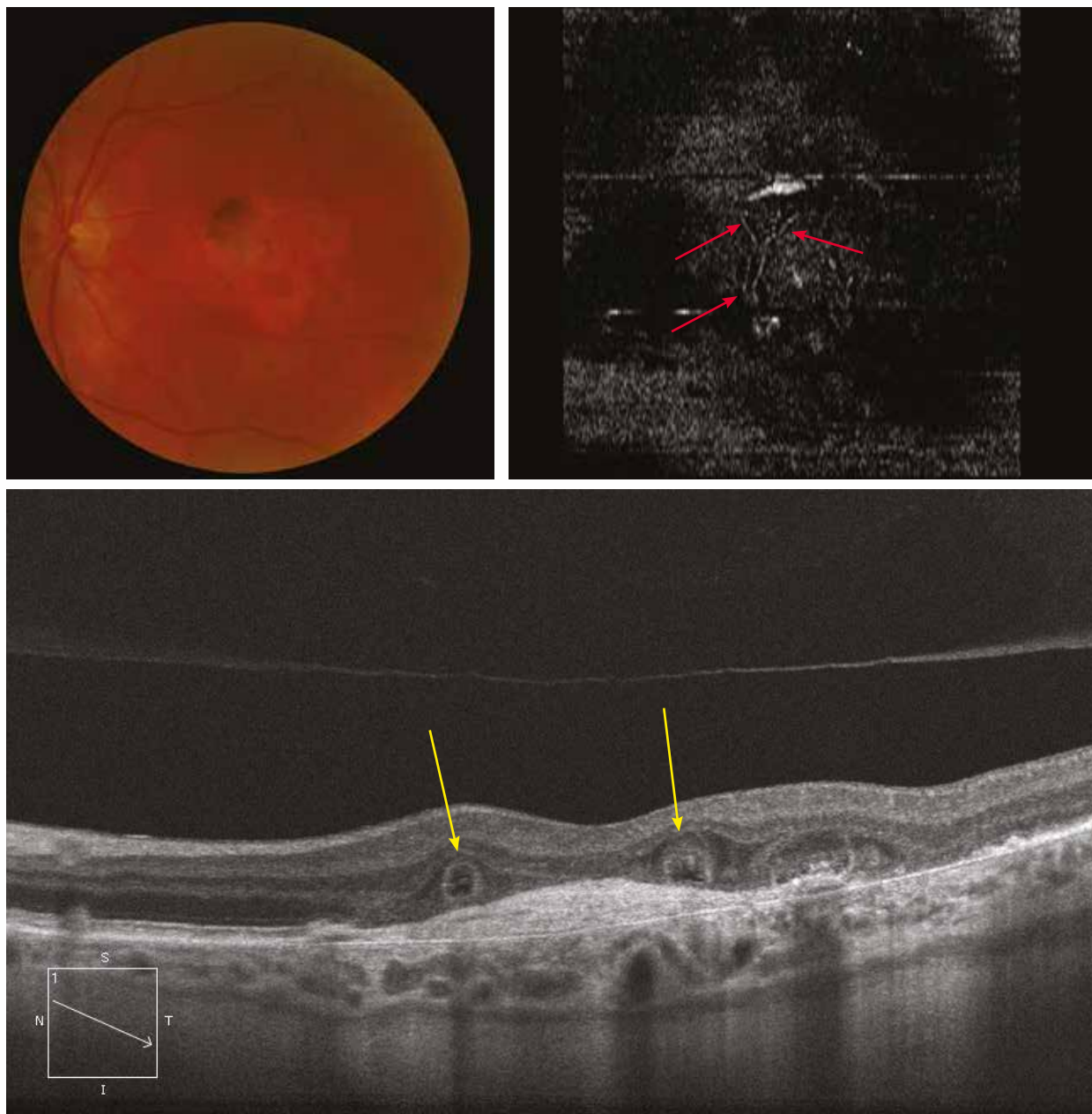
Other lesions are more difficult to distinguish from a genuine persistence of neovascular activity. These are the intraretinal cysts that persist despite the absence of any diffusion during angiography. They are classified as “cystoid macular degeneration”. They are more easily identifiable when they present squared margins. They are located in the inner retina.

These lesions are not visible either by fundus examination or angiography. They should not require any treatment.

Case 1 - Tubulations

The colour image shows macular atrophy associated with a range of pigmentation on the superonasal margin. The OCT also reveals a fibrous scar, the scarring stage of an exudative AMD. The oblique OCT section through the scar shows 2 typical tubulations within the outer nuclear layer (yellow arrows). Using the advanced Macular Cube Analysis (Advanced Visualization) and the RPE-fit display, an “en-face” image of the pigment epithelium is obtained. By moving the section to the level of the outer nuclear layer, these tubulations appear as ramified, taking a Y-shape in this case (red arrows). Hence, the 2 tubulations observed on the OCT section correspond to the 2 branches of the Y seen on the en-face OCT.

Case 1



Case 2 - Cysts and tubulations

In this case of cicatricial AMD with fibrous scarring at fundus examination, there is coexistence of a tubulation (yellow arrow) and intraretinal cysts with squared margins (red arrows), the latter corresponding to cystoid macular degeneration.

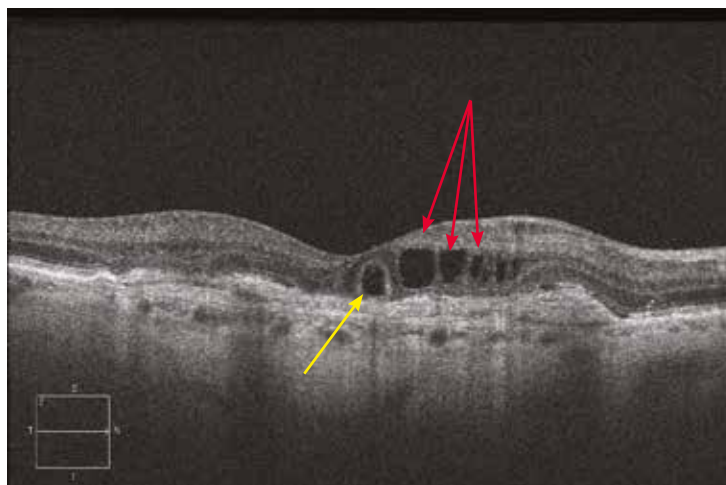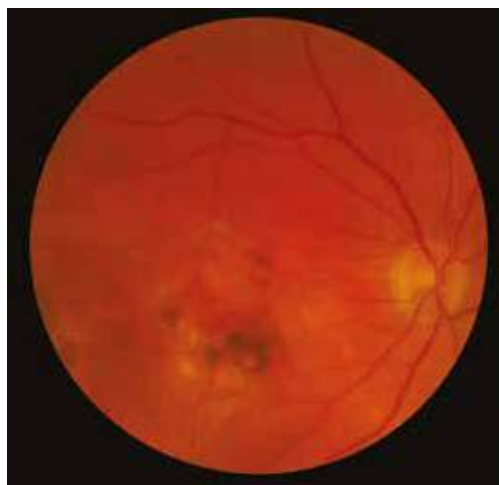Case 3 - Cysts

Cysts present within the inner retina, stable from one to another examination over several months, and located above a fibrous scar are part of a cystoid macular degeneration.

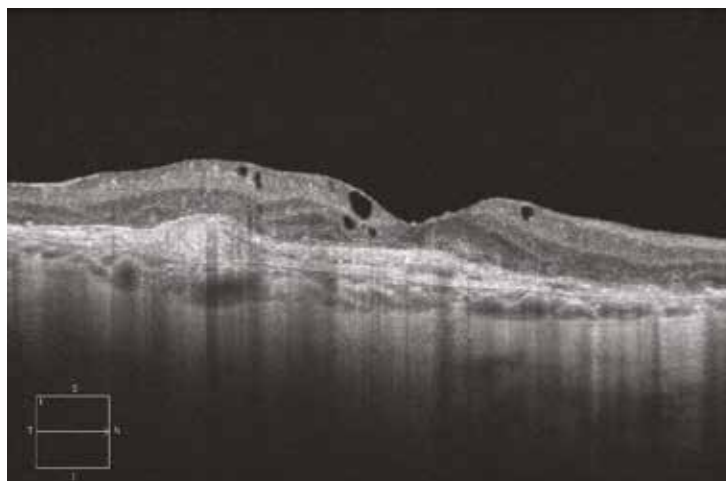
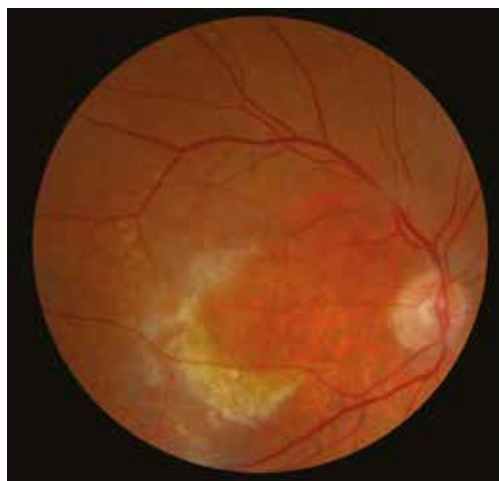Case 4 - Cysts

The presence of a pigmented scar on the colour image is characteristic of a pre-epithelial neovascularisation scar. On the OCT section, the scar is clearly visible, with an adjacent isolated cicatricial cyst within the inner retina.

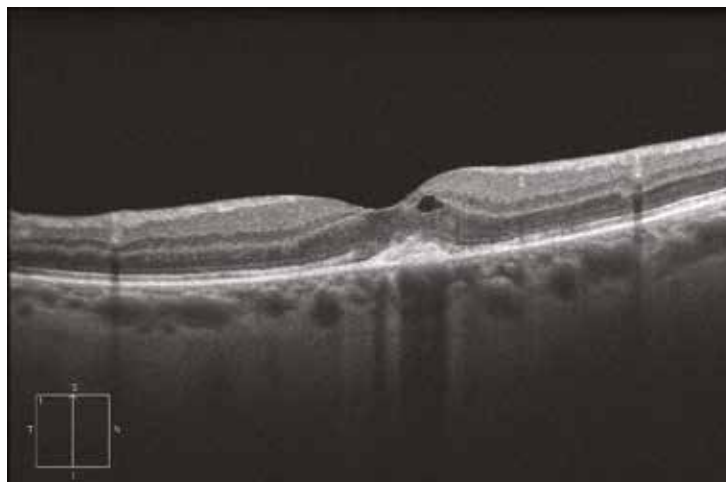
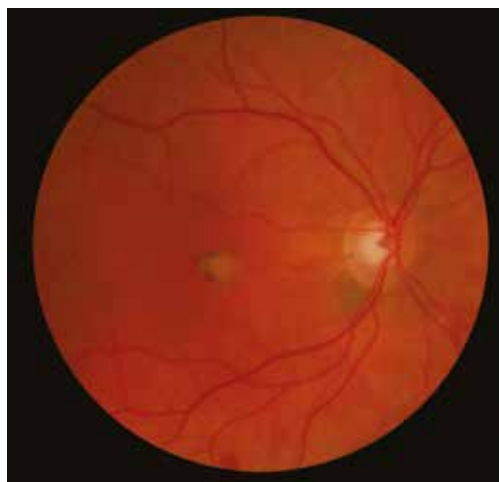Case 2



Case 3



Case 4

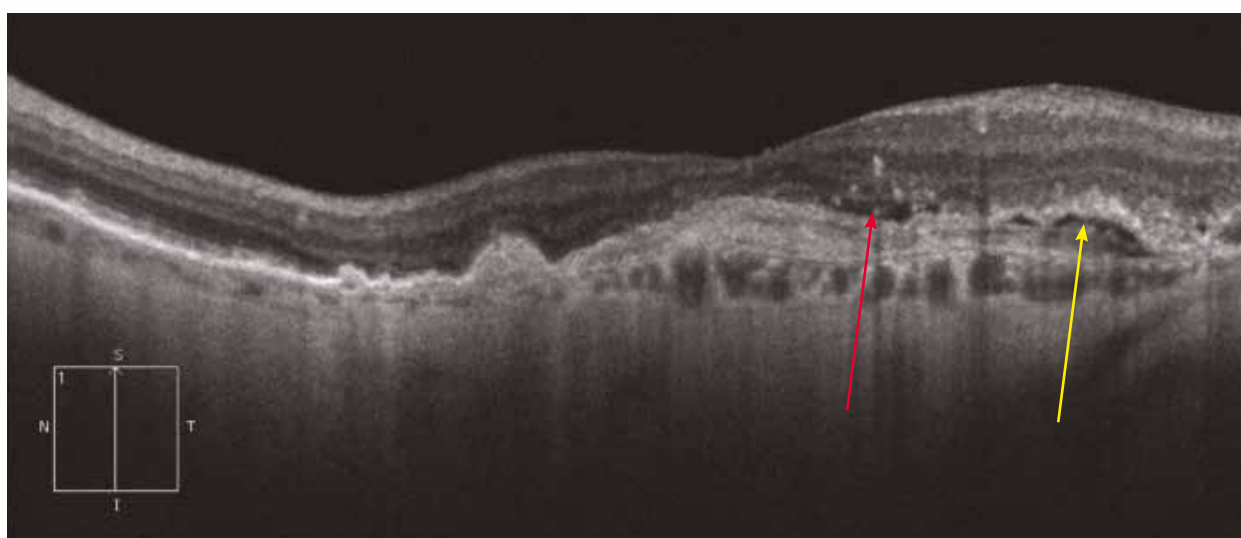
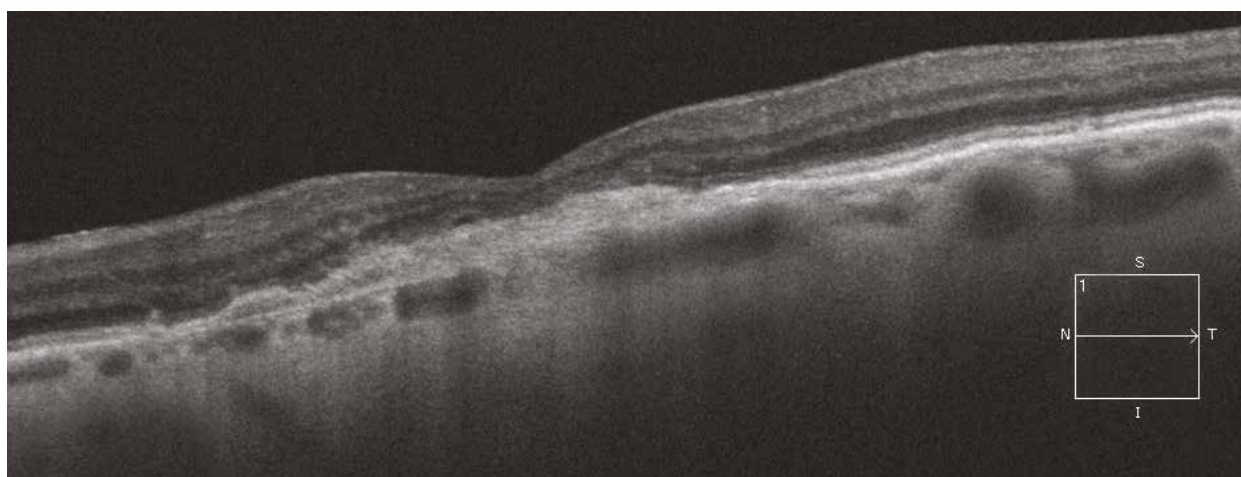
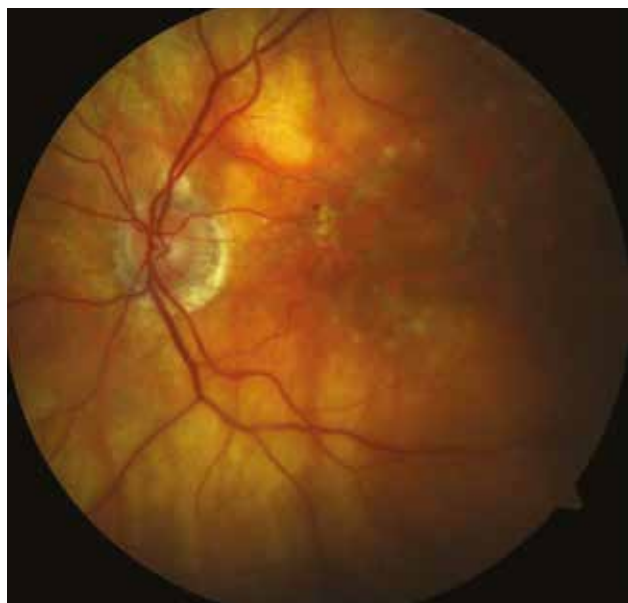

Case 5 - Recurrence

Follow-up of a patient with exudative AMD.

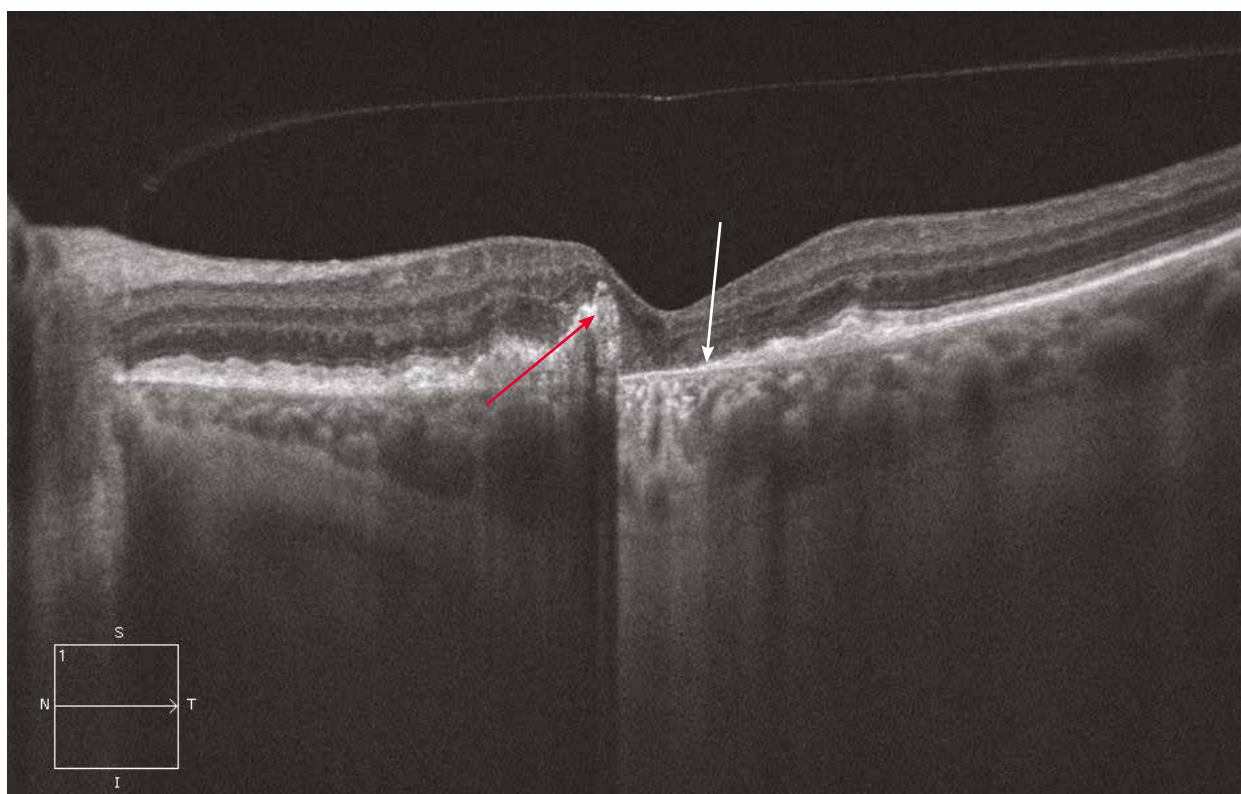
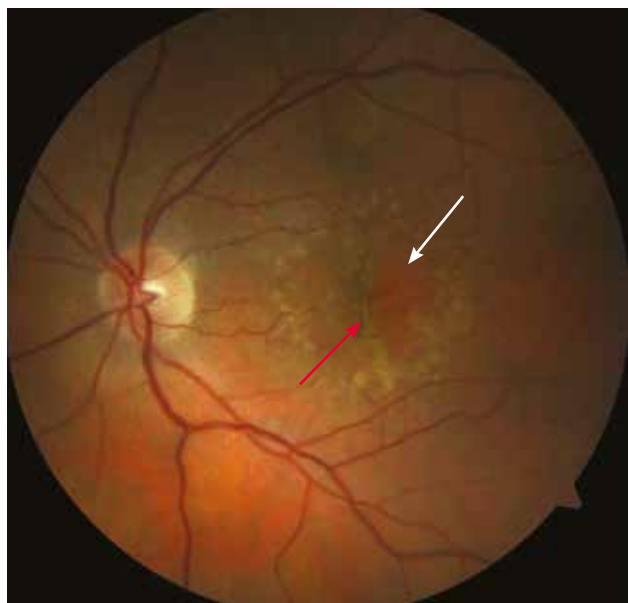
The macula is greatly altered and there are a small punctate haemorrhage and exudates. The horizontal OCT section is reassuring, with an uncomplicated fibrous scar. The vertical section shows signs of neovascular recurrence with the presence of subretinal fluid (yellow arrow) leading to the formation of 2 small PEDs (red arrow). The small hyperreflectivities within the inner retina correspond to the exudates.

Case 5



Retinal pigment epithelial tear

Tearing of the RPE is a complication of exudative AMD. On the colour image, the subretinal tissue is made visible at the tear site (white arrow) and the rolled-up RPE is found at the margin (red arrow). On the OCT, the tear is shown as an area where the choroid is very easily visible (white arrow), due to the RPE disappearance, and an area where the RPE is rolled up at the tear margin (red arrow).



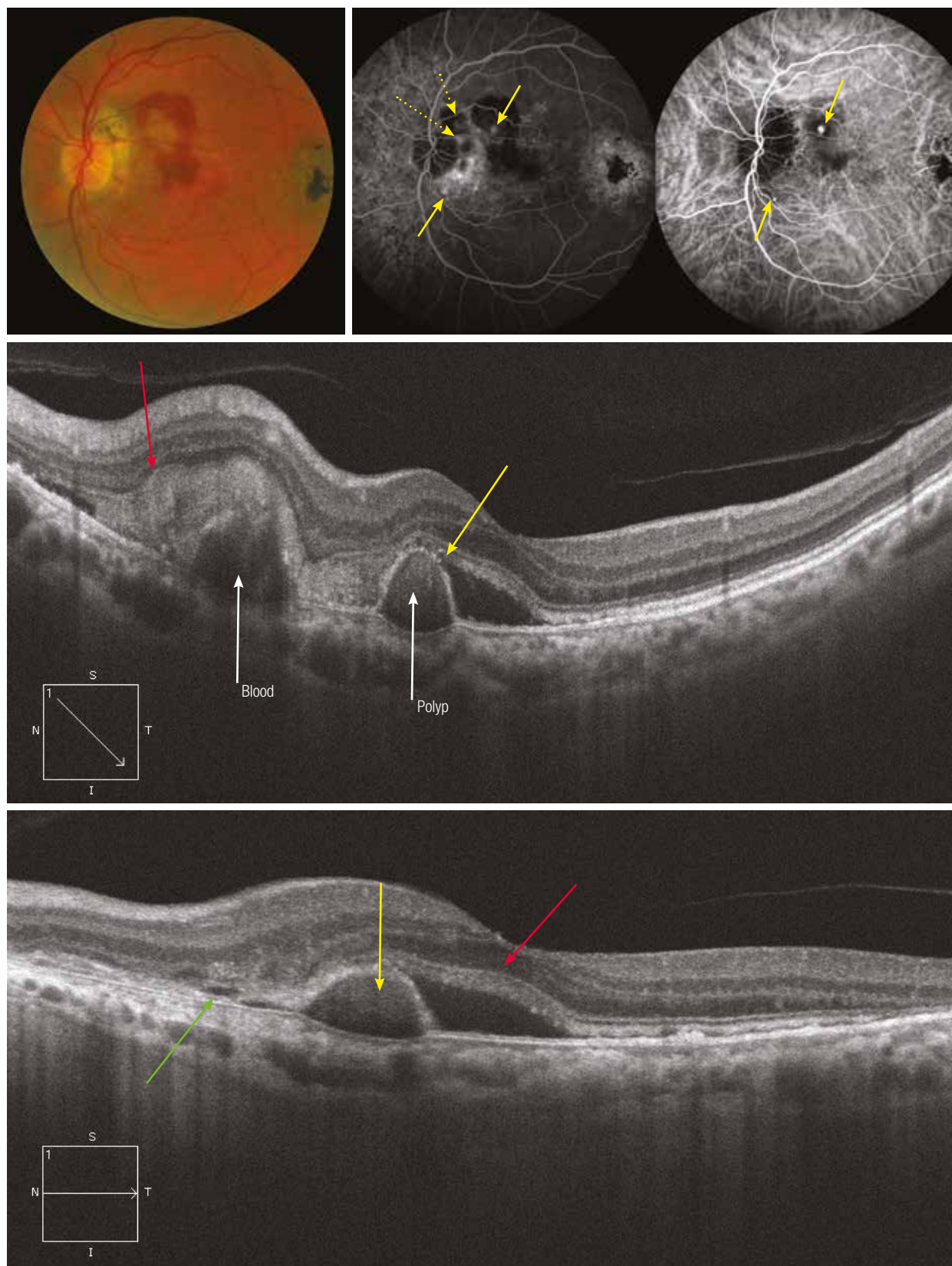
Polypoidal vasculopathy

Polypoidal vasculopathy is a retinal disease resulting from abnormal vascular proliferation originating from the choroid. Fundus examination discloses characteristic small orange-red lesions and an often severe serohaemorrhagic exudation. The ICG angiography, along with OCT, remains the key examination. Besides the changes in the choroidal vasculature observed during the early phases, a rounded hyperfluorescence corresponding to the polyp (yellow arrow) is visible at intermediate phases.

On the colour image, there is overall a subretinal haemorrhage, surrounding three poorly-distinguishable small red masses. On the fluorescein angiography and on ICG images, there are two hyperfluorescent spots corresponding to the polyps (yellow arrows). It should be noted that some are visible with the fluorescein but hidden by the blood with the ICG (dashed yellow arrows).

On the oblique OCT section through a polyp, there is a serohaemorrhagic PED of variable extent (here, it is large [red arrow]) in contact with a less voluminous PED at the external surface of which is attached an area of intermediate reflectivity corresponding to the polyp.

On a simple horizontal section through the macula, there is a smaller serohaemorrhagic PED visible because of much less blood at this level (red arrow), a SRD (green arrow) and a PED with a moderate hyperreflectivity at apex corresponding to a polyp (yellow arrow).



Chorioretinal anastomoses

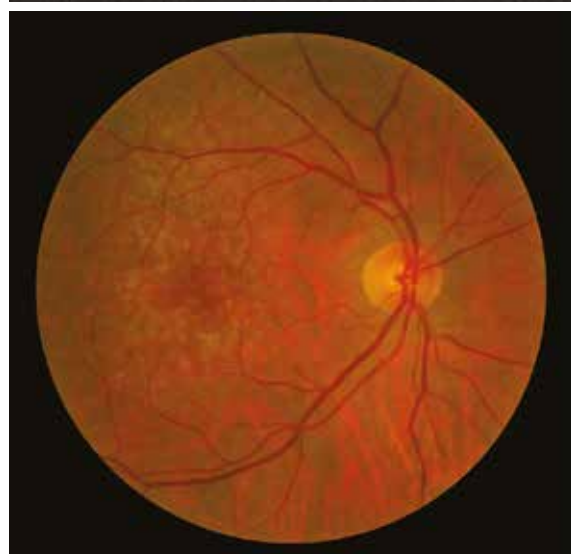
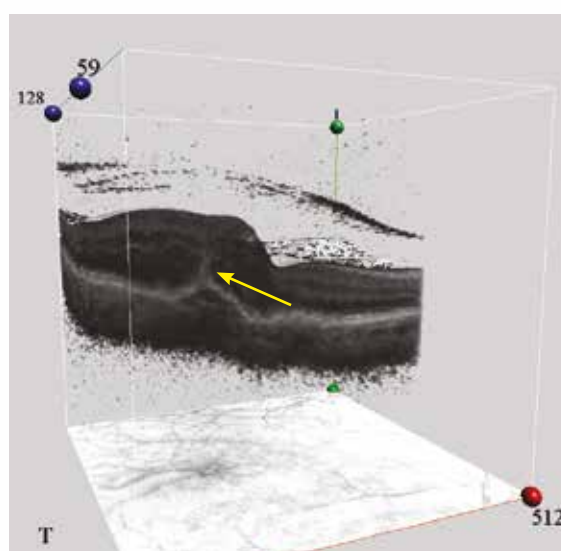
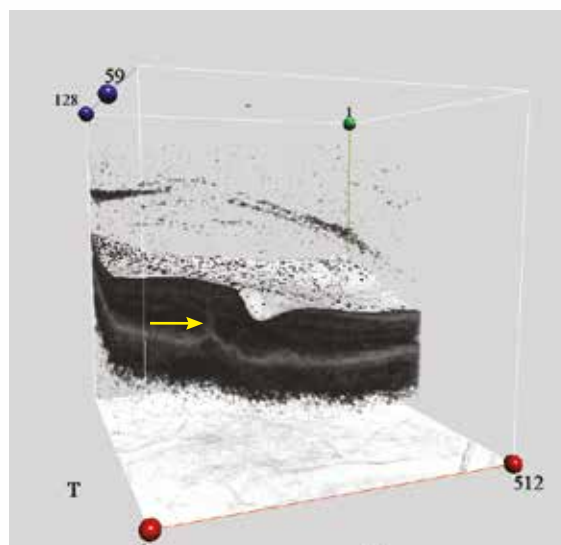
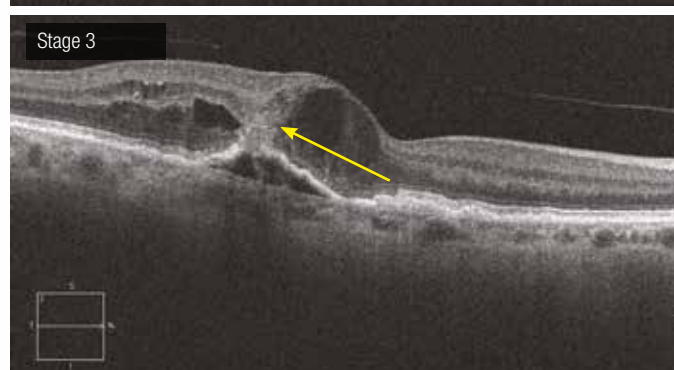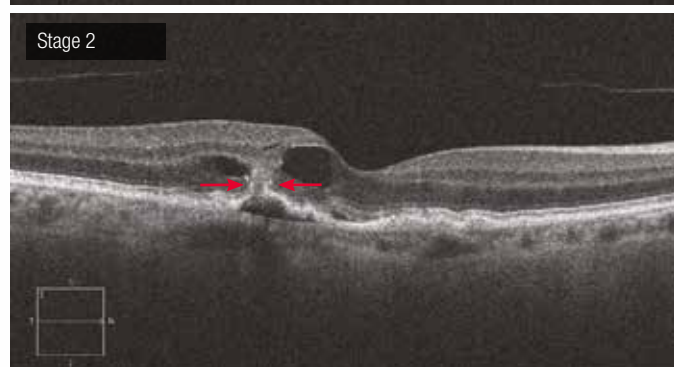
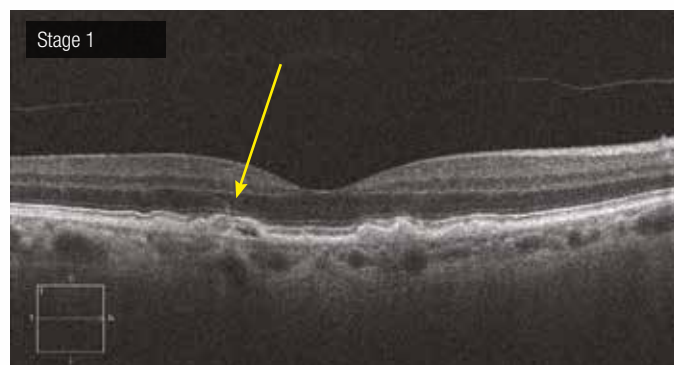Chorioretinal anastomoses are defined as abnormal connections between the retinal vascular network and the choroidal vasculature. They are isolated or, more frequently, associated with occult neovascularisation. Their pathogenesis is still debated. They are further complicated by haemorrhages and exudative signs (PED, SRD or cystoid macular oedema) and are very often associated with serous drusen. Angiography reveals a dye leakage with a hot spot. OCT greatly takes part to the diagnosis.

At the early stage, there is only a slight erosion of the pigment epithelium, which appears elevated. At the apex of the elevation, there is a hyperreflective ribbon in the outer nuclear layer. In addition, the typical deformations of the RPE associated with serous drusen are found.

Stage 2 is characterised by signs of exudation (in this case, two intraretinal cysts and a small SRD). At the anastomosis site, there is RPE tear and a “double-flap” structure (red arrows). The lesion is hyperreflective. On the 3D image, a retinal thickening adjacent to the anastomosis is found.

At the advanced stage, a double-tunnel structure is shown: one extending from the PED apex through the neurosensory retina which joins the other extending from the internal limiting membrane. This “kissing sign” indicates the connexion between the inner and outer retina. This sign is also seen on the 3D image with the adjacent retinal thickening. At this stage, the exudation is increased.

Note that, on the colour image, only the serous drusen are visible. There are no haemorrhages or exudation.



6. Other degenerative macular disorders

6.1. Pseudovitelliform dystrophy

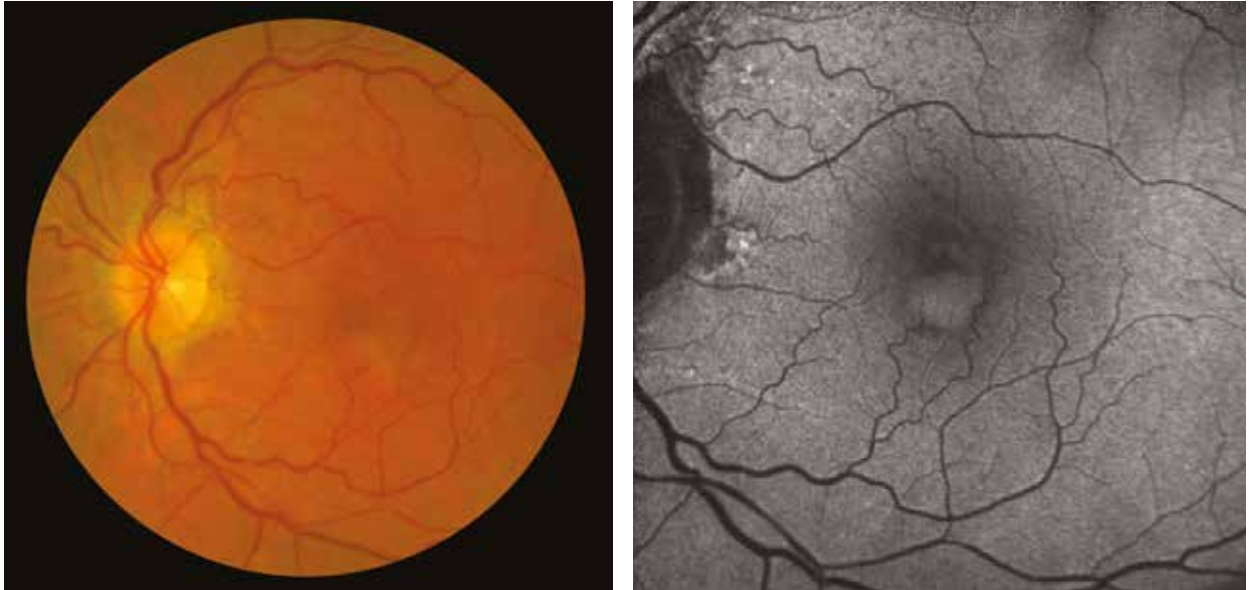
6.2. Angioid streaks

Pseudovitelliform macular dystrophy

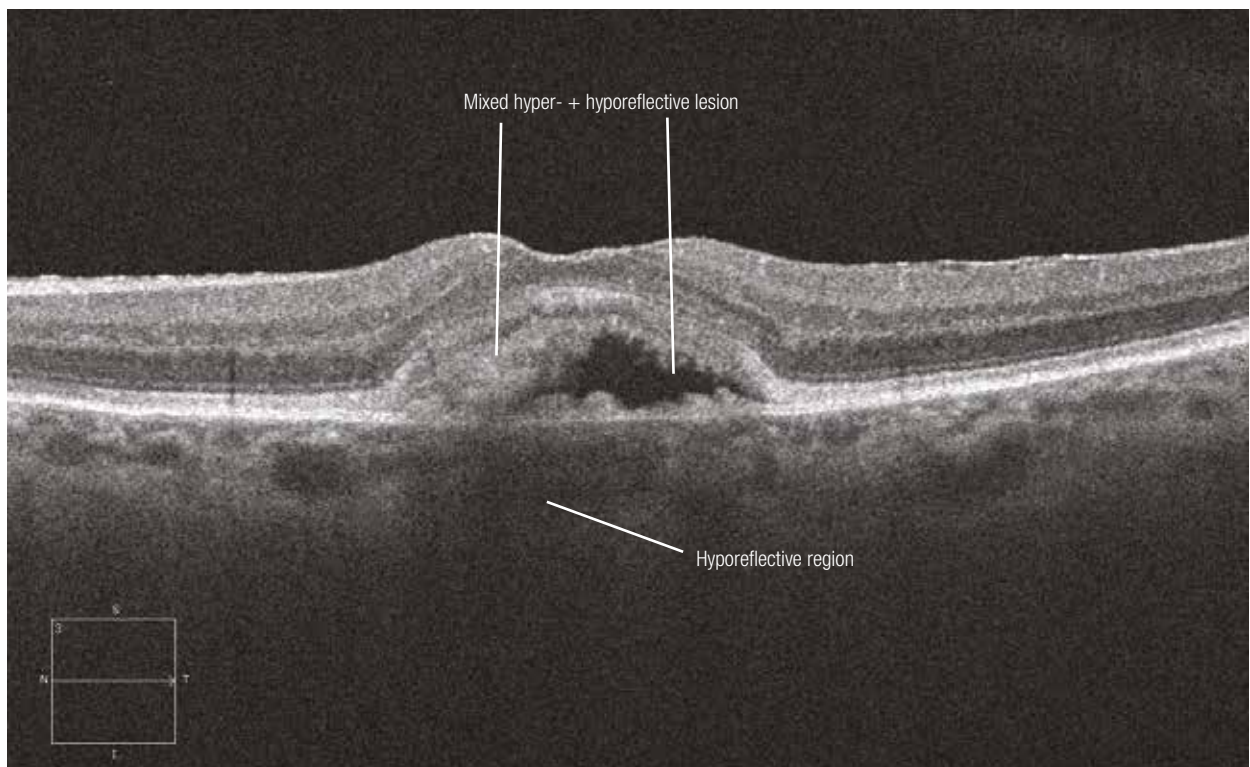
This condition is associated with the accumulation of yellowish material (like “egg yolk”) between the RPE and the neurosensory retina. Four stages are distinguished at fundus examination:

- 1) Presence of the vitelline material distributed evenly in the subretinal space, with or without central hyperpigmentation.
- 2) Pseudohypopyon (there is subretinal fluid in the upper part).
- 3) Material fragmentation, usually persisting around the margins of the lesion.
- 4) Atrophy.

On autofluorescence images, the material is obviously hyperautofluorescent and beneath the RPE, adjacent to the lesion, there is a hyporeflective region on OCT sections. The case presented here shows a pseudovitelliform dystrophy at the pseudohypopyon stage



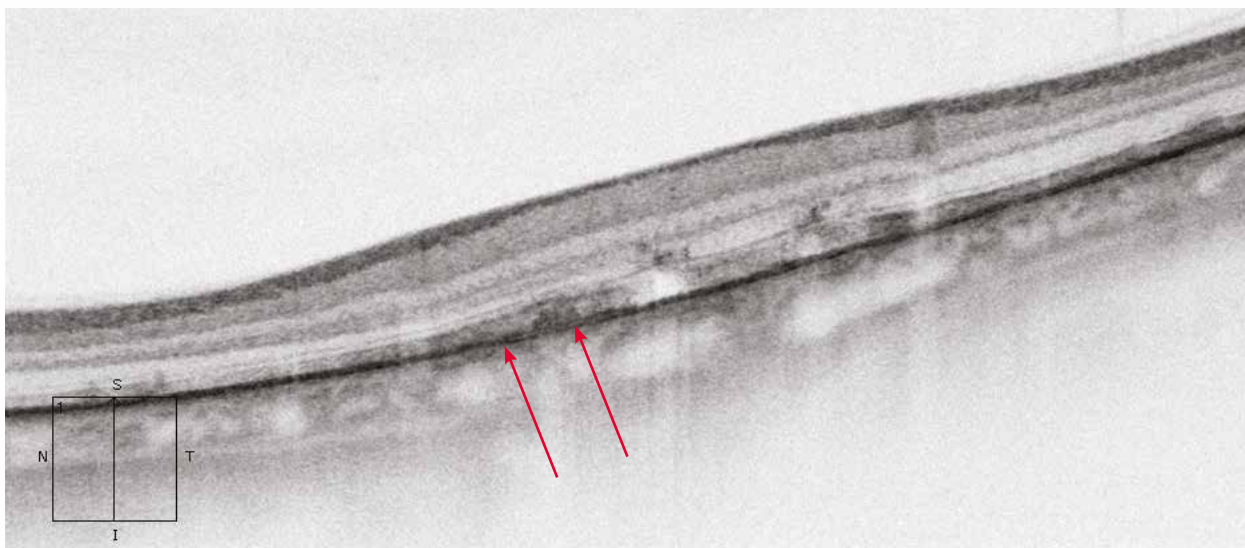
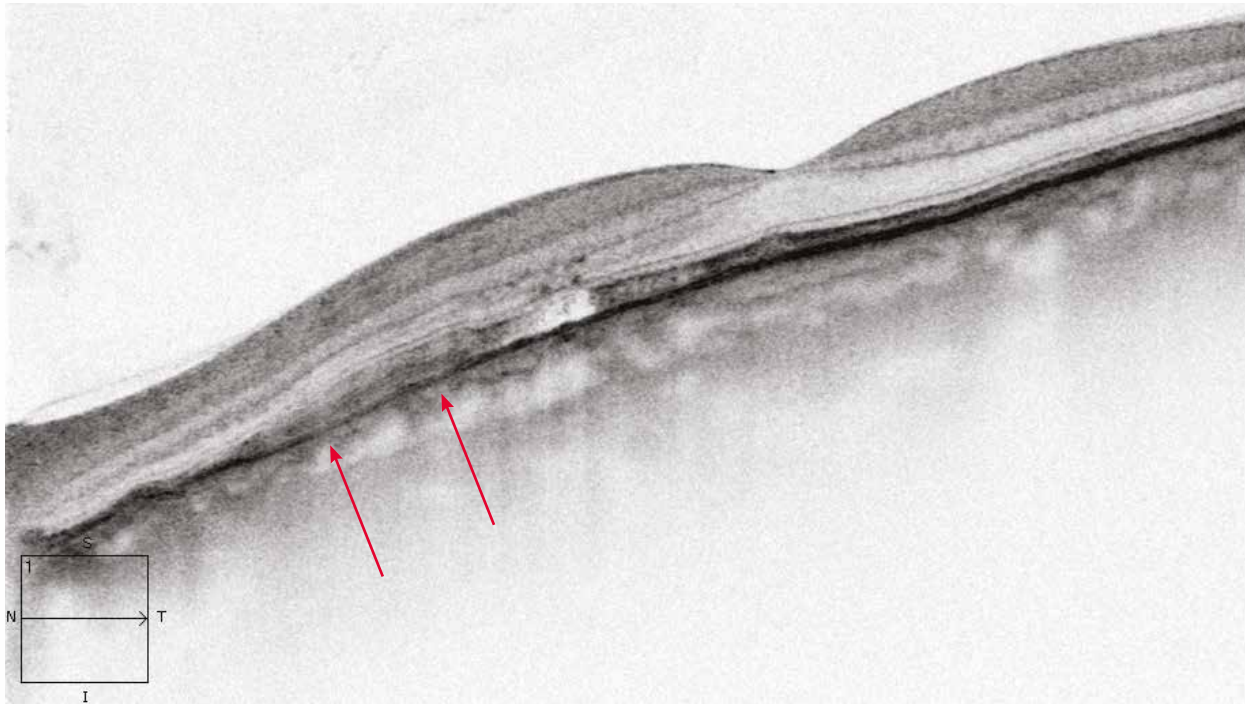
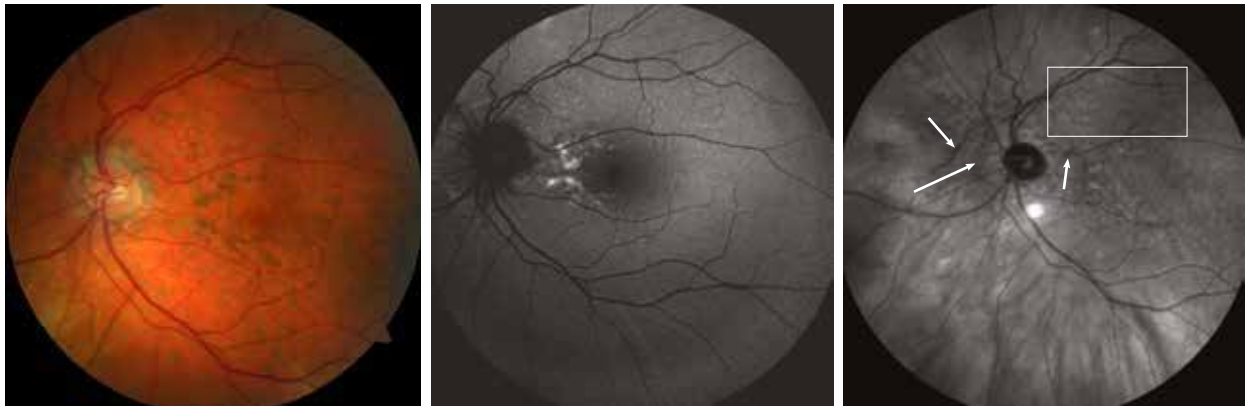Pseudovitelliform at the pseudohypopyon stage



Angioid streaks

They are often discrete on colour and autofluorescence images and become more obvious when RPE changes are associated. They are more clearly identified on infrared images (white arrows) with typical orange peel pattern when associated with pseudoxanthoma elasticum (rectangle).

On the OCT, the visibility of the tear of the Bruch's membrane depends on the width of the streaks (red arrows) and is more obvious using negative images.



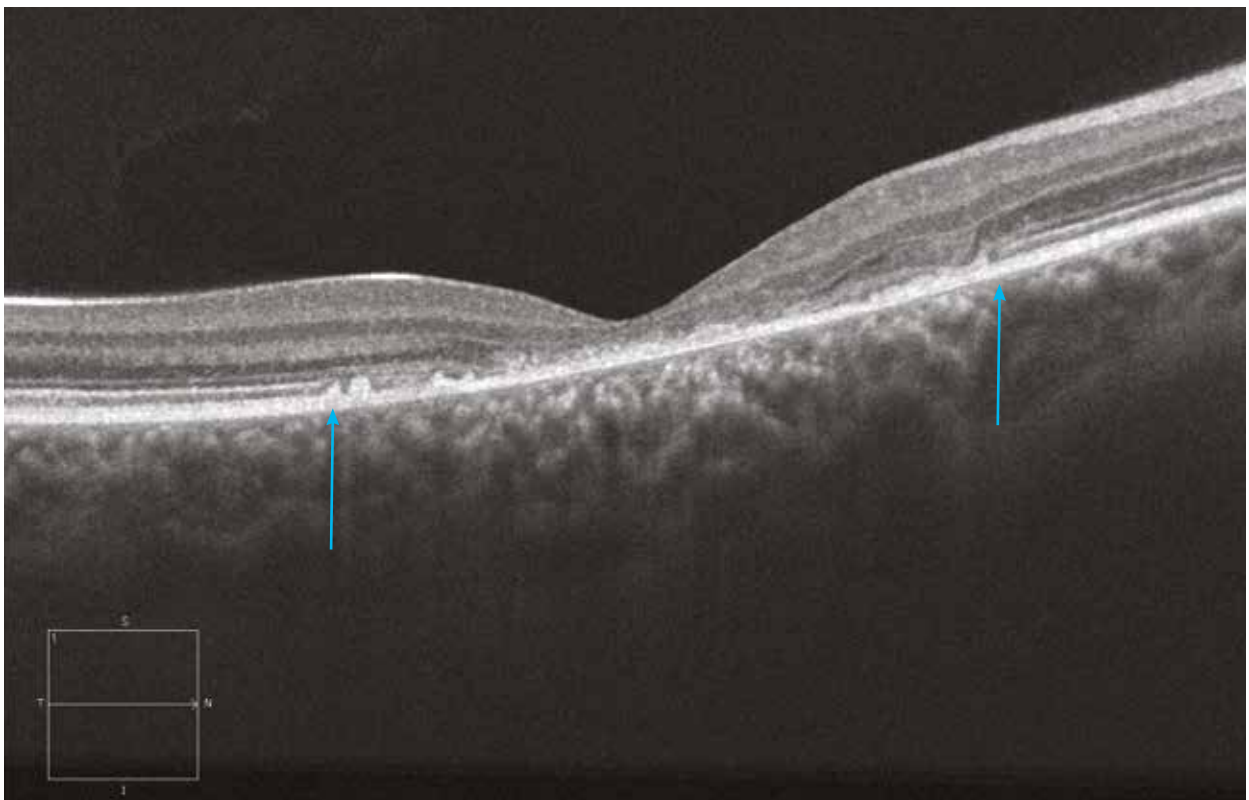
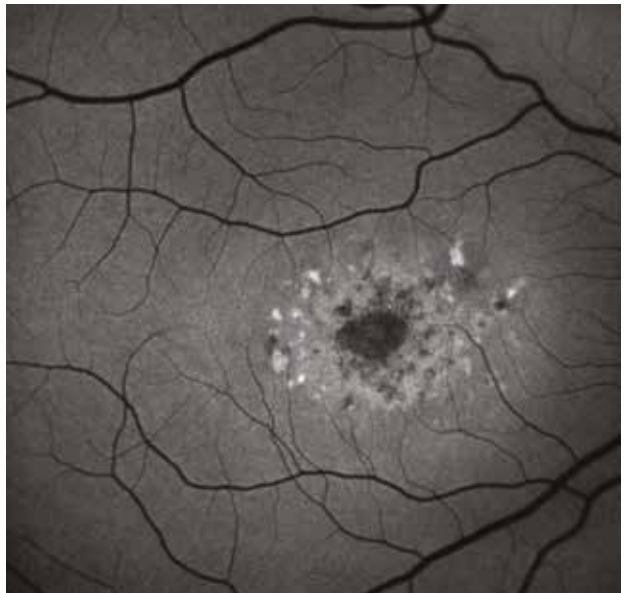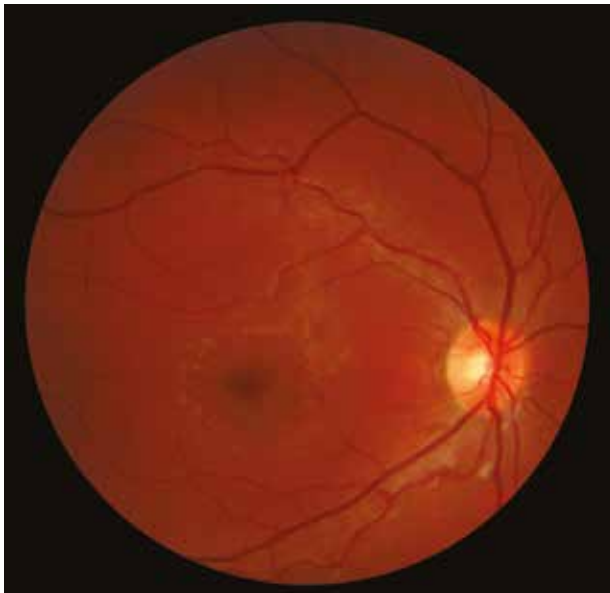7. Hereditary retinal dystrophies

- 7.1. Stargardt's maculopathy**
- 7.2. Retinitis pigmentosa**
- 7.3. Cone dystrophy**
- 7.4. Best's disease**
- 7.5. Central areolar choroidal sclerosis**
- 7.6. X-linked retinoschisis**

Stargardt's disease in an adolescent

On the colour image, there is a change in the macular reflection associated with perimacular yellowish dots.

The autofluorescence image shows small perimacular hypo- and hyperautofluorescent dots. The central macular atrophy (between the 2 arrows) is revealed by the OCT image, demonstrating the disappearance of the outer retina.

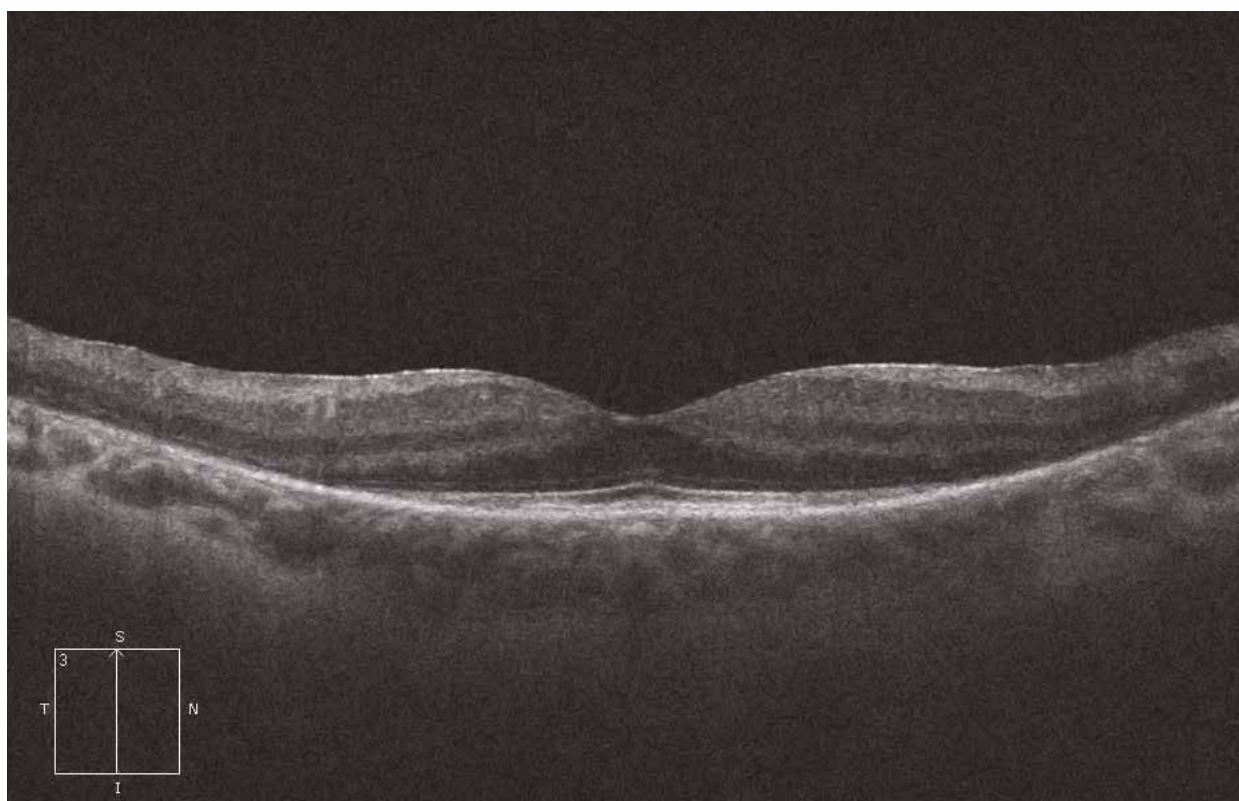
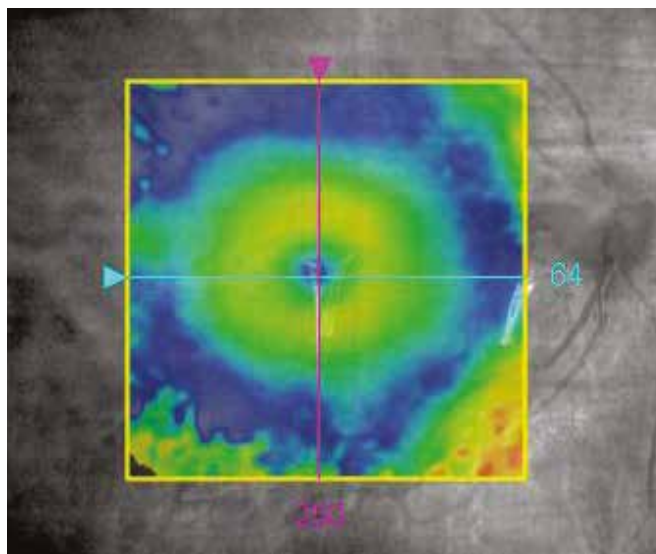
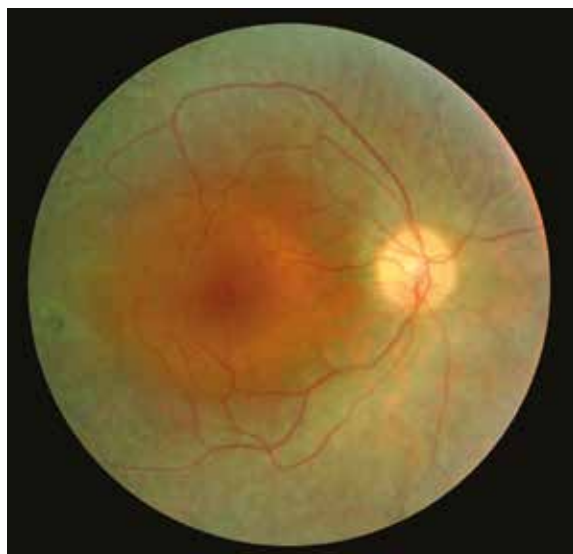

Retinitis pigmentosa

Case 1 - Classical case of rod-cone dystrophy

The colour image shows a greyish retinal atrophy extending from the perimacular region to beyond the vascular arcades, contrasting with the preserved appearance of the macular region. There are some peripheral pigment migrations producing an “osteoblast-like” appearance. The calibre of the arteries is slightly narrowed and the optic nerve appears “waxy”. The retinal mapping confirms the retinal atrophy beyond the central macular region. The OCT section shows an interruption of the outer nuclear layer from the perimacular region to the periphery, secondary to rod photoreceptor degeneration, with good preservation of the inner layers.

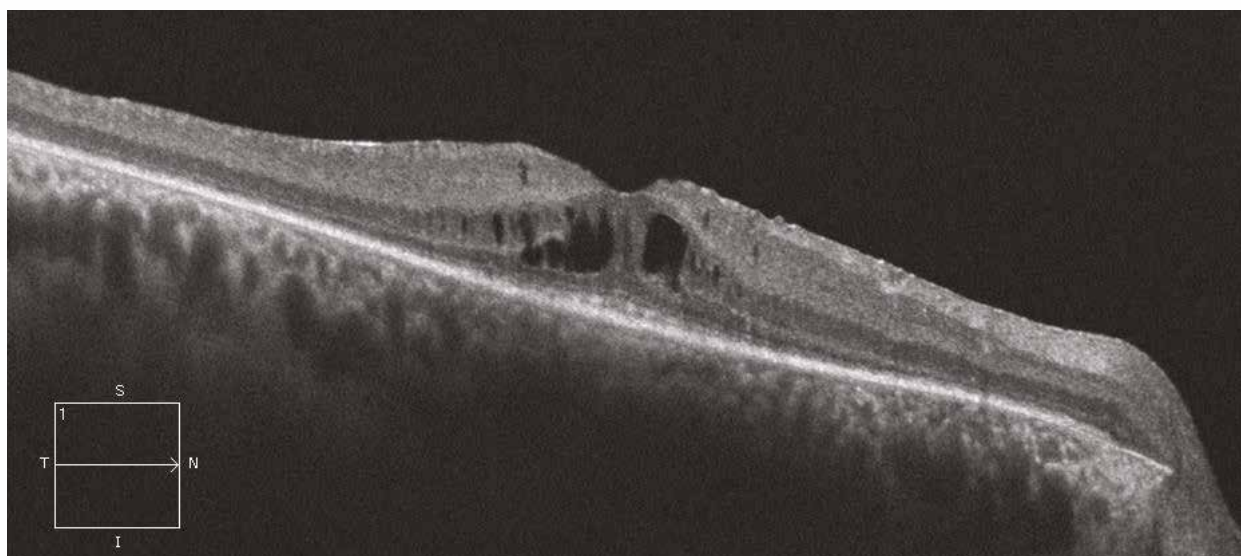
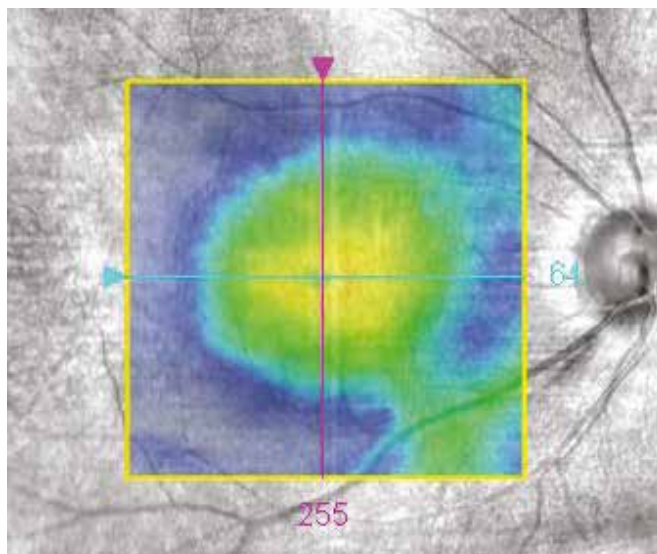
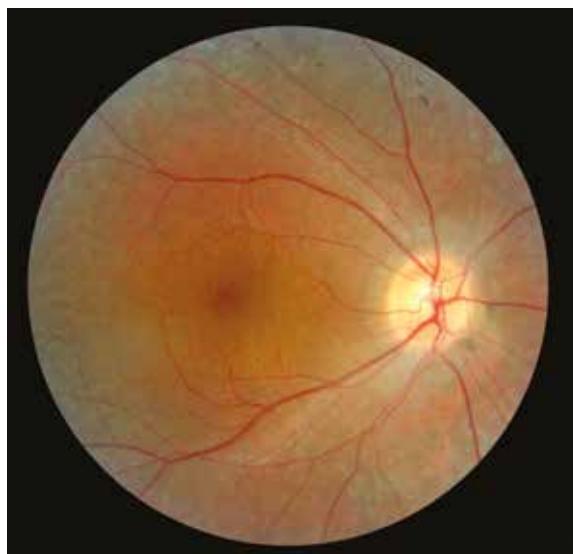Case 1



Case 2 - Retinitis pigmentosa associated with macular oedema

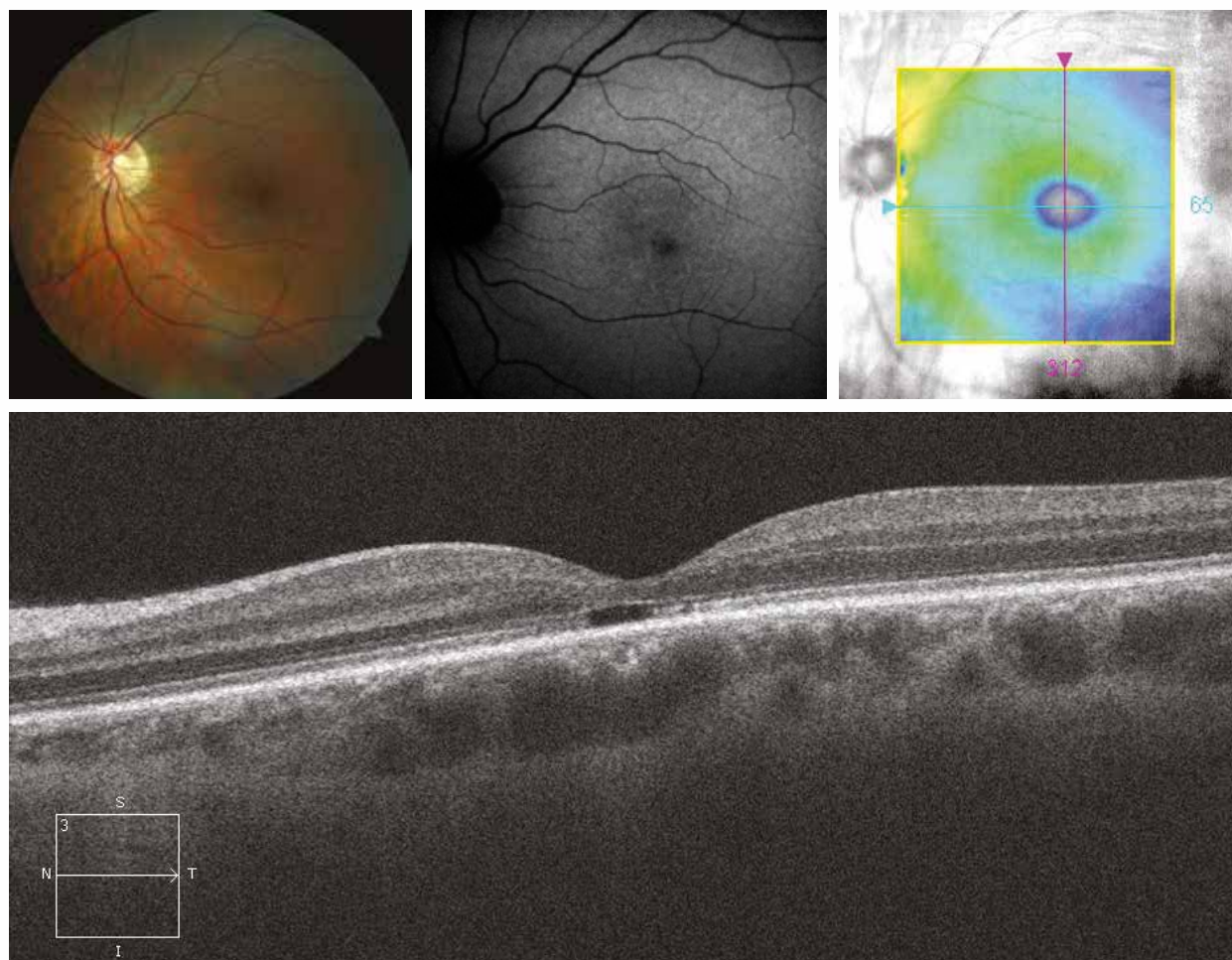
The appearance at fundus examination is quite close to the previous case, with peripheral atrophy, pigment migrations and narrowed arteries. The retinal mapping shows the atrophy in the perimacular region. On the OCT section, in addition to the outer nuclear layer interruption in the perimacular region, there are foveal cystic cavities. The occurrence of this type of macular oedema is quite common in patients with retinitis pigmentosa, although its pathogenesis is poorly understood.

Case 2



Cone dystrophy

On the colour image, there are discrete macular remodelings. On autofluorescence, there is a decrease in macular hypoautofluorescence. The macular mapping shows foveal thinning. On the OCT section, this thinning is associated with a focal interruption of the boundary line between the inner and outer segments of the photoreceptors. The ISCEV ERG confirms the diagnosis of cone dystrophy by showing a lack of response under photopic conditions while the scotopic response is preserved.



Best's disease

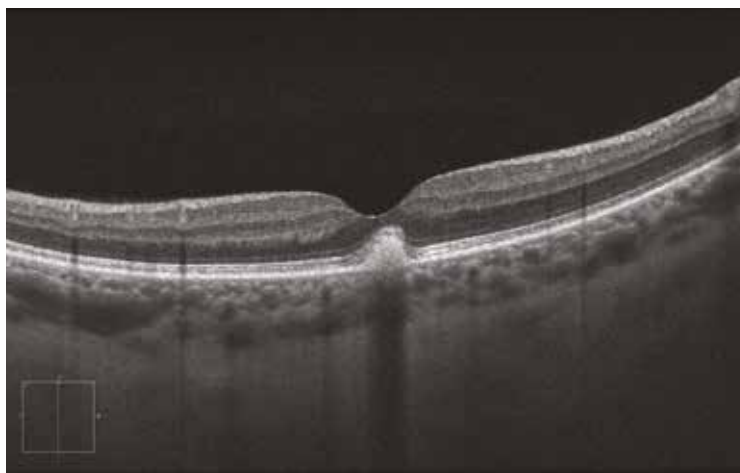
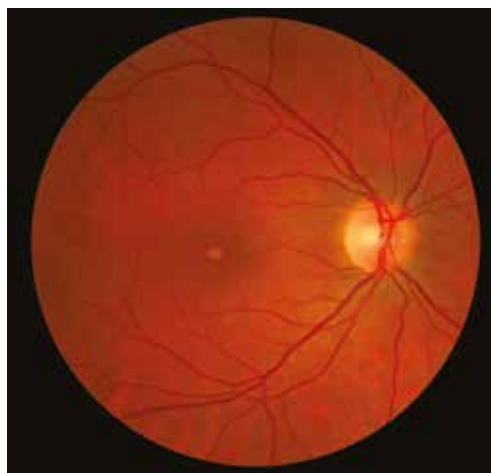Case 1 - Vitelliform stage

The colour image shows a yellowish rounded isolated macular lesion, in the present case of small size. This lesion is due to an accumulation of hyperreflective subretinal material. The adjacent retina is surelevated by the material but does not present any abnormalities.

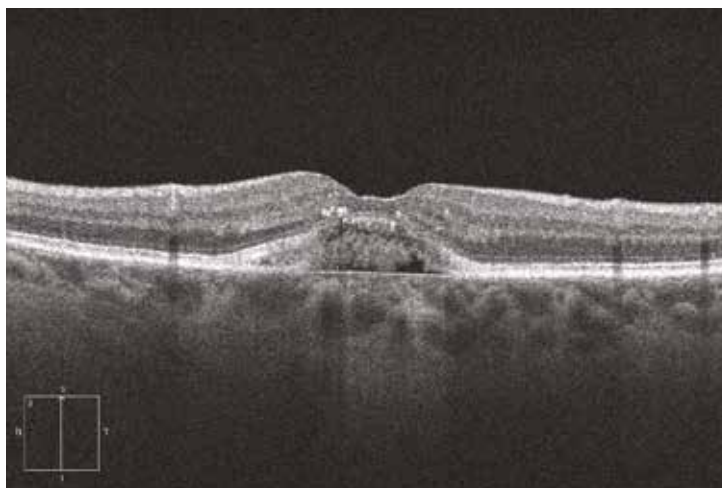
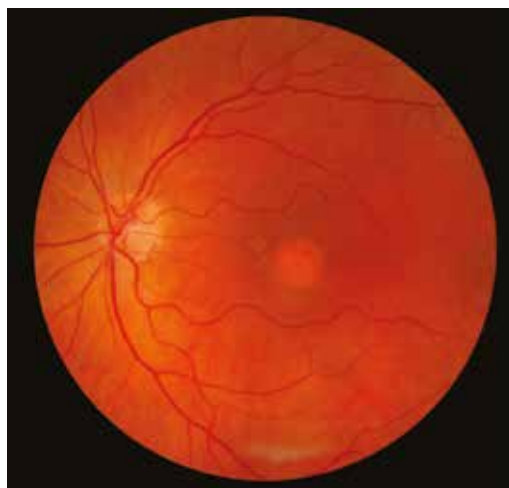Cases 2 and 3 - Fragmentation stage

The centromacular yellowish lesion loses its regular appearance. On the OCT section, the deposit of subretinal material is no longer homogeneously hyperreflective; it seems to fragment as suggested by hyporefective areas.

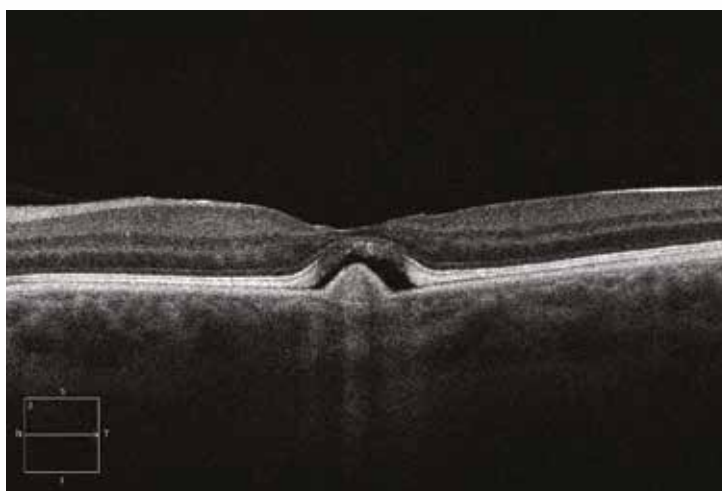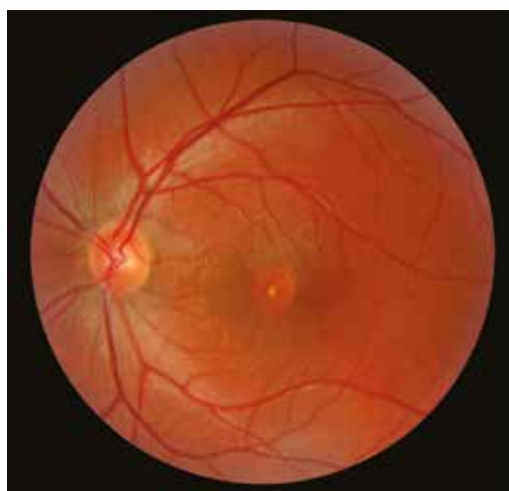Case 1



Case 2



Case 3

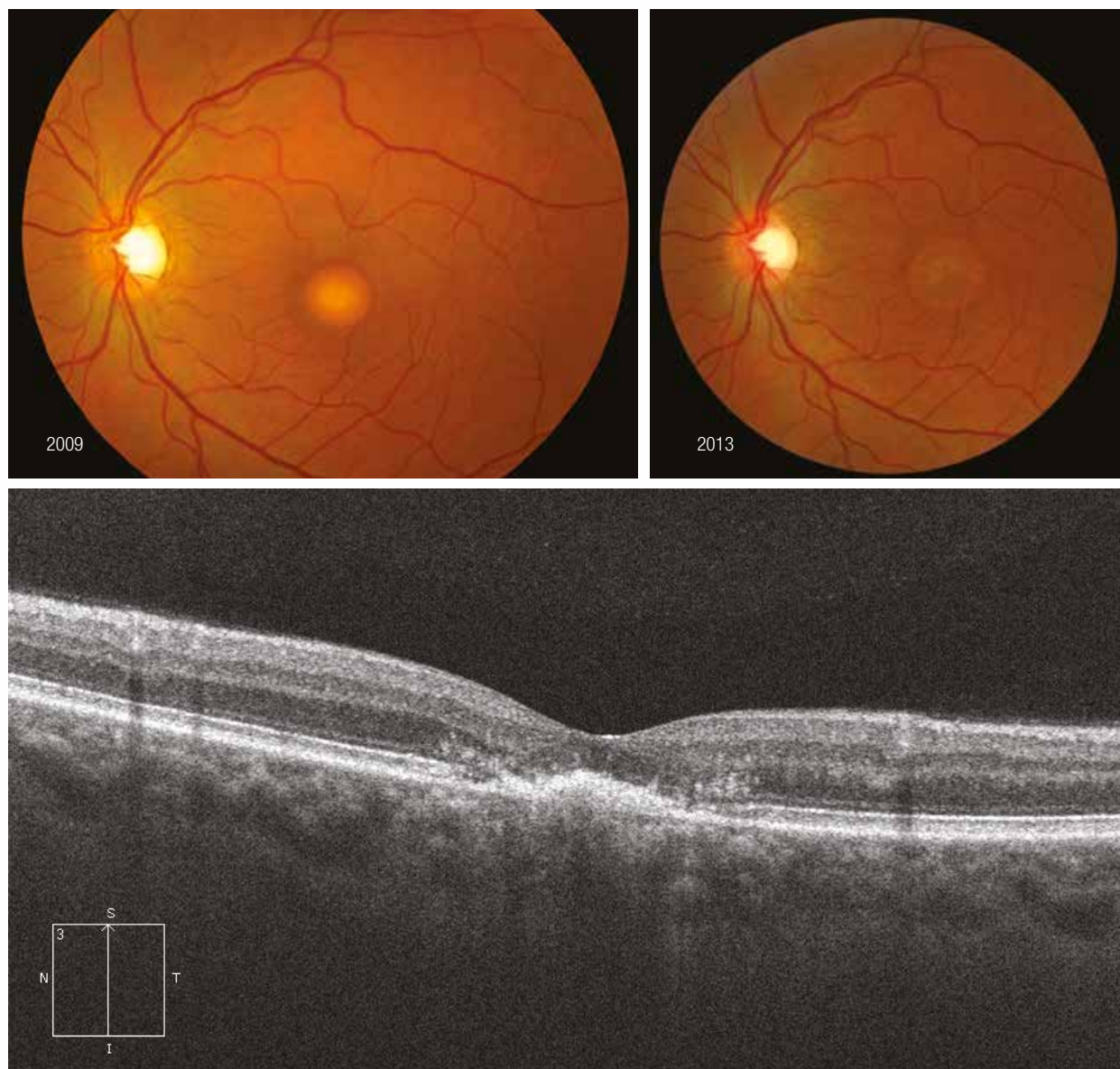


Case 4 - Atrophic stage

Ocular fundus of a female patient with a homogeneous vitelline disk in 2009 (upper left). The same patient seen in 2013 (upper right): an area of macular atrophy in place of the material is observed.

On the OCT section performed in 2013, there is a collapse of the subretinal material with disappearance of the photoreceptor outer segments.

Case 4



Case 5 - Neovascular complication

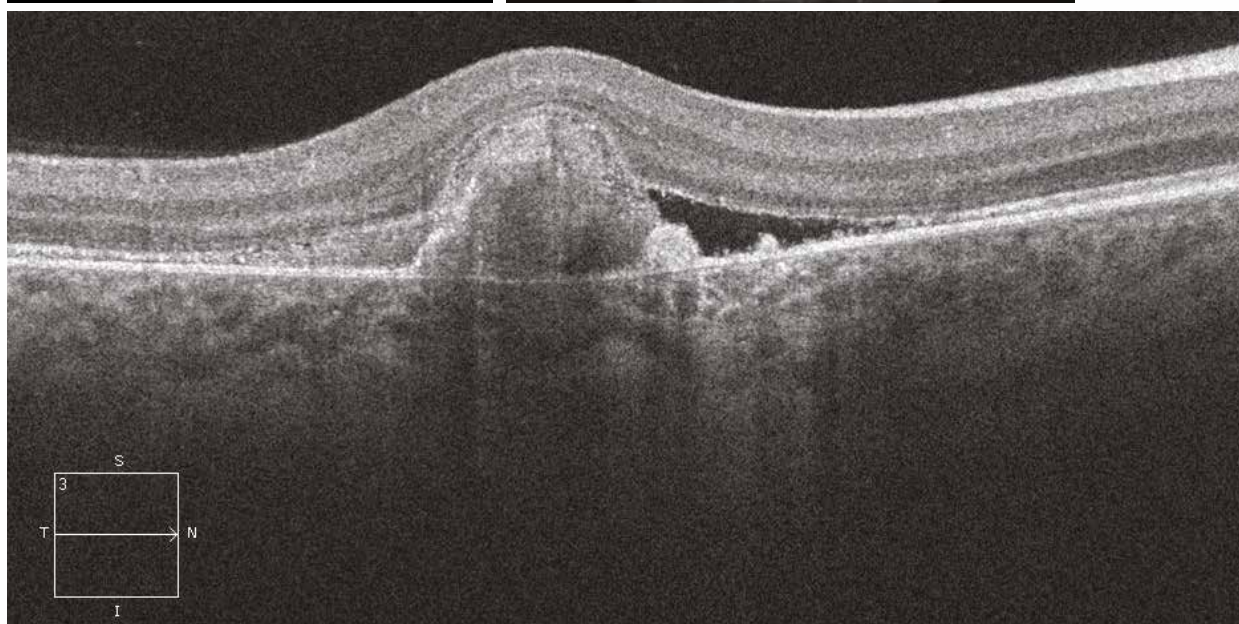
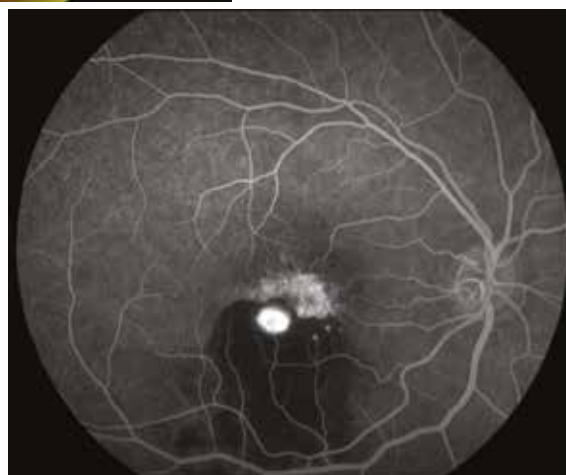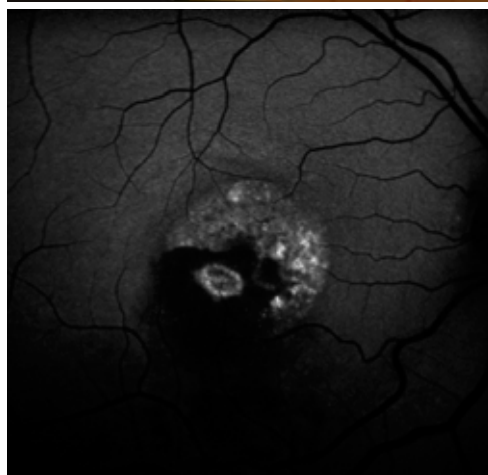
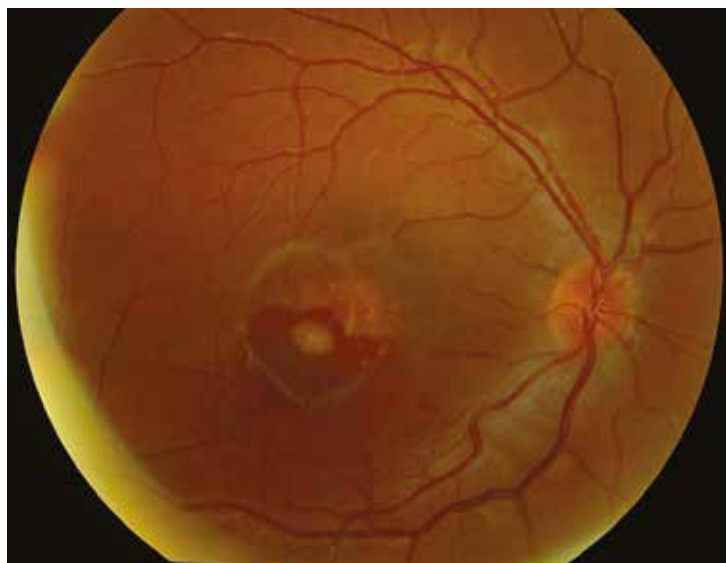
Formation of a choroidal neovessel with haemorrhage.

On autofluorescence, there are residues of fragmented hyperautofluorescent material as well as hypoautofluorescent areas corresponding to atrophy. In the lower temporal region, the haemorrhage causes a masking effect of the underlying autofluorescence.

On the early angiography image, at the centre of the haemorrhage, the neovessel is filled with fluorescein.

On the OCT image, there is a neovascular detachment of the retinal pigment epithelium with heterogeneous content associated with serous exudative retinal detachment.

Case 5

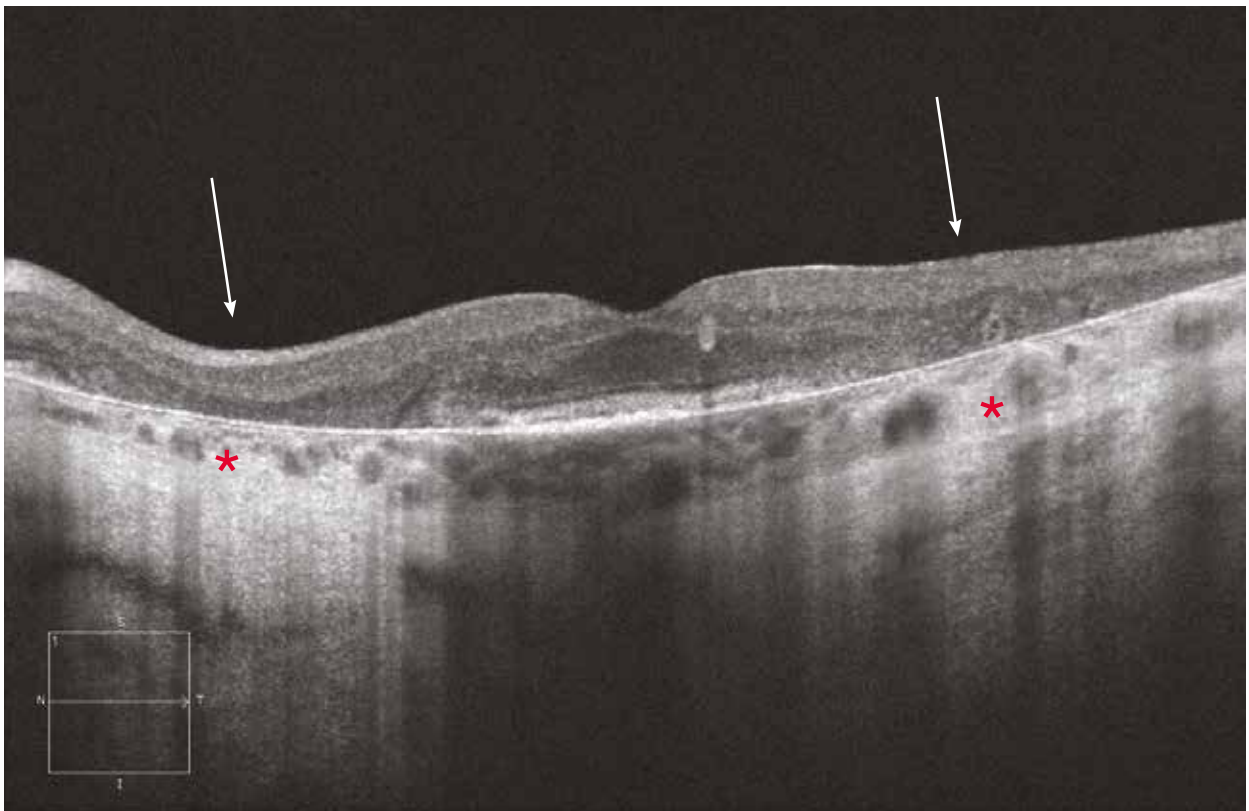
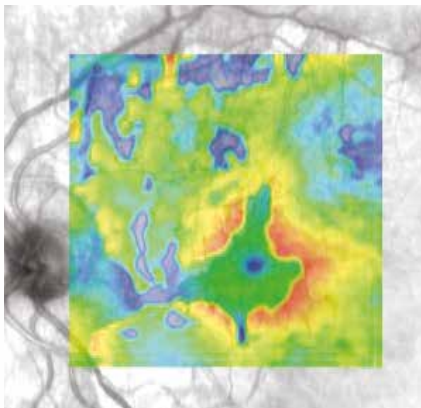
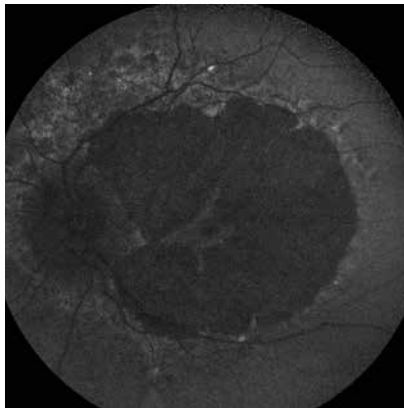
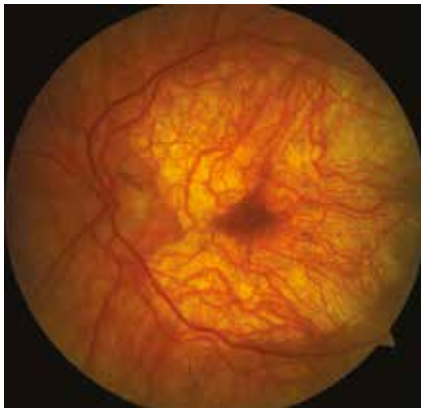

Central areolar choroidal sclerosis

A 45-year-old patient with preserved visual acuity but presenting with pericentral scotoma.

The fundus examination shows an area of perimacular chorioretinal atrophy with foveal sparing (rosette-like appearance), close to the aspect of the geographic atrophy in older patients with atrophic AMD.

On autofluorescence, the area of pigment epithelium atrophy is hypoautofluorescent. The retinal mapping confirms the retinal atrophy beyond the central macular region. On “en face” OCT, findings are similar to the fundus examination, with sparing of the centrofoveal tissue. The OCT section shows the atrophy of the outer retina and of the pigment epithelium in the centrofoveal region (arrows). Adjacent to the atrophy, the choroid is hyperreflective due to the pigment epithelium disappearance (asterisks).



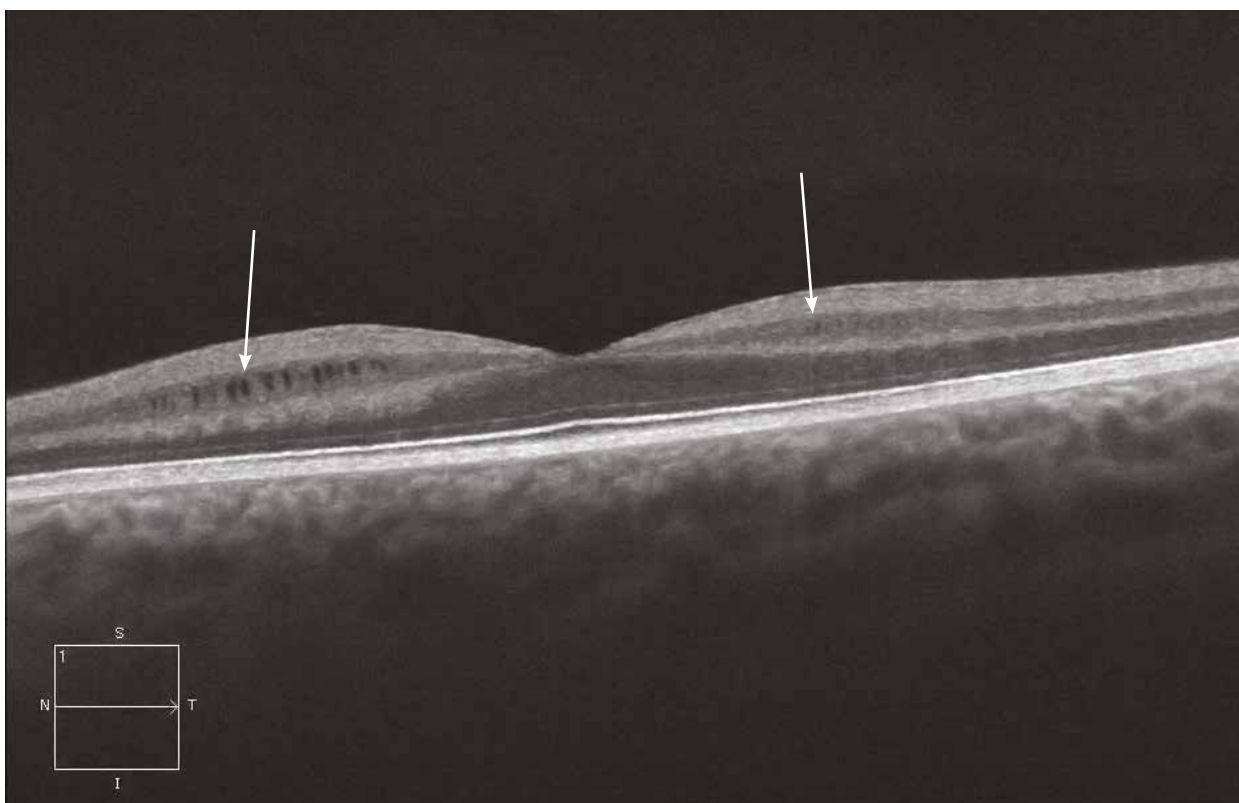
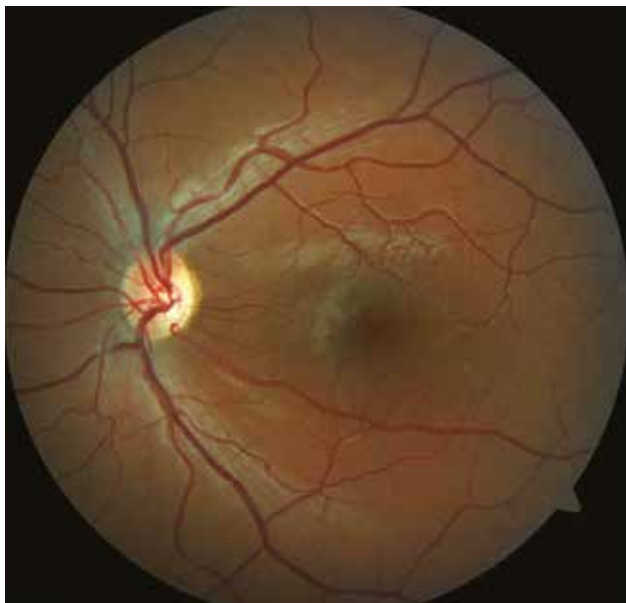
X-linked retinoschisis

Case 1

Fundus examination of a 13-year-old patient presenting with bilateral loss of visual acuity.

A discrete remodelling of the macular region is observed. On OCT, there is a cleavage site in the inner retina with small radial cysts.

Case 1



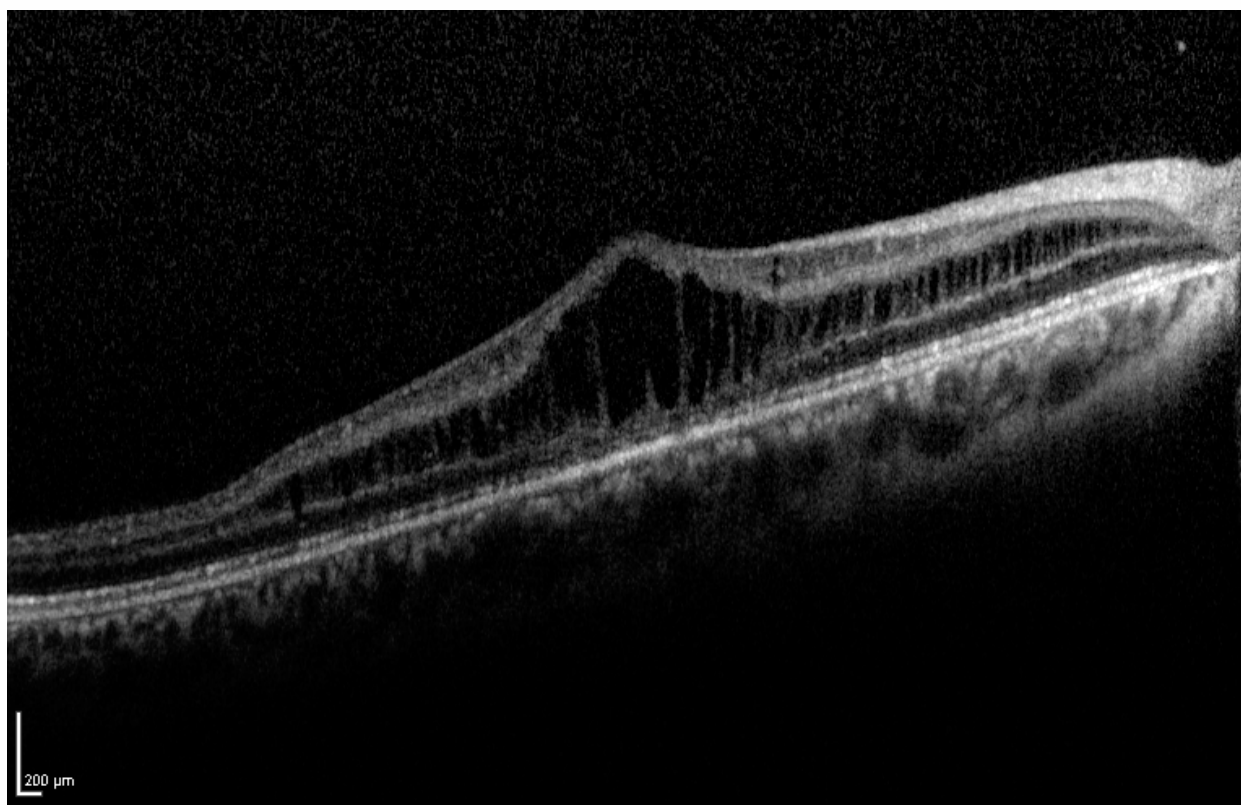
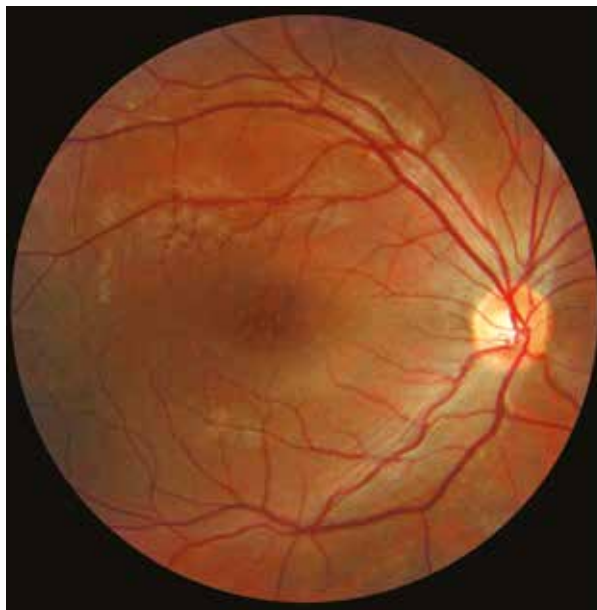
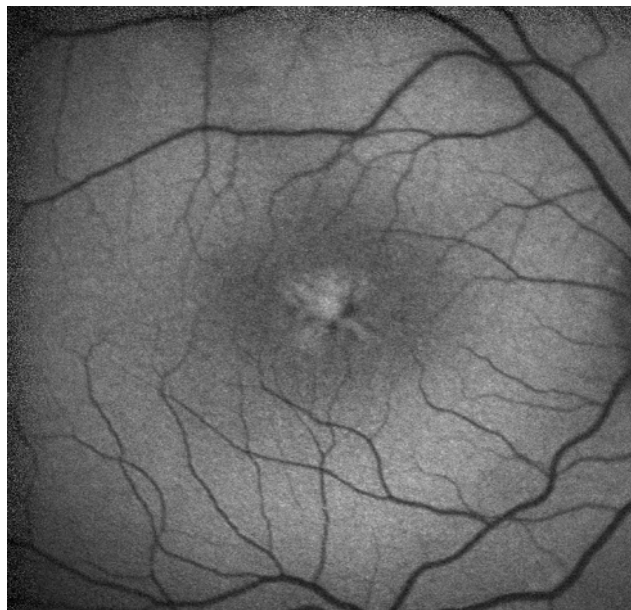Case 2

Characteristic macular remodelings with stellate or “spoke-wheel-like” appearance.

On autofluorescence imaging, the macular pigment distribution is modified by the presence of radial cysts.

On the horizontal OCT section, there is an obvious schisis of the inner retina.

Case 2



8. Myopia

- 8.1. Choroidal thinning**
- 8.2. Dome-shaped macula**
- 8.3. Bruch's membrane rupture**
- 8.4. High myopia neovascularisation**
- 8.5. High myopia foveoschisis**

Choroidal thinning

Case 1

At fundus examination, there is an appearance of moderate choroidosis with peripapillary atrophy, small macular remodellings and choroidal fundus depigmentation.

On the OCT section, the different neurosensorial retinal layers appear well preserved, contrasting with a very thin hyporeflective choroid (red arrows) which loses its three-layer organisation of blood vessels of different calibres, making clearly visible the underlying hyperreflective scleral wall (asterisks).

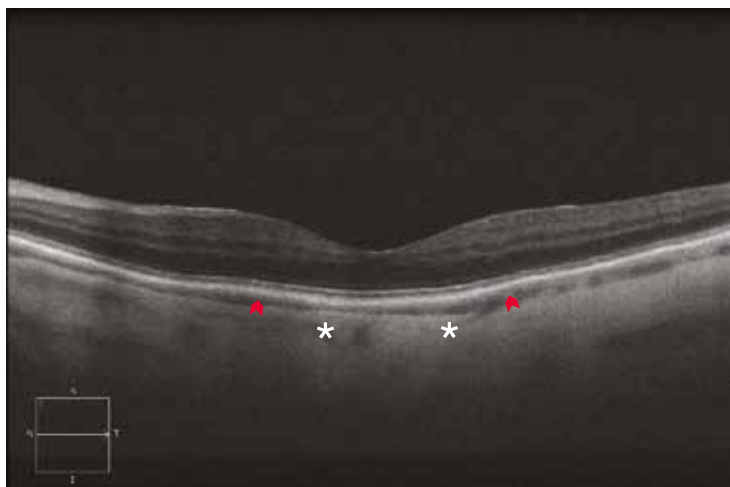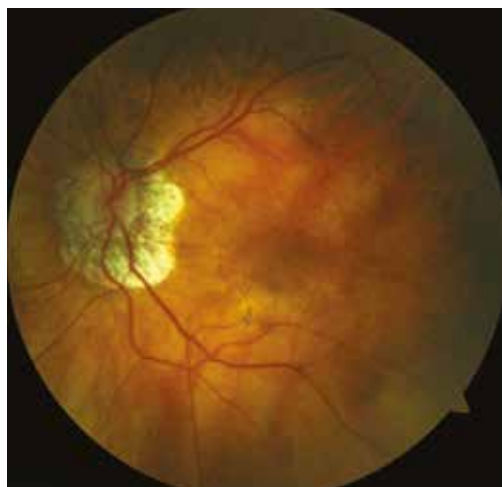Case 2

Another case of moderate choroidosis in a 55-year-old female patient with myopia of -9.00 dioptries.

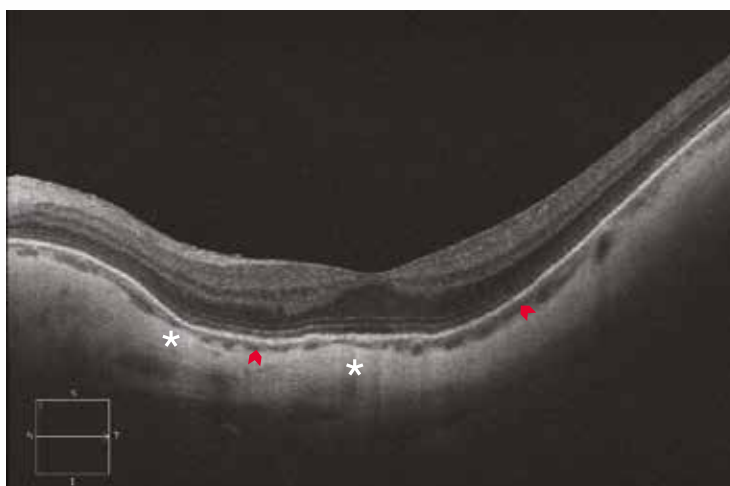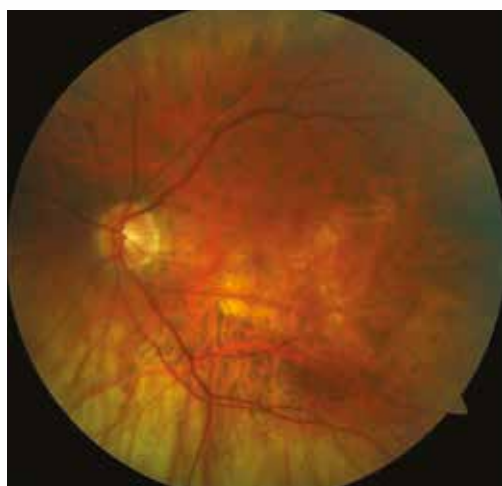The depigmentation of the choroidal fundus is clearly visible enabling to visualise the choroidal vascularisation. There is a moderate staphyloma of the posterior pole.

The OCT section shows again a good preservation of the retinal layers, with a barely visible hyporeflective choroid (red arrows). Note the deformed wall of the hyperreflective sclera next to the staphyloma (asterisks).

Case 1



Case 2



Dome-shaped macula

Case 1

Asymptomatic high myopic patient.

At fundus examination, a myopic staphyloma with peripapillary atrophy extends to the temporal side.

The OCT shows a doming of the macular region associated with choroidal thinning.

Case 2

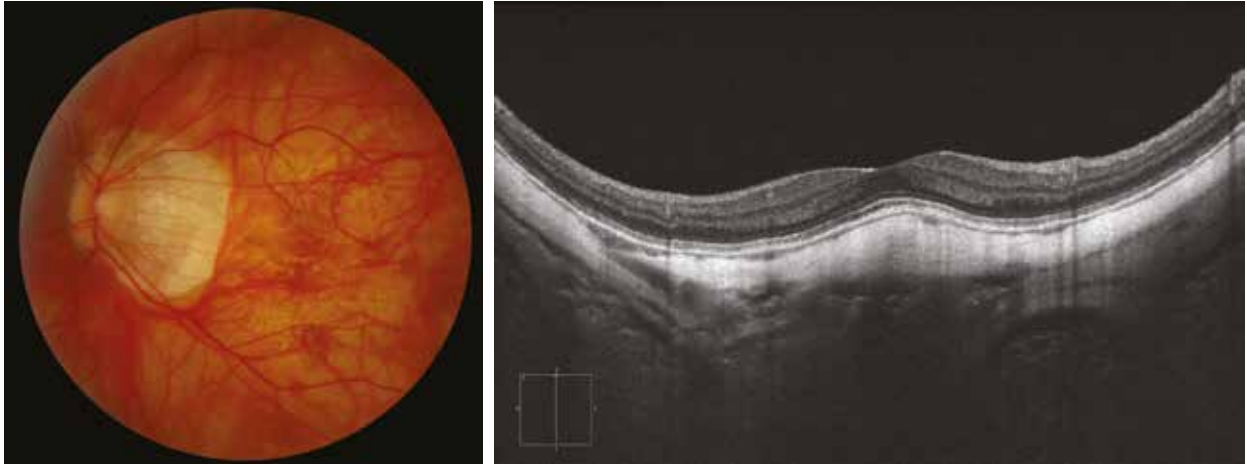Case of dome-shaped macula associated with symptomatic serous retinal detachment.

At fundus examination, there is an appearance of marked detachment of the retinal pigment epithelium in a female patient with a myopia of -6.00 dioptres and presenting with a recent loss of visual acuity of around 4/10.

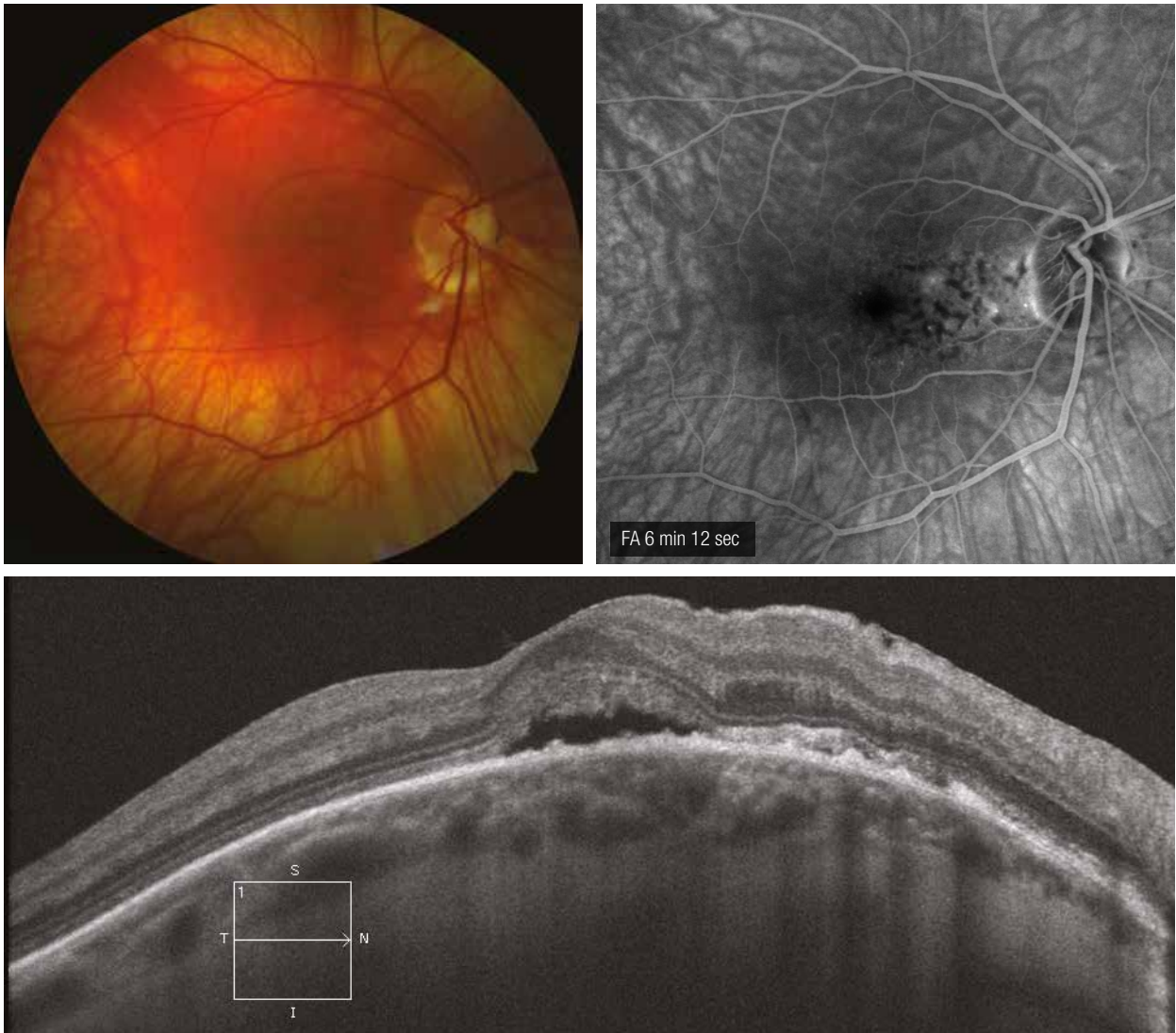
The OCT shows a doming of the centromacular region associated with an adjacent tiny serous detachment.

Angiography shows moderate alterations of the pigment epithelium associated with pinpoint leakage.

Case 1

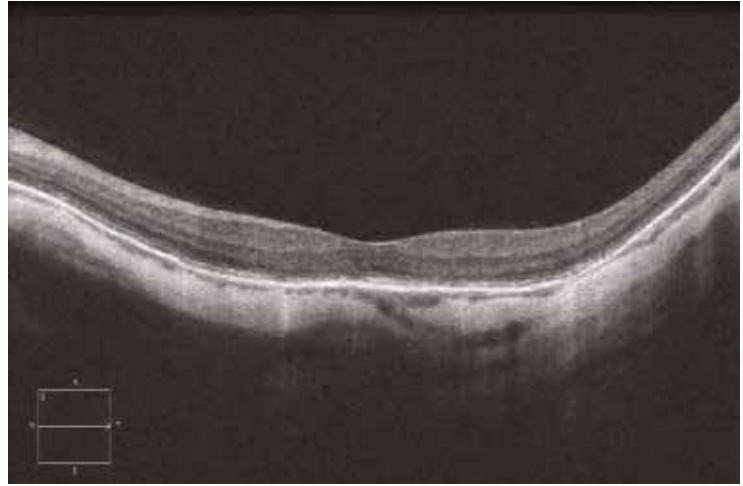
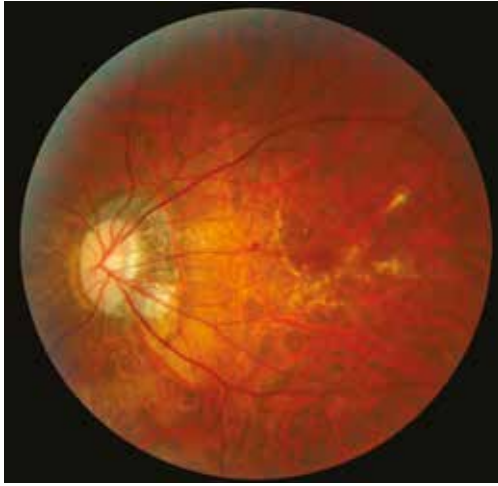
Case 2



Bruch's membrane rupture

At fundus examination, there is an appearance of myopic choroidosis with peripapillary atrophy and depigmentation of the choroidal fundus in a 43-year-old patient with myopia of -18.00 dioptres. In the macular region, there are several whitish rupture lines of the Bruch's membrane of reticulated appearance. Within these rupture lines, except the choroidal thinning, the OCT section does not show any clearly identifiable break. In fact, Bruch's membrane ruptures are not visible in OCT.



High myopia neovascularisation

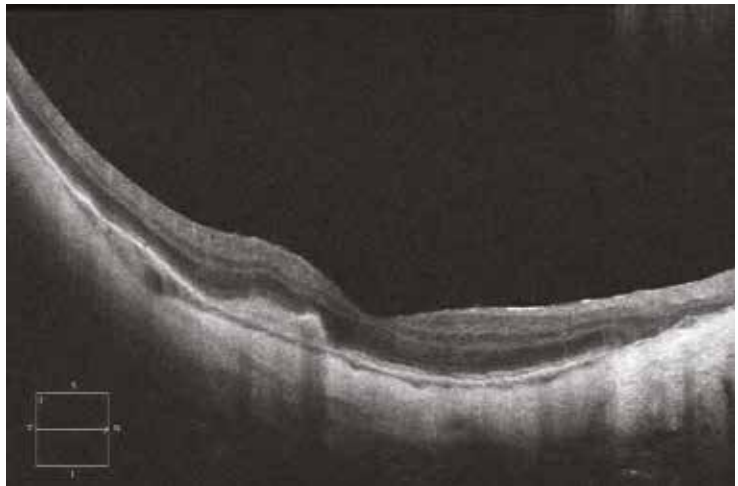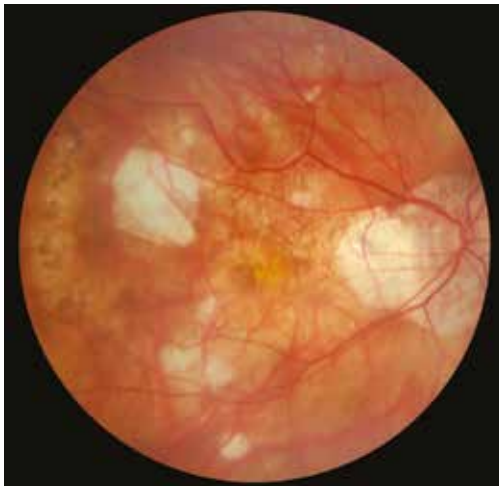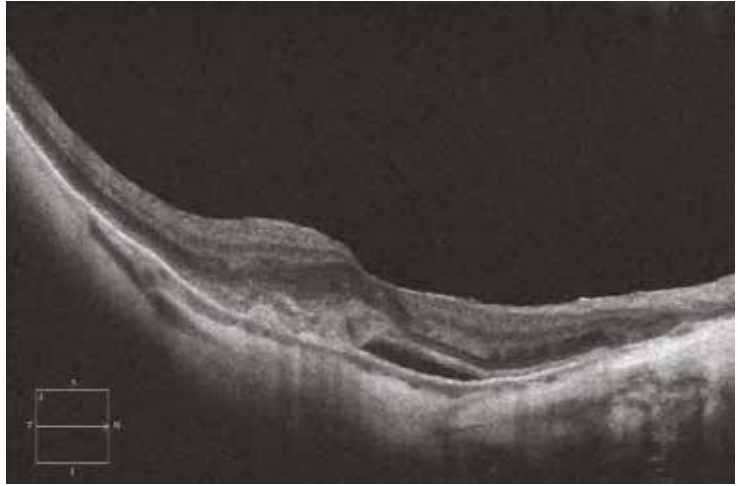
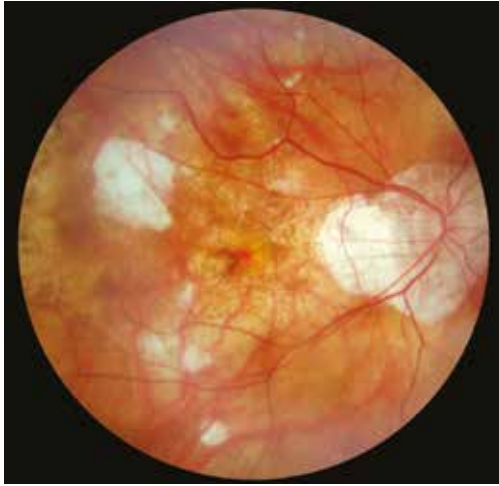The patient reported a sudden loss of visual acuity associated with metamorphopsia.

At fundus examination, there is an appearance of myopic choroidosis with peripapillary atrophy, focal areas of chorioretinal atrophy and macular remodelings consisting of hyperpigmentations and localised haemorrhage.

On the OCT image, there is a pre-epithelial exudative lesion with retrofoveal serous detachment. Note the associated choroidal thinning.

3 months after an intravitreal injection of anti-VEGF, vision increased to 8/10 and the macular haemorrhage was no longer seen at fundus examination. Discrete hyperpigmentation of the scarred neovascular membrane is visible.

On the OCT section, a juxtafoveal subretinal scarring is observed, with good recovery of the retinal tissue located strictly retrofoveally, explaining the functional improvement.



High myopia foveoschisis

Case 1

At fundus examination, there is an appearance of myopic choroidosis with staphyloma.

On the OCT section, the foveal pit is preserved but there are two large cleavage areas within the retinal tissue: a first internal cleavage area which lies between the internal limiting membrane and the ganglion cell layer on the one hand, and the inner plexiform layer and the inner nuclear layer on the other hand, and a second external cleavage area located at the outer plexiform layer. Note also the presence of choroidal thinning and the dome-shaped macula.

Case 2

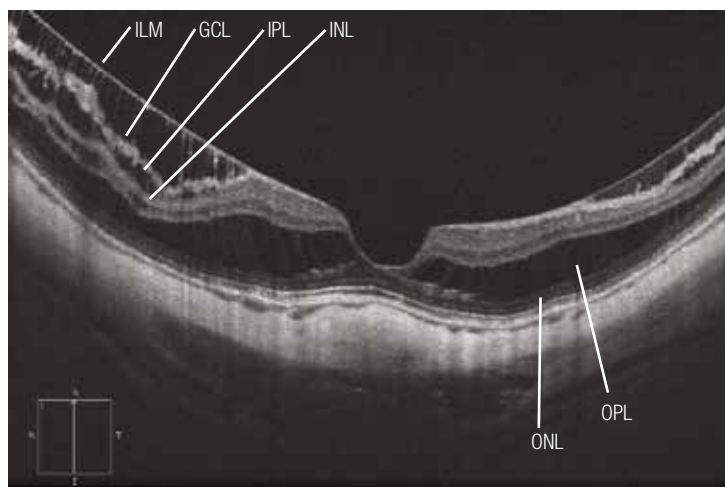
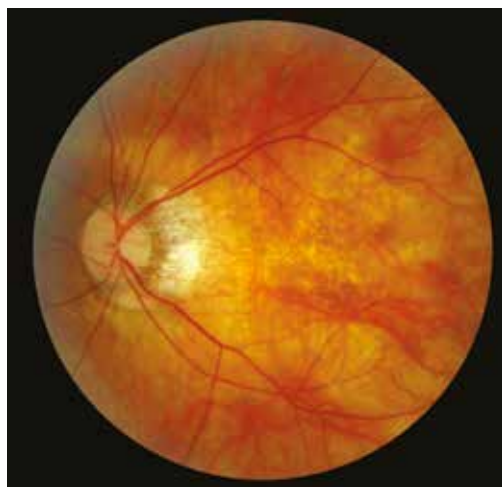In this case, on the fundus image, the choroidosis is more marked, with an area of juxtamacular choroidal atrophy making sclera visible.

On the OCT, in addition to the internal and external cleavage areas described above, there is a clear deformation of the foveal pit with traction of the centromacular region. However, the outer retinal layers remain in contact with the retinal pigment epithelium.

Case 3

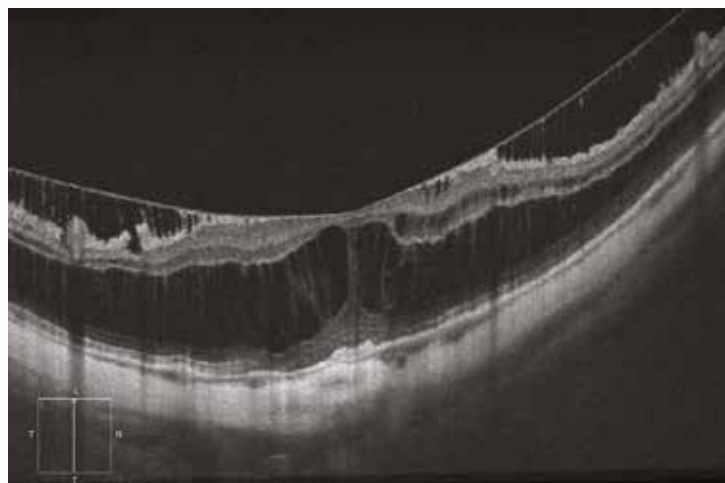
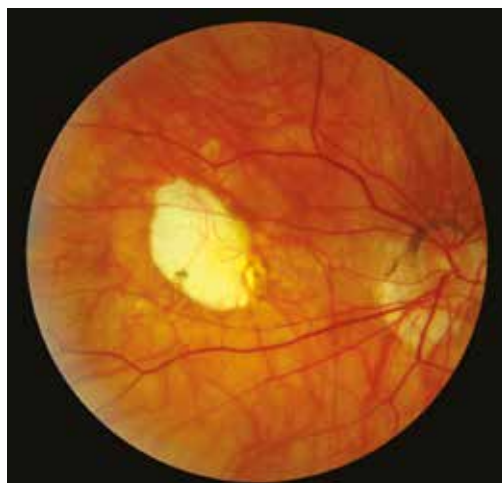In this female patient, in addition to the external cleavage, there is a loss of contact between the centrofoveal photoreceptors and the underlying pigment epithelium (asterisk). This is a poor prognostic factor which may lead to indicate surgery.

Case 1

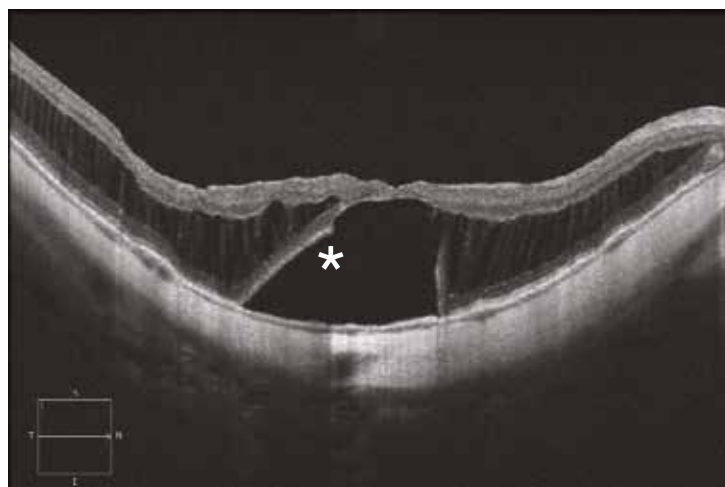
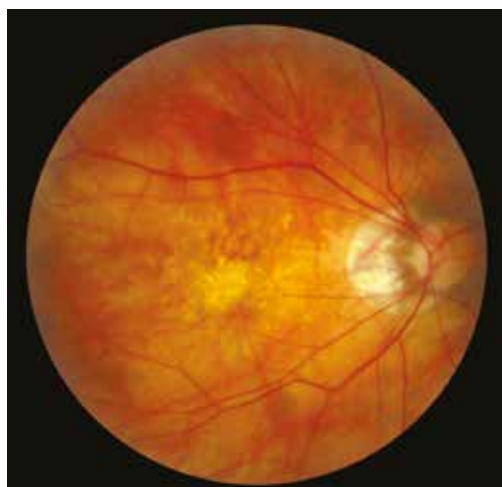

ILM: internal limiting membrane; GCL: ganglion cell layer; IPL: inner plexiform layer; INL: inner nuclear layer; OPL: outer plexiform layer; ONL: outer nuclear layer.

Case 2



Case 3



9. Central serous chorioretinopathy (CSCR) and other serous retinal detachments

9.1. Typical CSCR

9.2. Chronic CSCR and diffuse retinal pigment epitheliopathy (DRPE)

9.3. Other causes of serous retinal detachment

9.3.1. Hypertension (2 cases)

9.3.2. Purtscher's retinopathy

9.3.3. Colobomatous pit

9.3.4. Iatrogenic causes

9.3.5. Rhegmatogenous retinal detachment

9.3.6. Postoperative causes

9.3.6.1. Episcleral surgery outcomes

9.3.6.2. Subretinal perfluorocarbon liquids

Typical CSCR

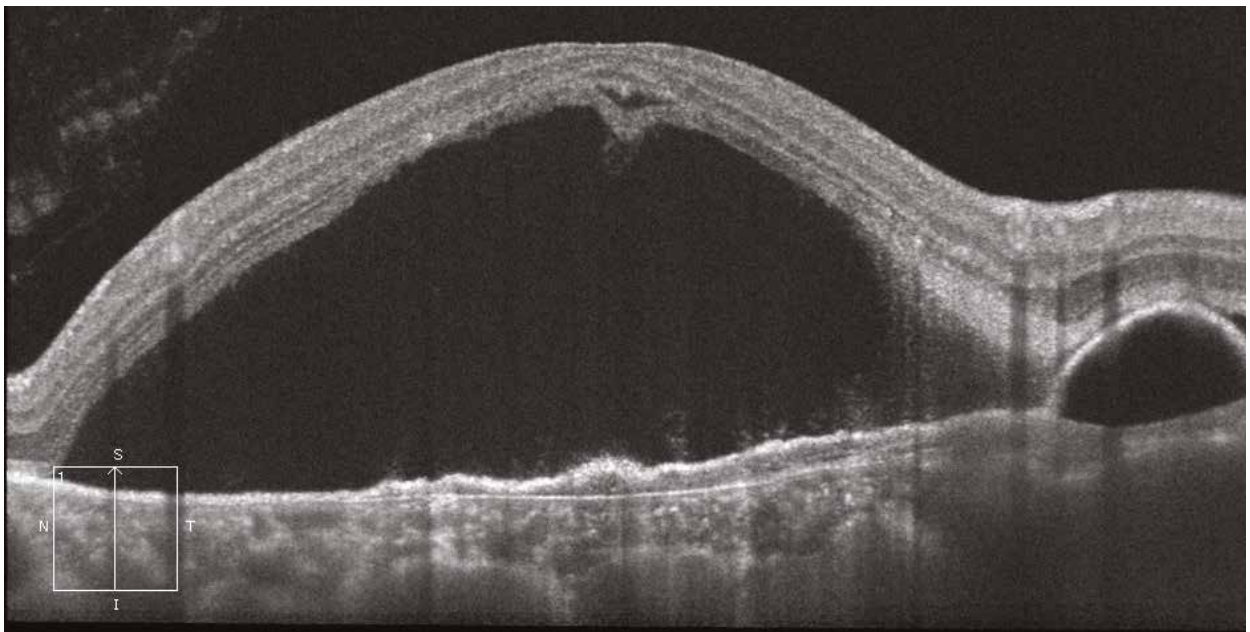
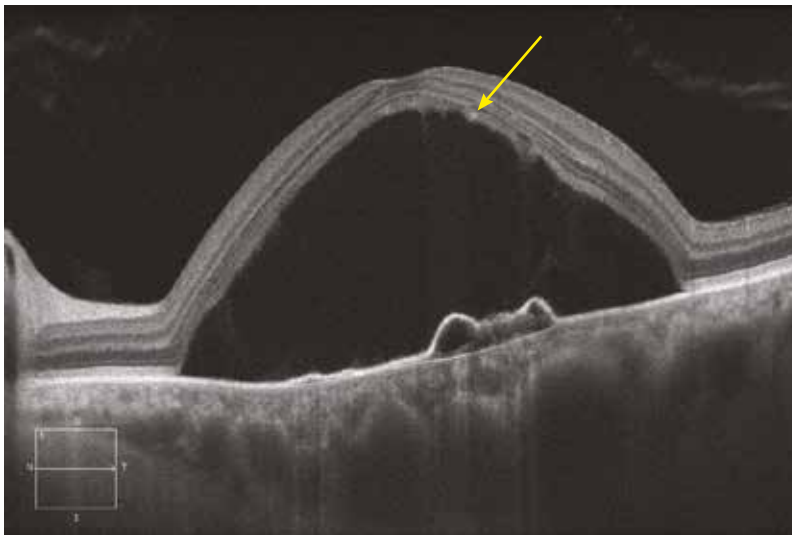
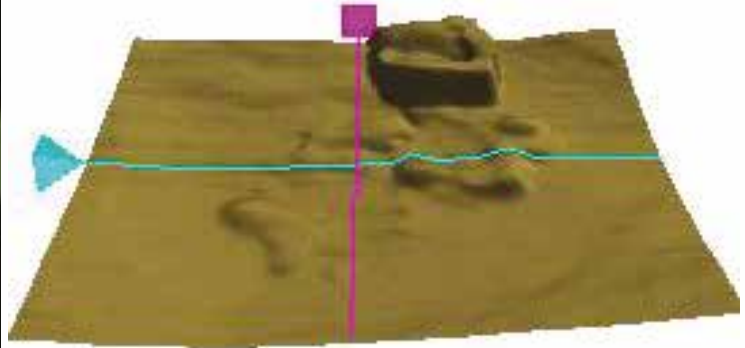
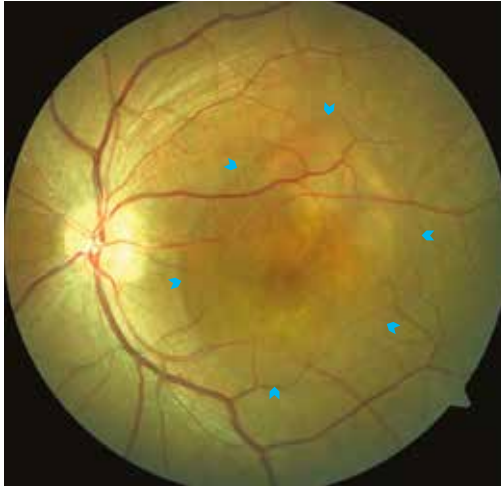
Central serous chorioretinopathy (CSCR) is a condition that occurs more frequently in men and causes serous retinal detachment. Although its origin is unknown, it is agreed that it results from a dysfunction of the choroidal permeability.

Case 1

On the colour image, there is a blister-like elevation of the macula with clear margins (solid arrows) corresponding to a serous retinal detachment (SRD). Within the SRD, there are some small subretinal white spots indicative of the chronicity of the disease.

On the horizontal OCT section, the SRD is large, globally homogeneous and hyporeflective. Within the SRD there is a PED next to a focal leakage point. The neurosensory retina remains normal overall. However, there are some hyperreflective spots on the posterior surface of the photoreceptors line (yellow arrow), which correspond to the white dots seen on the colour image. The vertical section shows another PED corresponding to a second focal leakage point. On the retinal mapping focalised on the RPE layer, these PEDs are readily visible as elevations.

Case 1

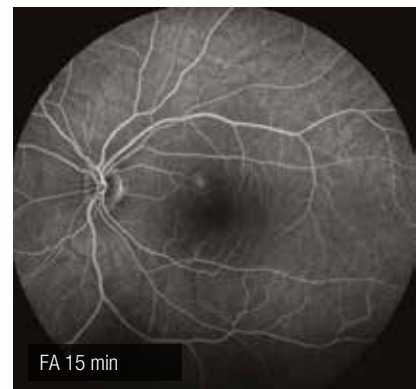
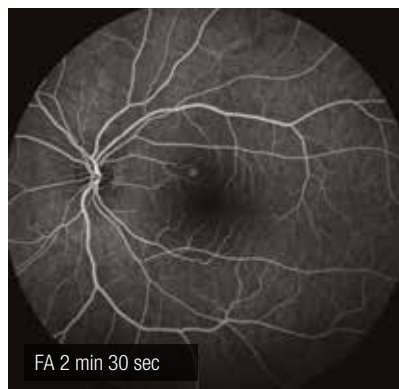
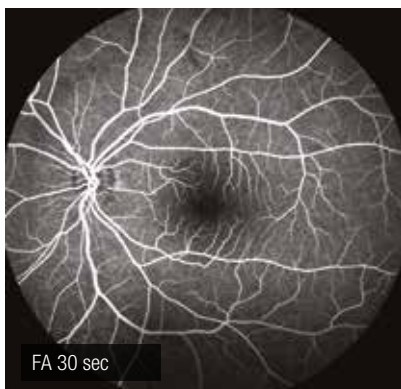
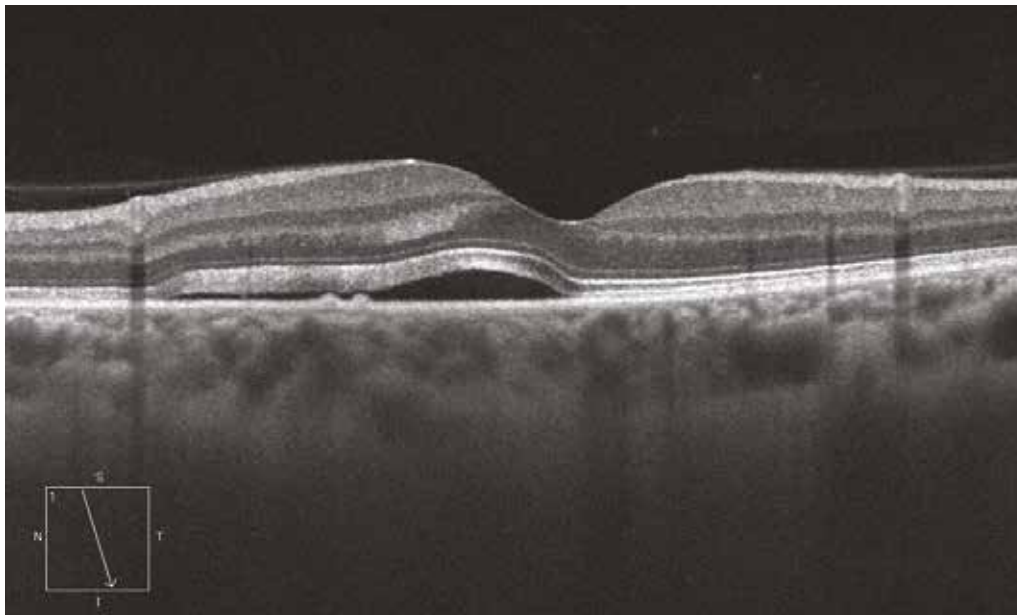
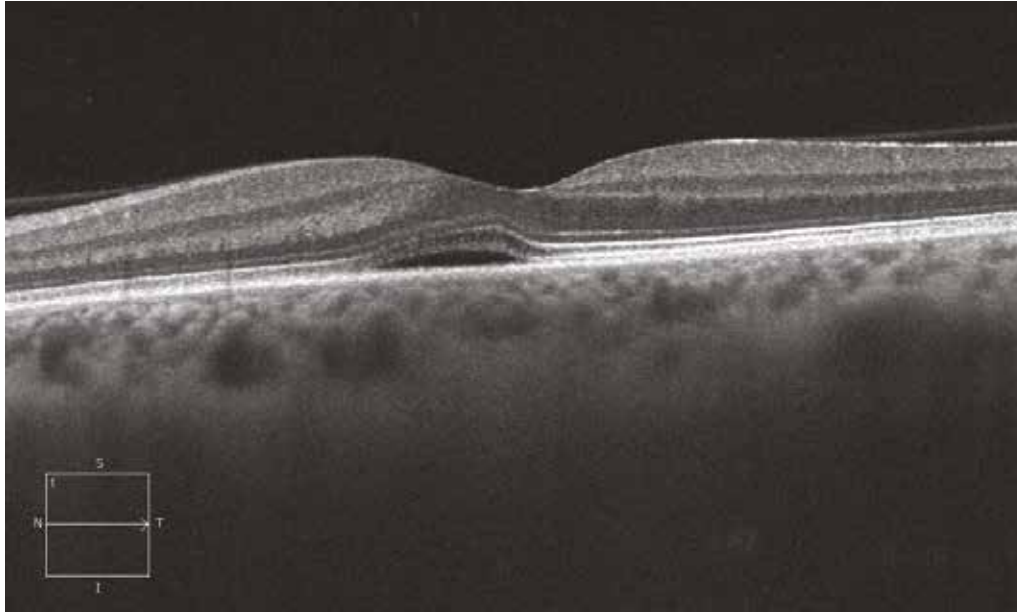


Case 2

In this case of CSCR, the SRD is almost flat on the horizontal section. However, through the focal leakage point, there are two small juxtaposed PEDs corresponding to the leakage site. The overlying neurosensory retina shows no abnormalities.

The focal leakage point is easily identified by fluorescein angiography at intermediate phase (2 min 30 sec), while it was not observed at early phase (30 sec). Fluorescein leakage remains limited at late stage (15 min).

Case 2



Case 3

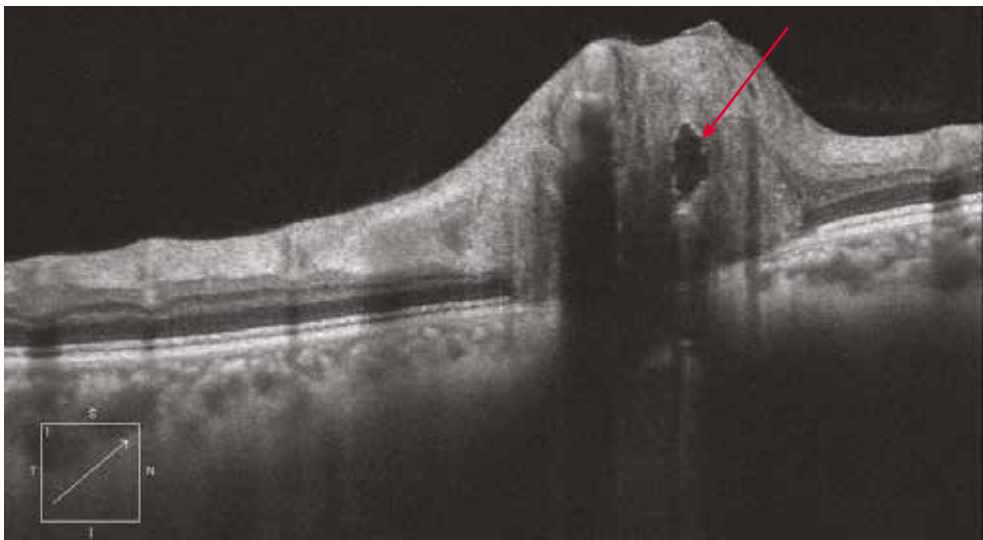
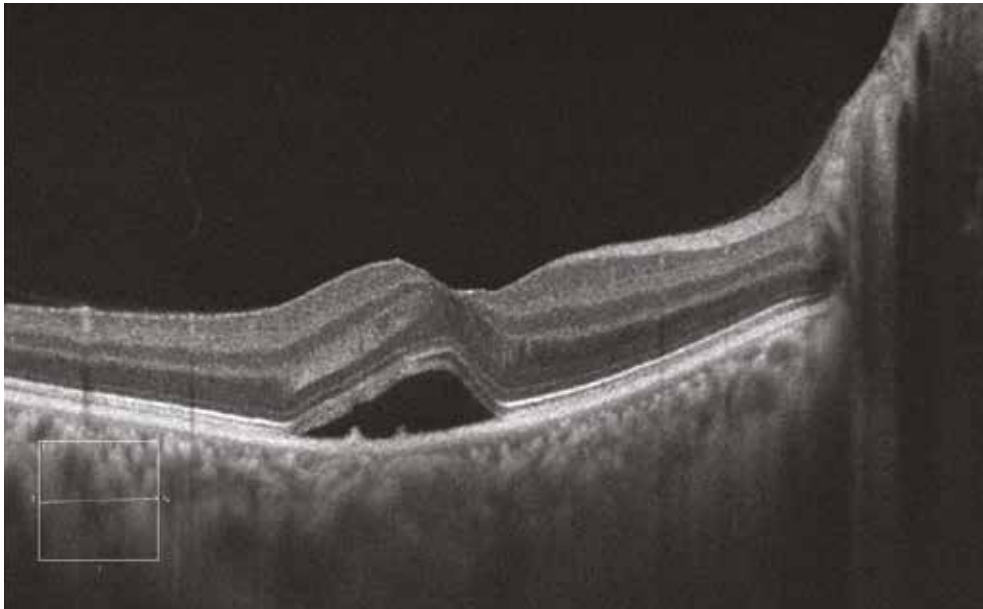
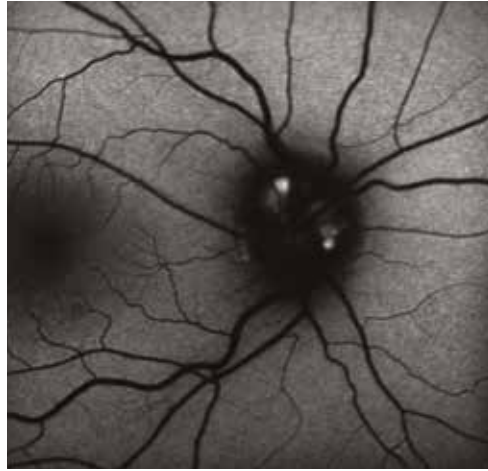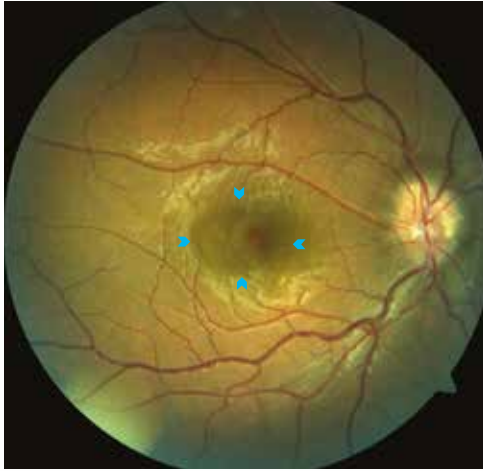Here, there is a minimal SRD on the colour image (solid arrows). Note also the blurring appearance of the margins of the papilla corresponding to drusen.

The autofluorescence image of the papilla confirms these drusen as a hyperautofluorescent elements.

The macular OCT reveals a SRD with two RPE irregularities at the focal leakage point.

The section in EDI mode also shows abnormally thickened choroid as frequently seen in CSCR. Finally, the OCT section in EDI mode passing through the head of the optic nerve shows a globally round hyperreflective cavity corresponding to the drusen (red arrow).

Case 3



Diffuse retinal pigment epitheliopathy (DRPE)

Chronic CSCR is defined as CSCR lasting more than 6 months. DRPE refers to diffuse forms of chronic CSCR, with multiple focal leakage points. The diffusion shown at angiography is generally weaker compared with typical CSCR and is sometimes restricted to an area of diffusion with blurred margins. The retinal pigment epithelium is often altered, with signs of gravitational depigmentation.

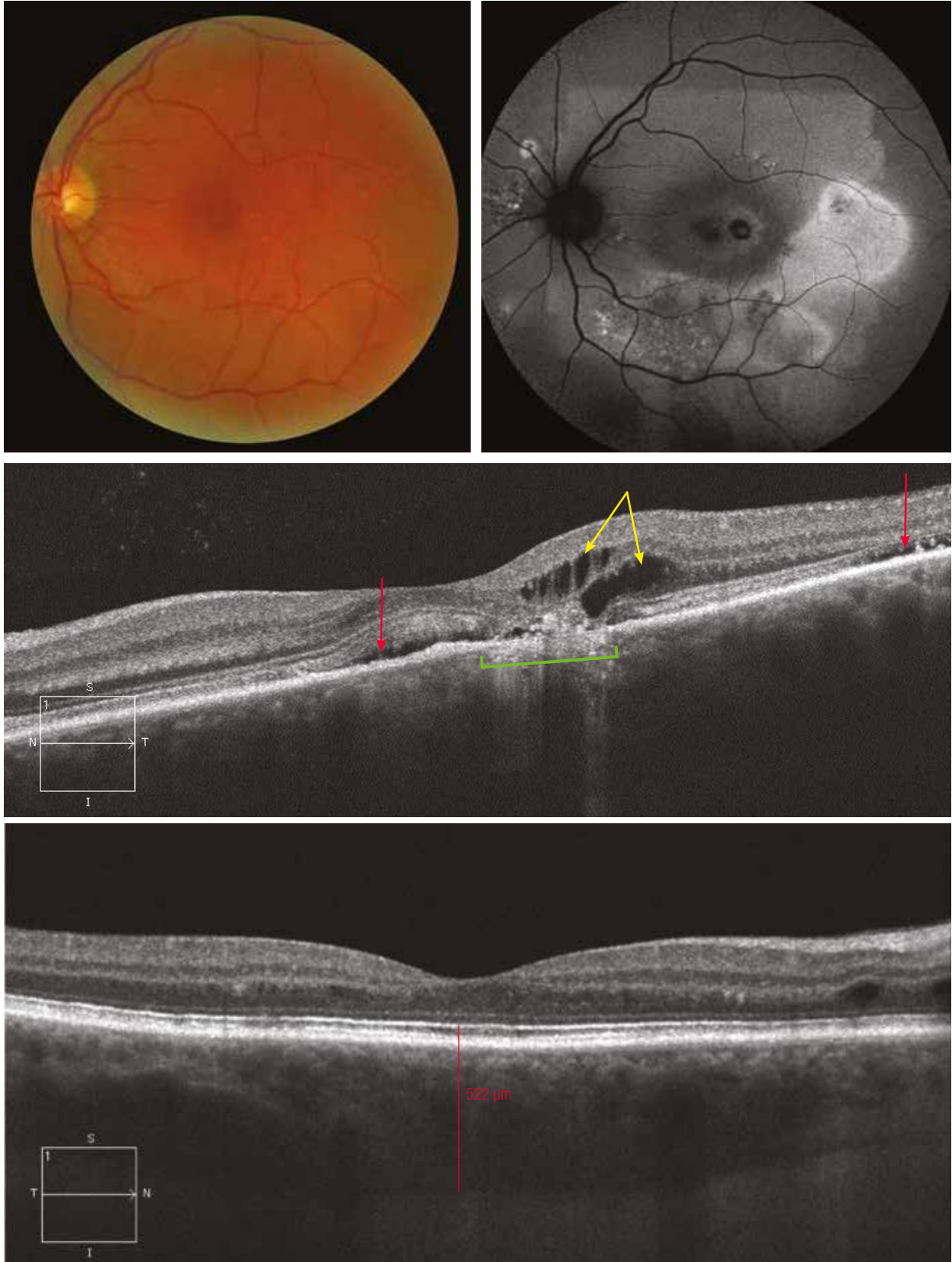
Case 1

The colour image only reveals very discrete alterations shown as scattered areas of pigment migrations. The autofluorescence is more contributive, showing significant retinal pigmentation changes composed of hyperfluorescent and hypofluorescent areas. Gravitational descending atrophic retinal pigment epithelial tracks are often associated.

The horizontal OCT section through the macula allows to identify two flat SRDs (red arrows), intraretinal cysts (yellow arrows) and an atrophied area of RPE (green line). The presence of hyperreflective elements in the SRD is consistent with the chronicity of the SRD.

On EDI mode OCT of the contralateral eye, the choroidal thickness is very increased (red line) and only two small intraretinal cysts are observed.

Case 1



Diffuse retinal pigment epitheliopathy (DRPE)

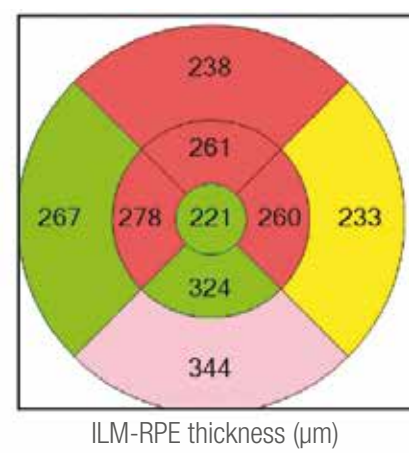
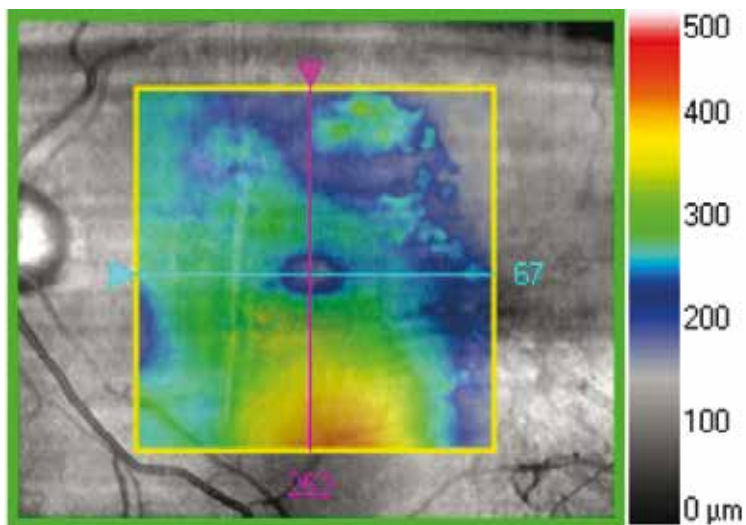
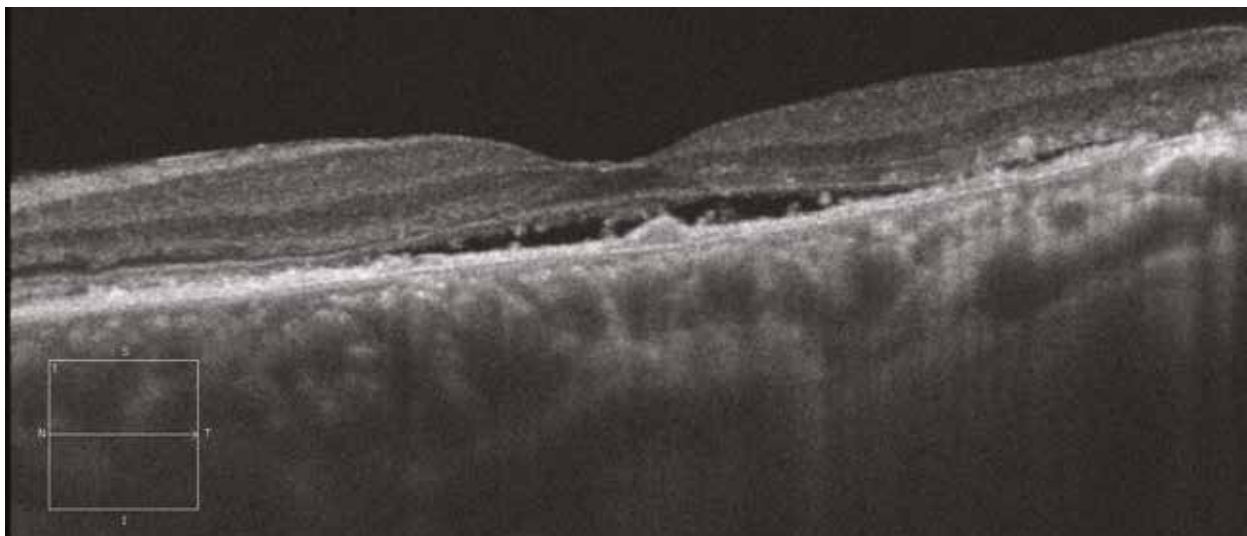
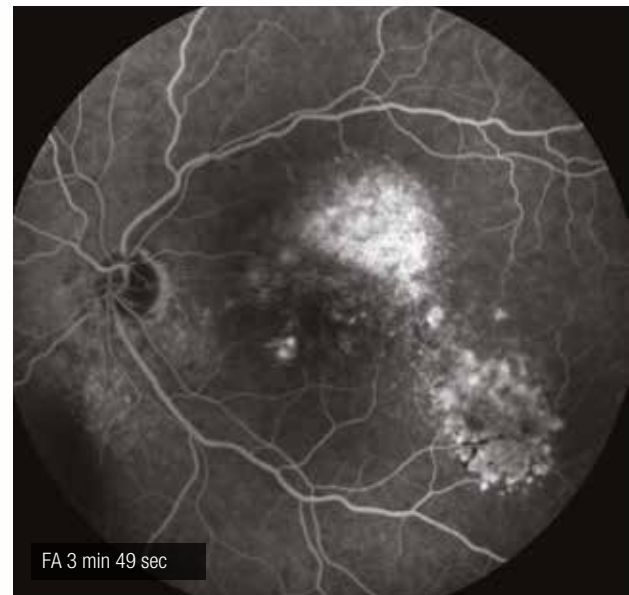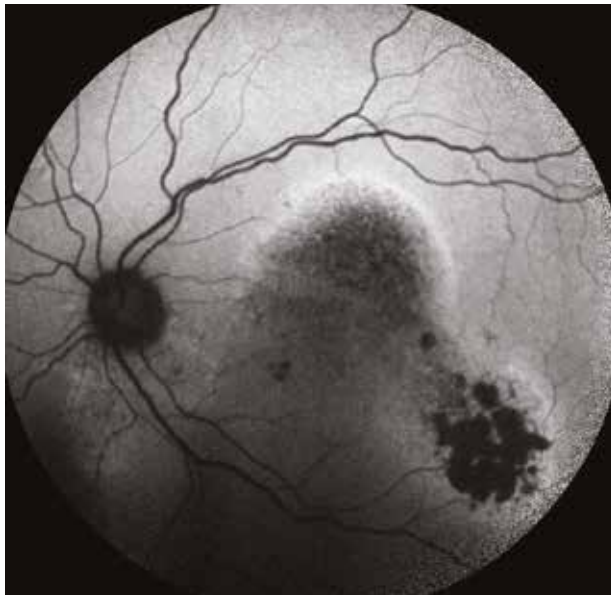Case 2

Autofluorescence shows the signs of retinal depigmentation with hypoautofluorescent areas (with gravitational topography) limited by a hyperautofluorescent line. The fluorescein angiography at late stage (3 min 49 sec) reveals a diffuse hyperautofluorescent area in the superotemporal region of the macula.

The OCT section through the macula shows characteristic features of DRPE: a flat SRD, atrophy of the RPE adjacent to the SRD, hyperreflective spots on the external edge of the inner retina (indicative of the chronic stage of the elevation) and a choroidal thickening. A small PED is observed, probably juxtaposed to a focal leakage point.

The retinal mapping, which allows to measure the retinal thickness between the internal limiting membrane and the RPE, shows that the SRD is greater in the inferior region, resulting from the gravitational flow of the subretinal fluid towards the bottom.

Case 2



Hypertension

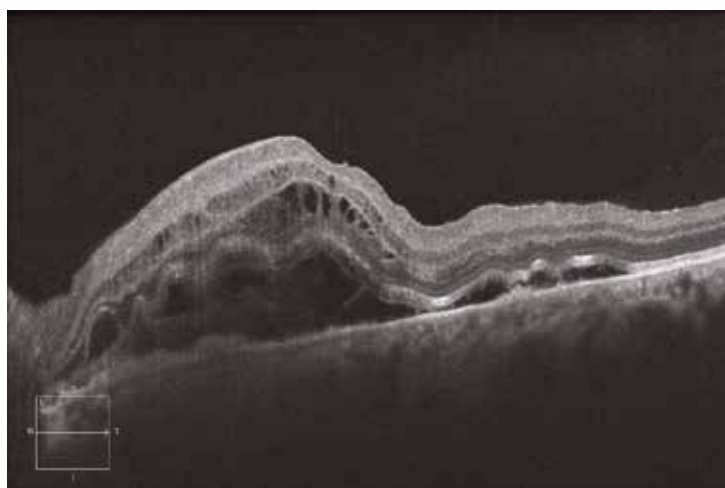
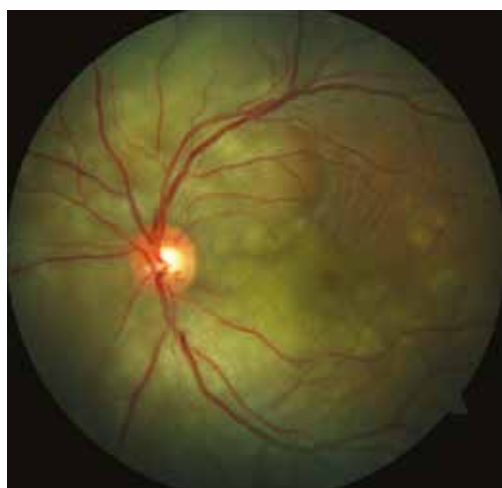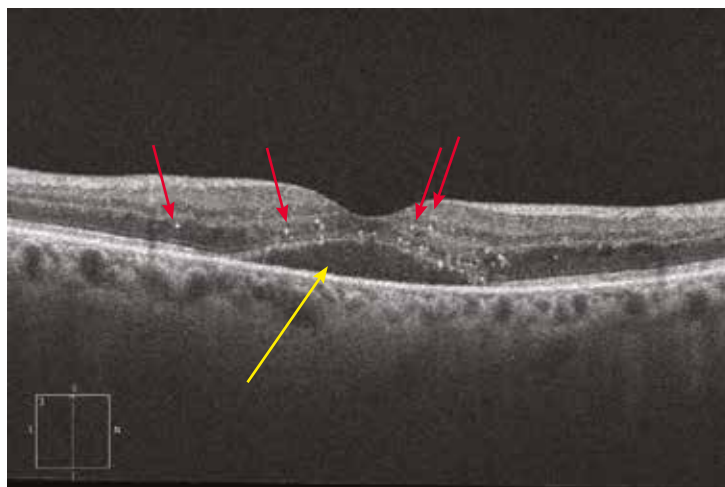
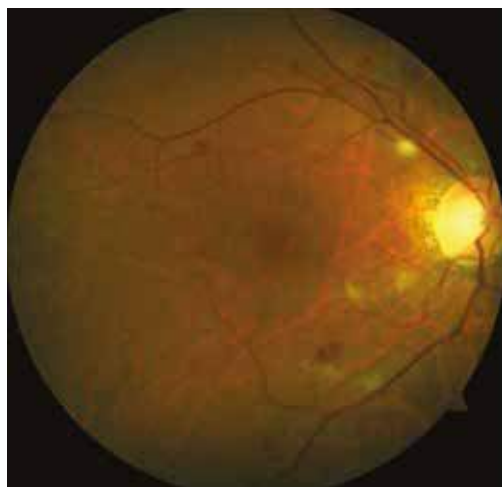In case of acute high blood pressure, a hypertensive choroidopathy (i.e. choroidal ischaemia) may develop as SRD usually in the macular region. The resorption of this macular SRD upon treatment usually leads to the formation of exudates with a macular star pattern.

In the present case, the OCT reveals the SRD (yellow arrow) but also intraretinal hyperreflective spots (red arrows) corresponding to intraretinal exudates not yet visible at fundus examination. In contrast, on the colour image, there are cotton wool spots and retinal haemorrhages.

Pre-eclampsia

The primary ocular signs of pre-eclampsia are ischaemia of the choroid and RPE, leading to multiple SRDs and yellowish patches, respectively. Haemorrhages and cotton wool spots are rarely observed at this stage.

Here, the OCT shows large and numerous SRDs. They are associated with a retinal oedema secondary to the retinal arterial spasm produced by the acute hypertension. All ocular signs resolve upon systemic treatment.



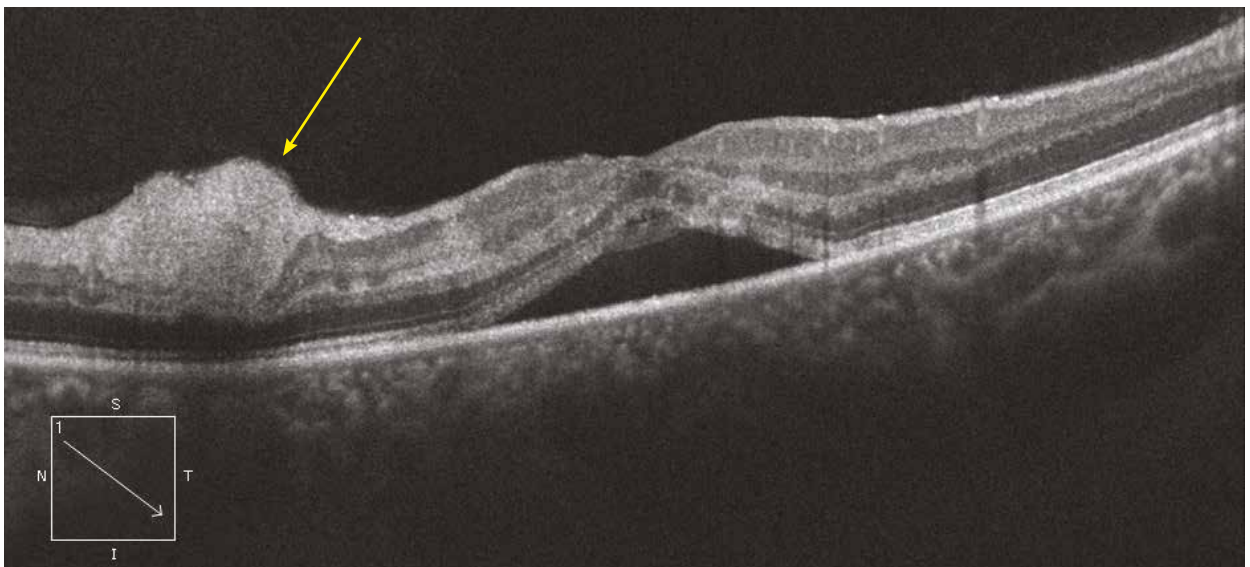
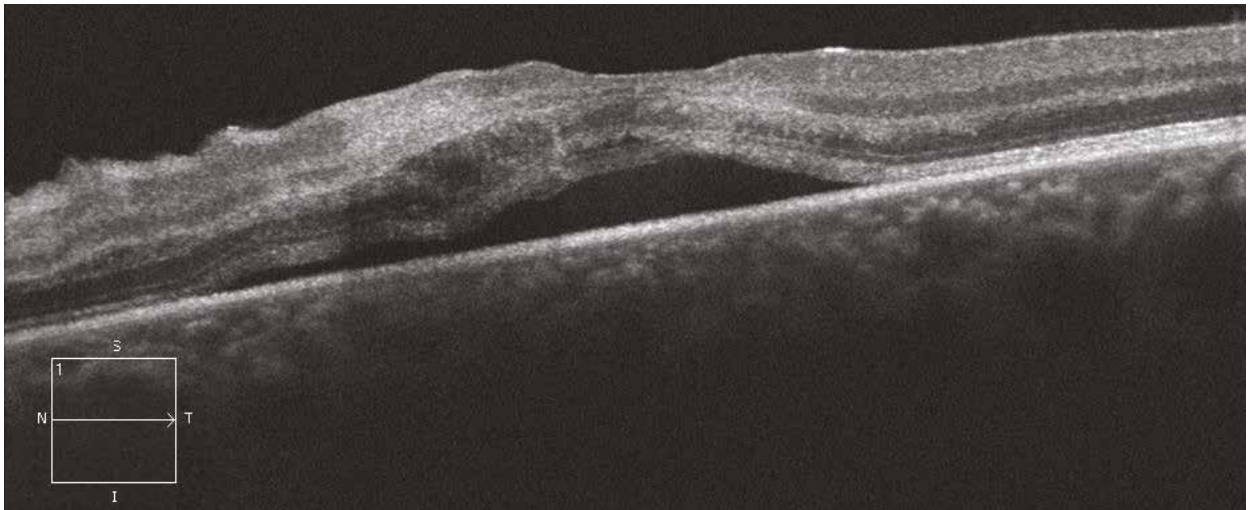
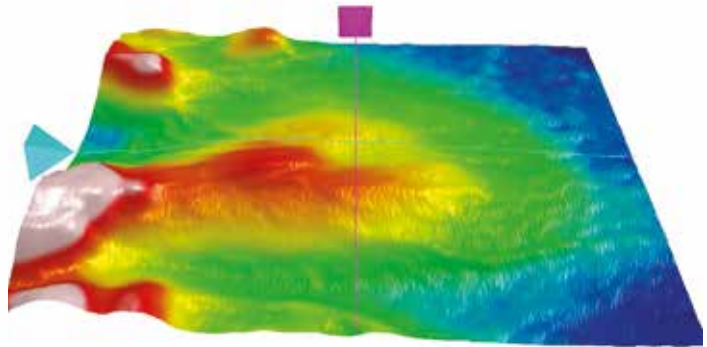
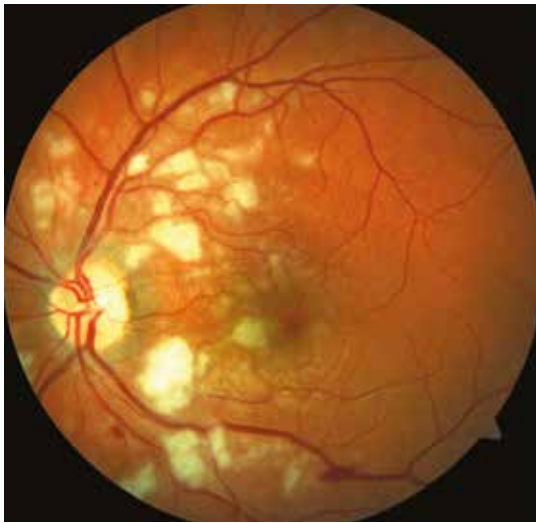Purtscher's retinopathy

This is a post-traumatic retinopathy without direct ocular contusion.

At fundus examination, there are multiple cotton wool spots and flame-shaped haemorrhages.

The horizontal OCT section shows a serous retinal detachment associated with a photoreceptor line thickening. An oblique section through a cotton wool spot shows a rounded hyperreflective lesion (yellow arrow) in the ganglion cell layer. Histologically, cotton wool spots correspond to an ischaemia in the ganglion cell layer and to a swelling of axons due to the axoplasmic transport blockade.

The retinal mapping shows a global retinal thickening, with elevated areas adjacent to the cotton wool spots.

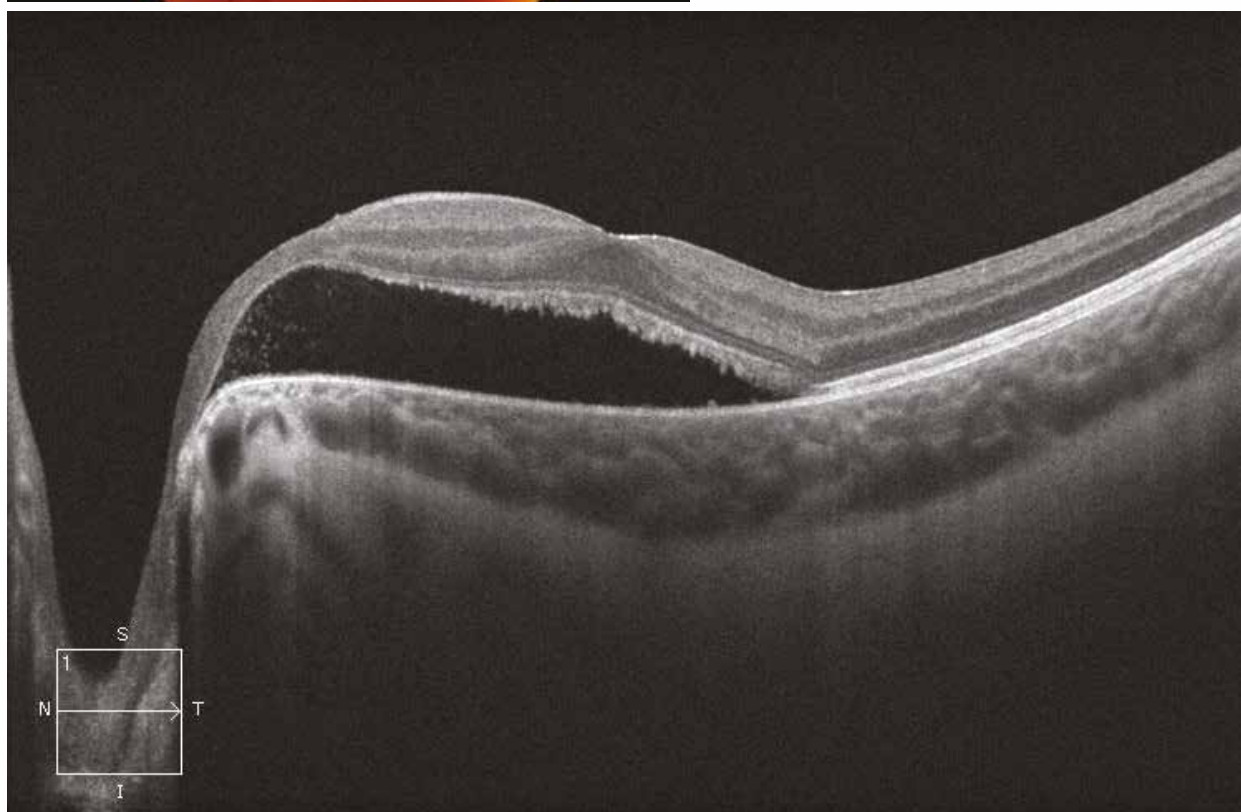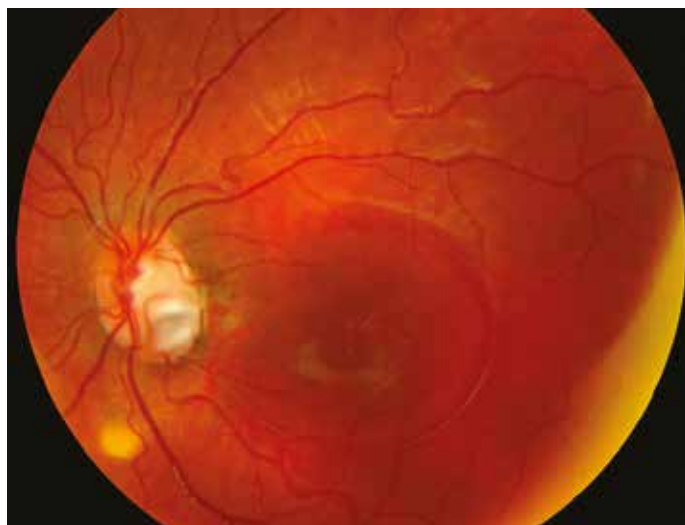


Colobomatous pit

A 6-year-old child presenting with a loss of visual acuity since several weeks.

At fundus examination, there is a blister-like elevation of the macula corresponding to a serous retinal detachment and, in the inferotemporal region of the papilla, a greyish oval lesion greatly suggestive of colobomatous pit.

On the OCT section, there is a large serous retinal detachment involving the macular region in contact with the optic nerve. The external segments of the photoreceptor line, separated from the retinal pigment epithelium, take a comb-like appearance; the other retinal layers adjacent to the detachment are intact.

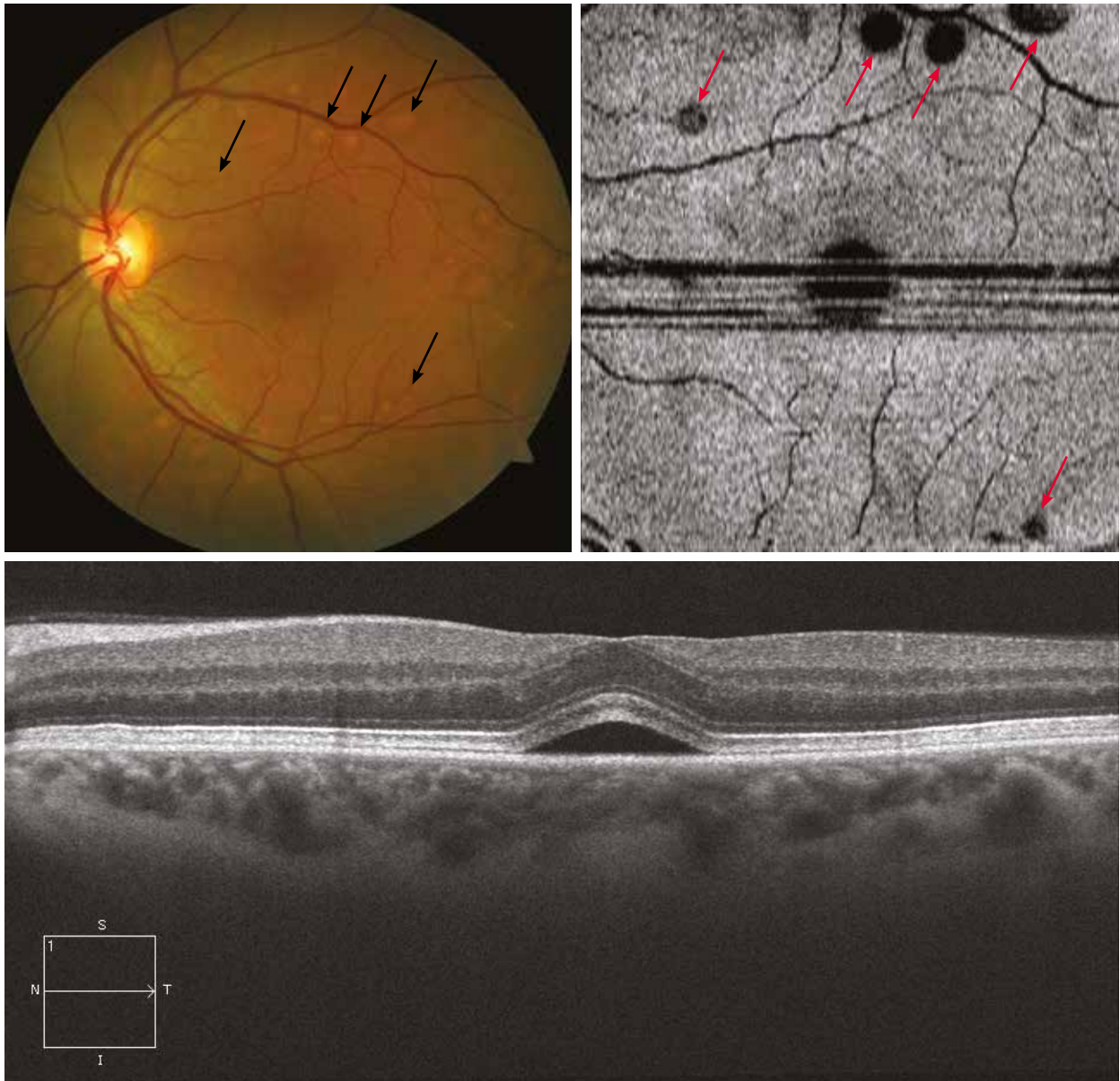


SRD: iatrogenic causes

Sudden onset of multiple SRDs following a cancer therapy (MEK inhibitors).

On the OCT section, a SRD is isolated without other abnormalities.

On the “en-face” OCT, hyporeflective images correspond to SRDs on the colour image (arrows).



Rhegmatogenous retinal detachment

Case 1

Very recent retinal detachment in a pseudophakic patient presenting with a loss of visual acuity since 24 hours.

The ocular fundus examination reveals retinal folds in the inferotemporal region of the macula. The aspect of the peripheral retina is consistent with a retinal tear at 8 o'clock.

The vertical OCT section reveals the temporal and foveal detachment. The retina between the macula and the optic nerve remains flat. The detached retinal layers show a "normal" structure.

Case 2

Another case of a long-standing rhegmatogenous retinal detachment.

The foveal retina is separated from the RPE with, in this case, objective signs of cellular stress: intraretinal cysts and undulations of the outer retina.

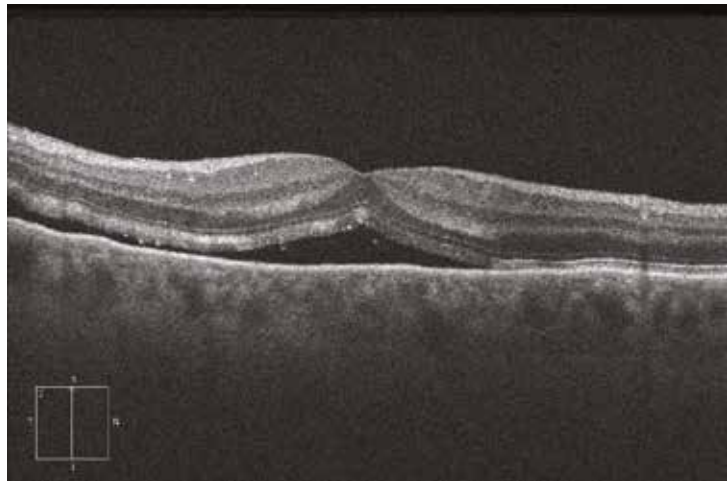
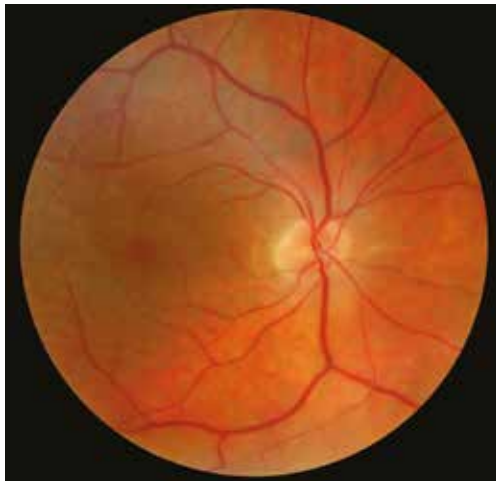Case 3

Case of long-standing and slowly progressive retinal detachment.

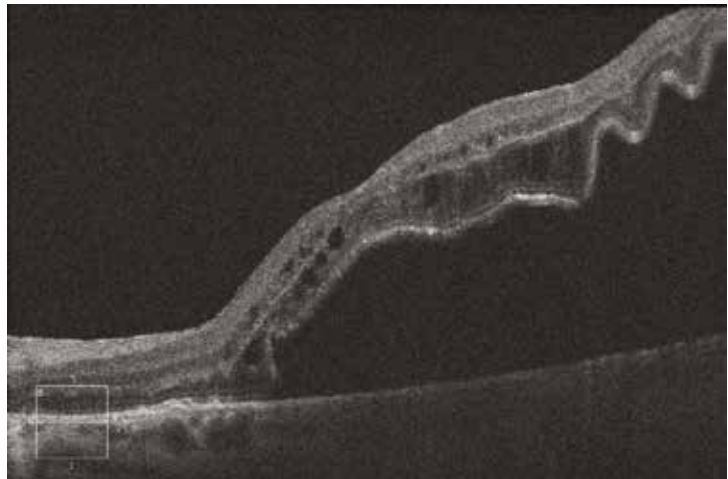
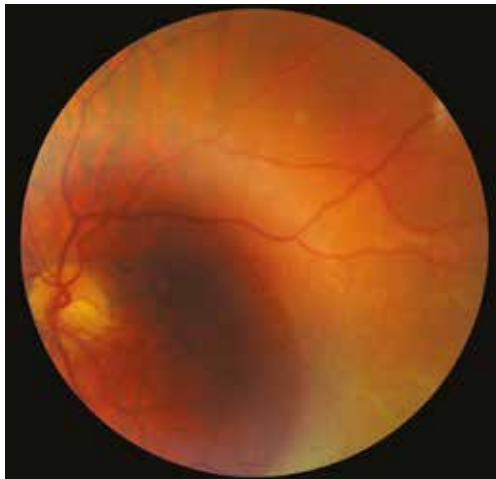The patient is asymptomatic with visual acuity preserved at 20/20. On the colour image, however, there is a large bullous detachment of the superior, nasal and inferior retina with pigmented demarcation lines (arrows), and a progression of the retinal detachment towards the posterior pole so far self-limited.

The vertical OCT section shows a quite flat central retina but with intraretinal cysts and a hyperreflective area of RPE proliferation (arrow) corresponding to the demarcation line on the colour image and limiting the progression of the detachment towards the macula (asterisk).

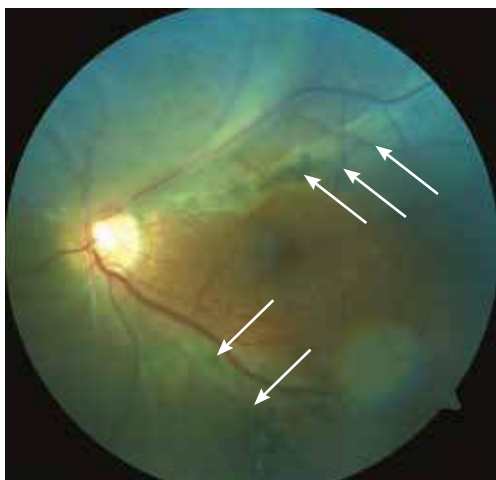
Case 1



Case 2



Case 3



Episcleral surgery outcomes

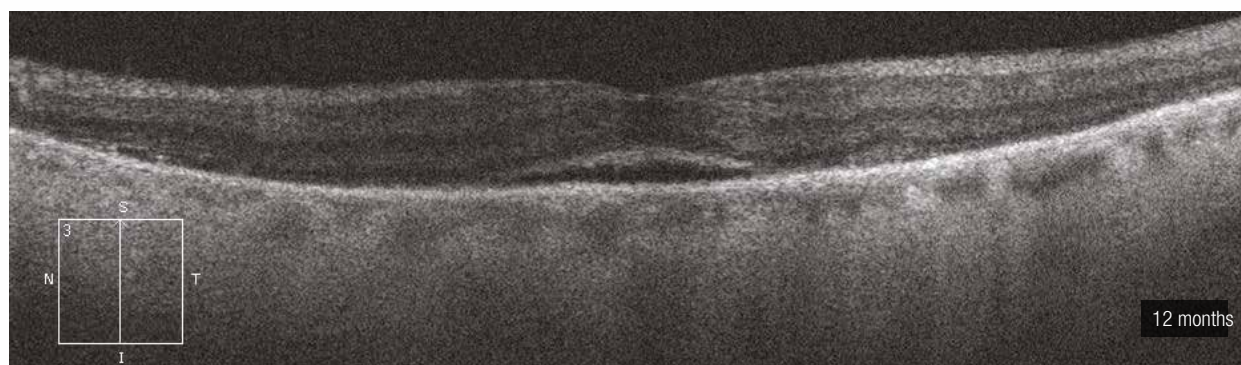
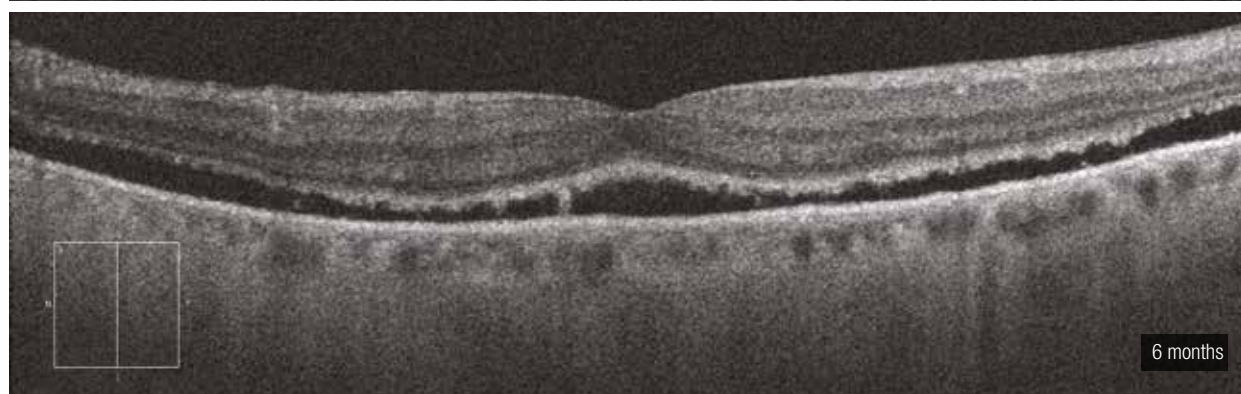
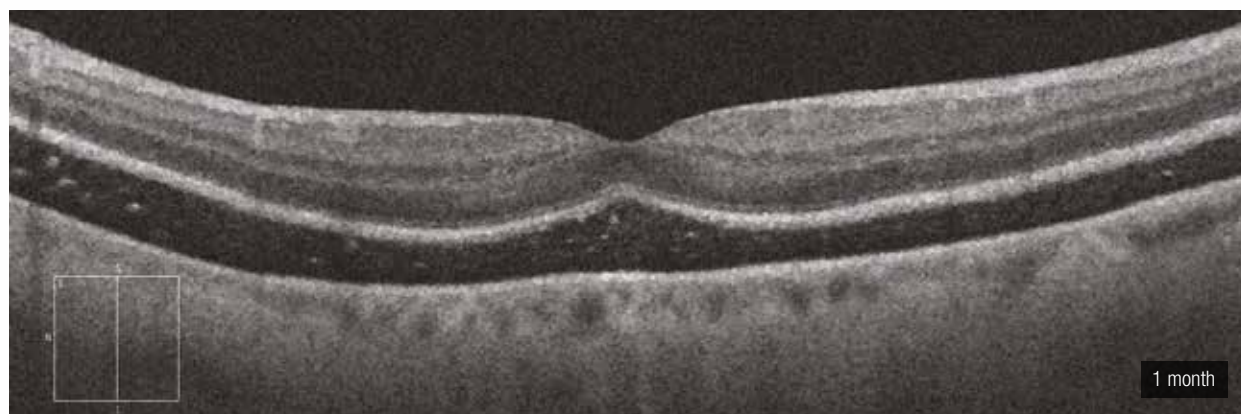
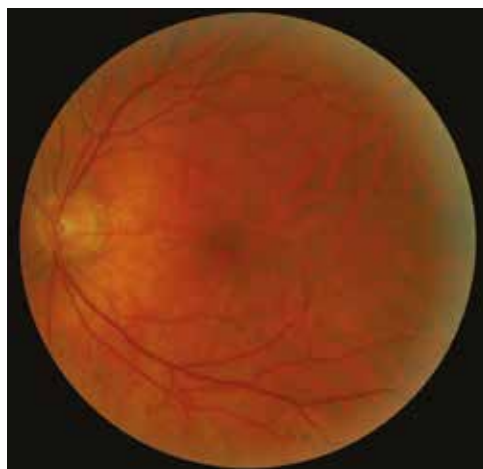Phakic patient who underwent surgery for macula-off retinal detachment using scleral buckling.

At 1 month post-operatively, fundus examination shows a well reattached retina. However, the patient still has metamorphopsia.

On the OCT section, there is a persistent serous retinal detachment. The heterogeneous aspect of the detachment with hyperreflective spots is consistent with a thick, and probably old, subretinal fluid. The retinal layers show a normal structural organisation without signs of cellular stress (cyst, outer retina undulation, etc.).

At 6 months, the serous retinal detachment is still present but is decreasing as the fluid is being reabsorbed by the retinal pigment epithelium.

At 12 months, the perifoveal retina is well reattached but there is still a slight foveal elevation.



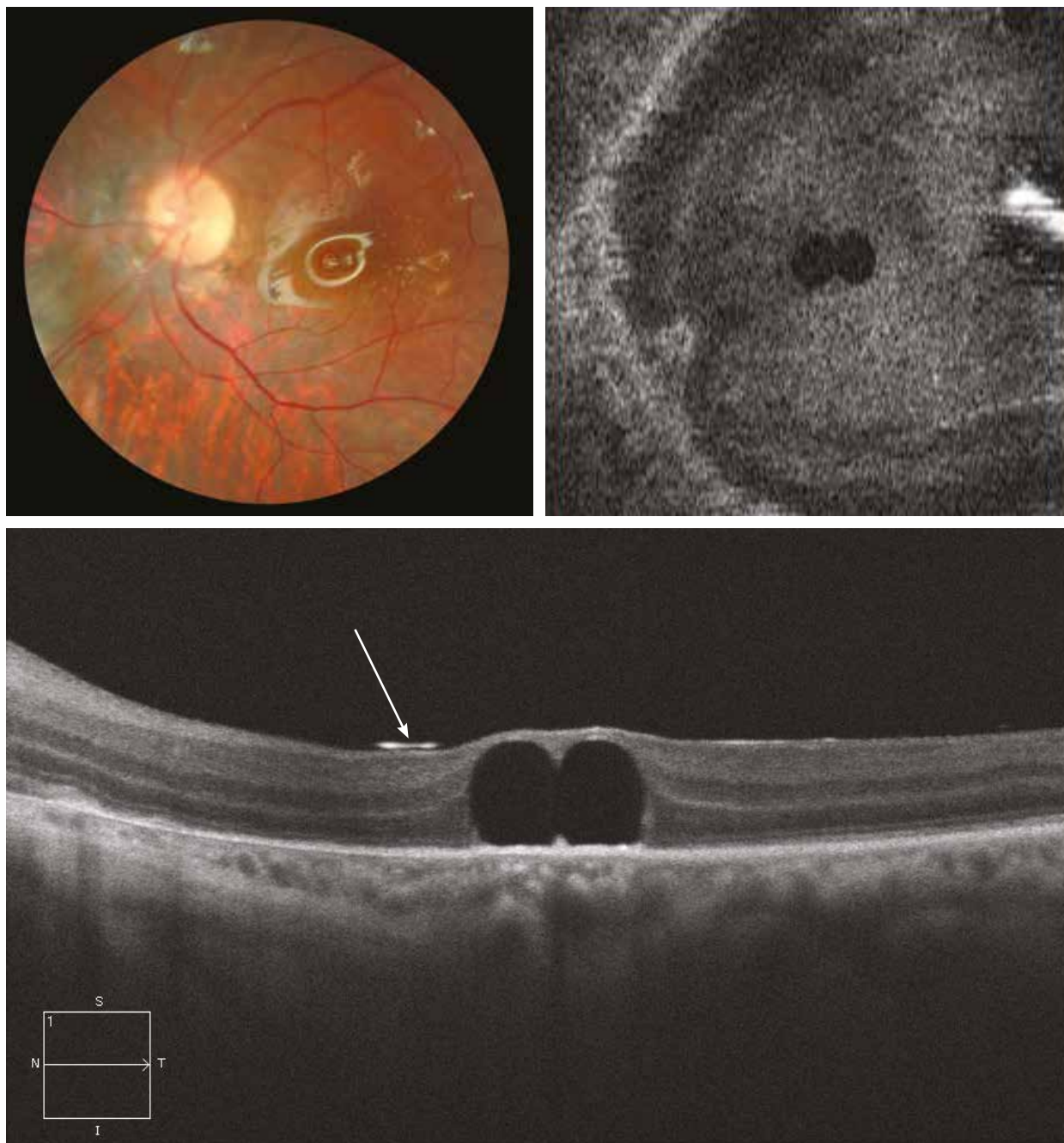
Subretinal perfluorocarbon liquids

Short-term tamponade with perfluorocarbon liquids (PFCLs) is used to treat complicated retinal detachments. PFCLs are removed at the end of the surgery. Sometimes, the exchange may be incomplete and small droplets of PFCL migrate under the retina and become encysted, often beneath the macular region.

Here, the colour image shows two small subretinal droplets of PFCL in the centromacular region of an eye filled with silicon.

The OCT section shows the two droplets beneath the centrofoveal retina. Note the silicon meniscus is visible as a hyperreflective line (arrow).

The “en-face” OCT shows the two small droplets of PFCL.



10. Inflammatory diseases

- 10.1. Multiple evanescent white dot syndrome (MEWDS)**
- 10.2. Acute multifocal placoid pigment epitheliopathy (AMPPE)**
- 10.3. Serpiginous choroiditis**
- 10.4. Harada's disease**

Multiple evanescent white dot syndrome (MEWDS)

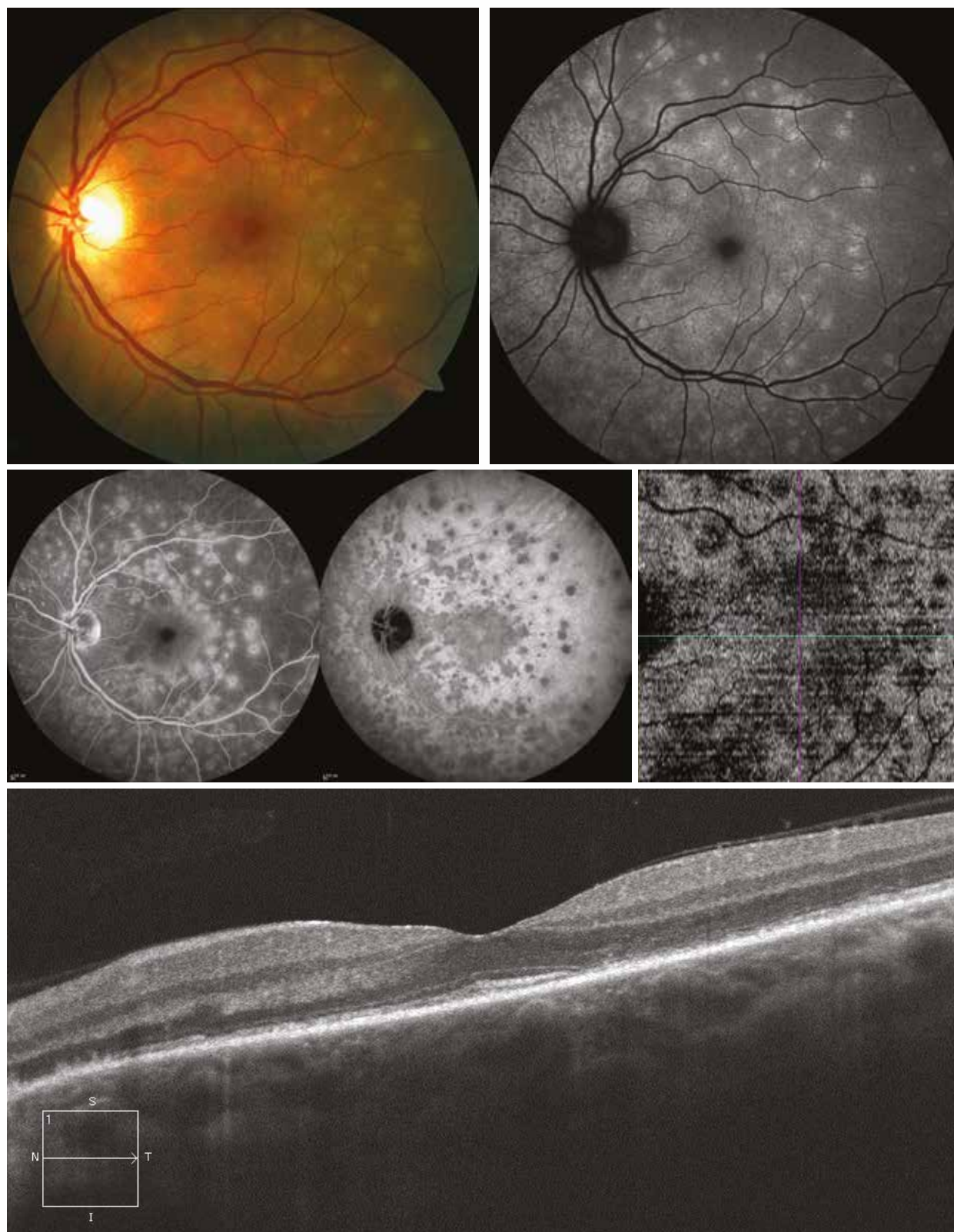
MEWDS is a benign retinal inflammatory disease of unknown origin, affecting women between 20 and 50 years.

The loss of visual acuity is moderate and the fundus examination shows discrete yellowish dots at the posterior pole and the mid-peripheral retina.

The autofluorescence image shows numerous hyperautofluorescent lesions corresponding to the hypocyanescent lesions typically observed on ICG angiography.

These lesions are hyperfluorescent on fluorescein angiography.

On the OCT section, the associated signs are limited. The outer retina and RPE are remodelled, with interruption of the IS/OS boundary line in some restricted areas. In contrast, on the “en-face” OCT focalised on the outer retina, there are clearly hyporeflective areas corresponding to the lesions shown by ICG and autofluorescence.



Acute Multifocal Placoid Pigment Epitheliopathy (AMPPE)

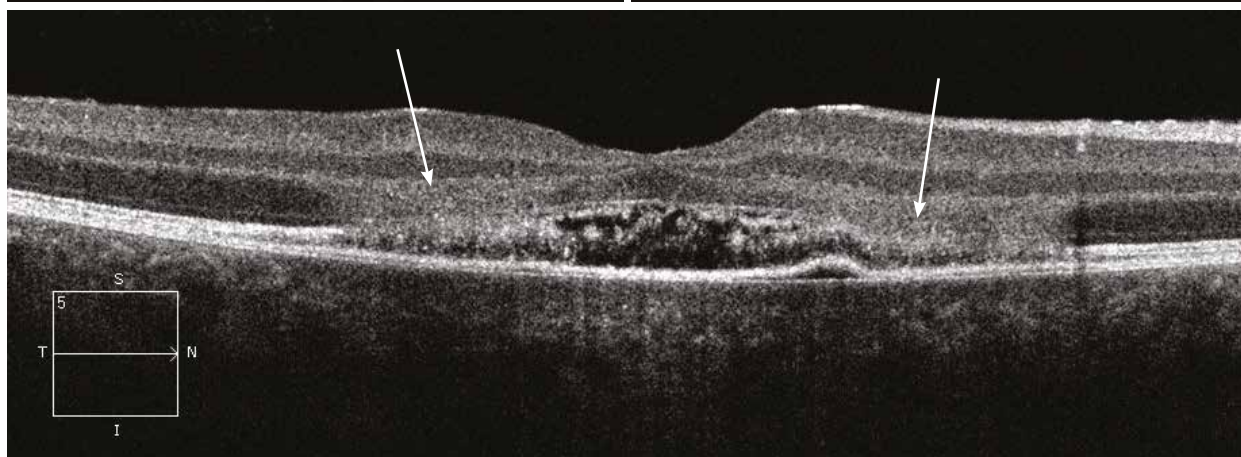
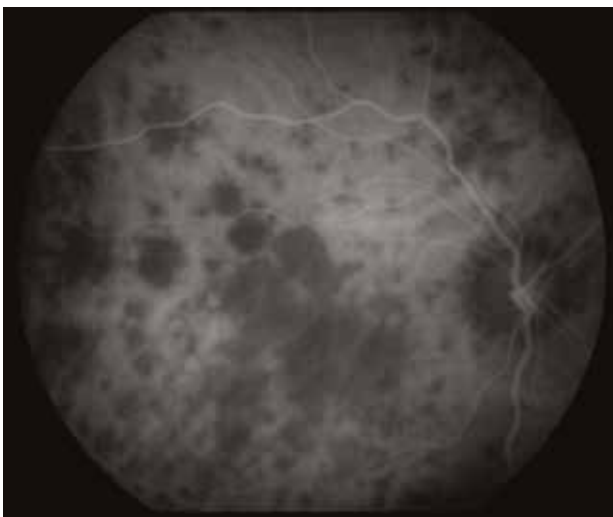
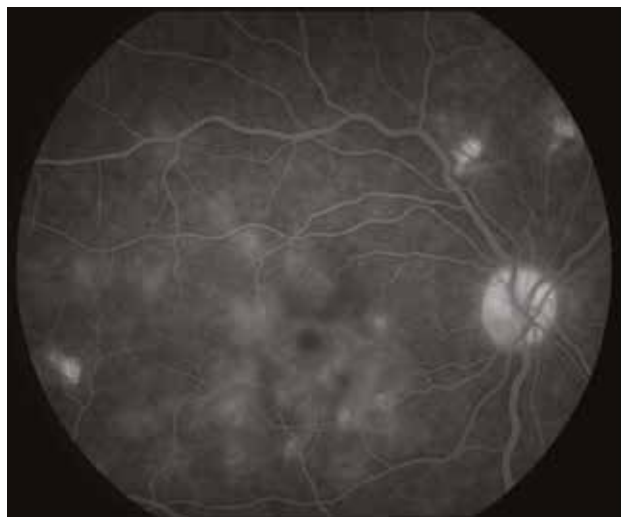
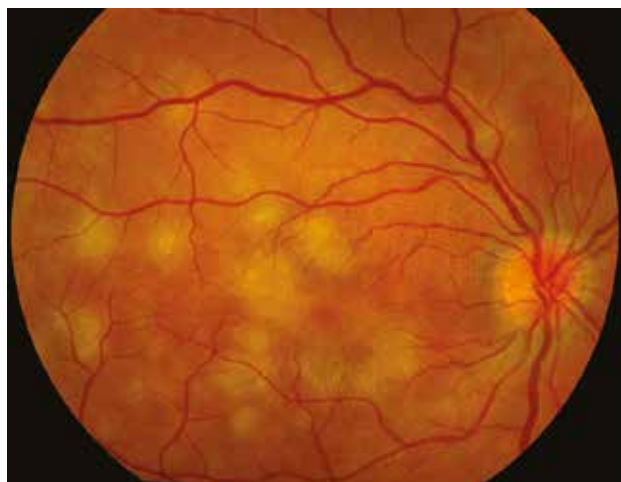AMPPE is an inflammatory disease of the retina affecting young subjects between the second and fourth decades of life.

The fundus examination reveals randomly scattered, flat multifocal creamy white or yellow plaques at the level of the retinal pigment epithelium with indistinct margins, predominantly in the posterior pole. Lesions are either uni- or bilateral, and the visual impairment is related to the position of the plaques.

Usually, the fluorescein angiography reveals more lesions than clinically observed, shown as hypo- then hyperfluorescent lesions.

The ICG angiography shows numerous hypocyanescent lesions throughout the sequence.

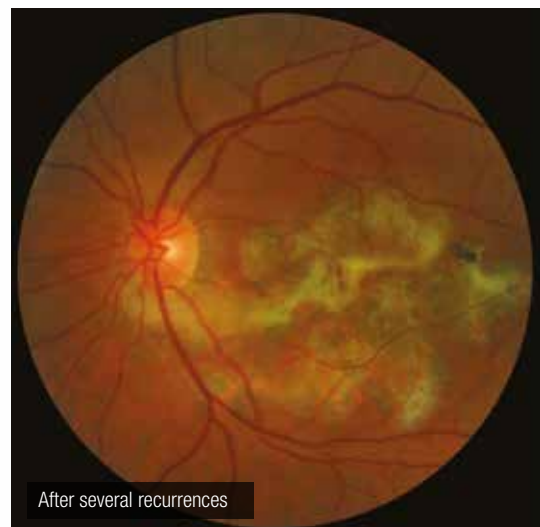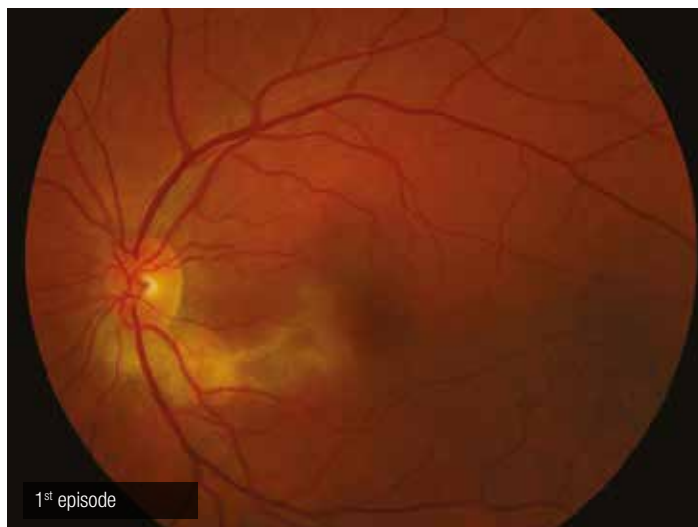OCT enables to localise the lesions in the outer nuclear layer. Plaques appear hyperreflective (arrows). A small SRD is frequently associated at the acute phase.

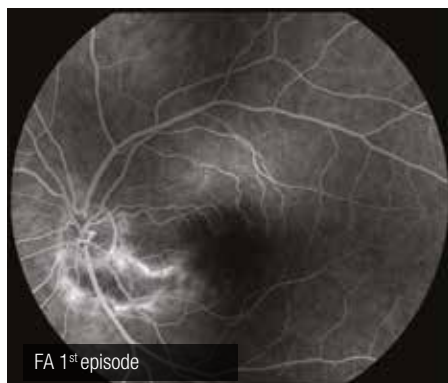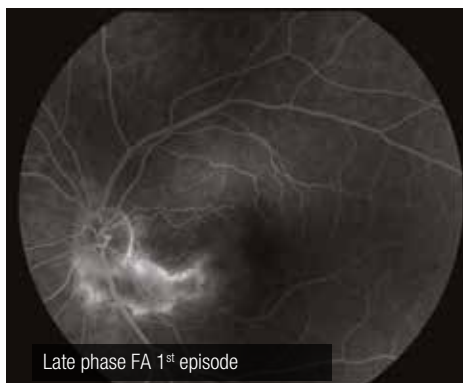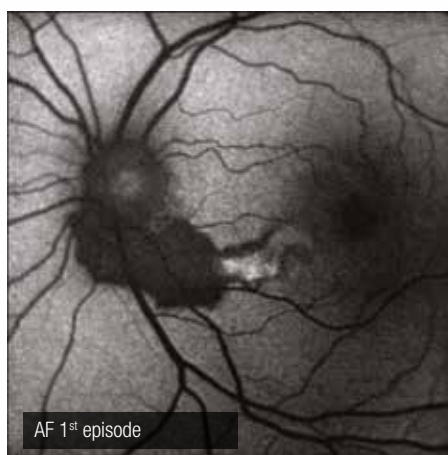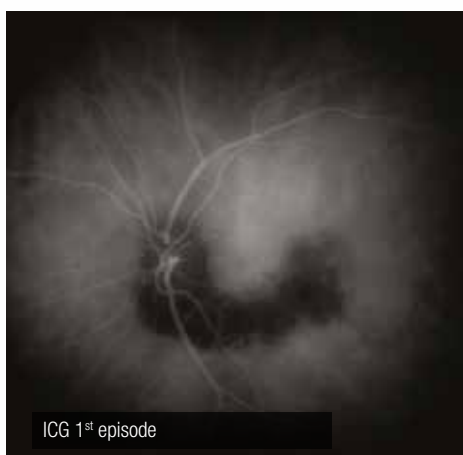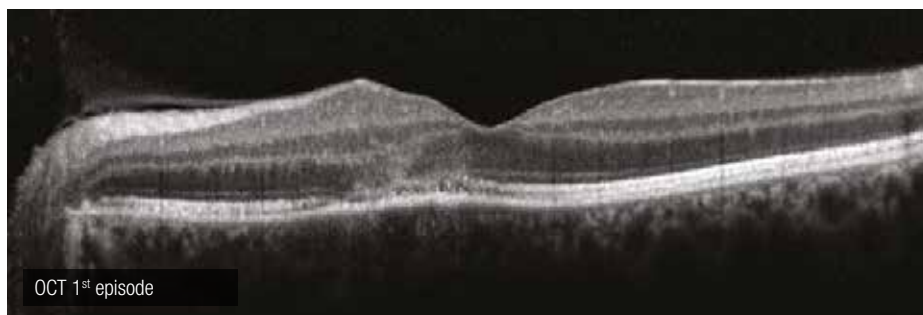
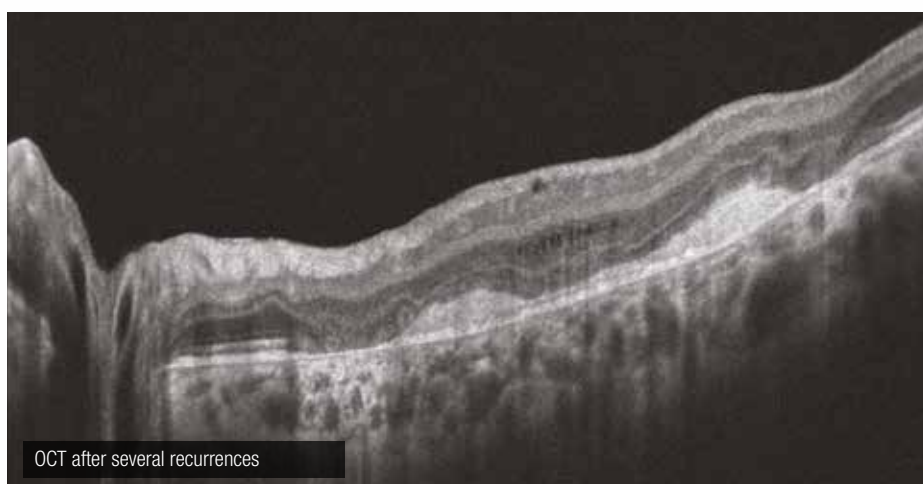


Serpiginous choroiditis

Serpiginous choroiditis is a rare and recurrent inflammation disorder of the outer retina and choroid, leading to extensive chorioretinal atrophic scars in a jigsaw-puzzle configuration. It is of unknown origin. Visual signs are present only when the macula is affected as in the present case. Indeed, the colour image reveals the signs of a previous undiagnosed episode, in contact of the papilla and sparing the macula. This female patient presents a typical recurrence contiguous with previous lesions. The autofluorescence clearly shows the hypoautofluorescent old scar and the current hyperautofluorescent lesion. Fluorescein angiography reveals a window effect at the scar and a masking effect at the choroiditis, which fills at the late phase. On the ICG angiography, both active and scarred lesions remain hypocyanescent. Finally, on the OCT image, there is a juxtamacular hyperreflectivity in the outer nuclear layer, corresponding to active choroiditis.

After several recurrences, extensive chorioretinal atrophic scars are observed. The OCT shows destructive lesions within the outer retina and the RPE, while the inner retina is barely affected.



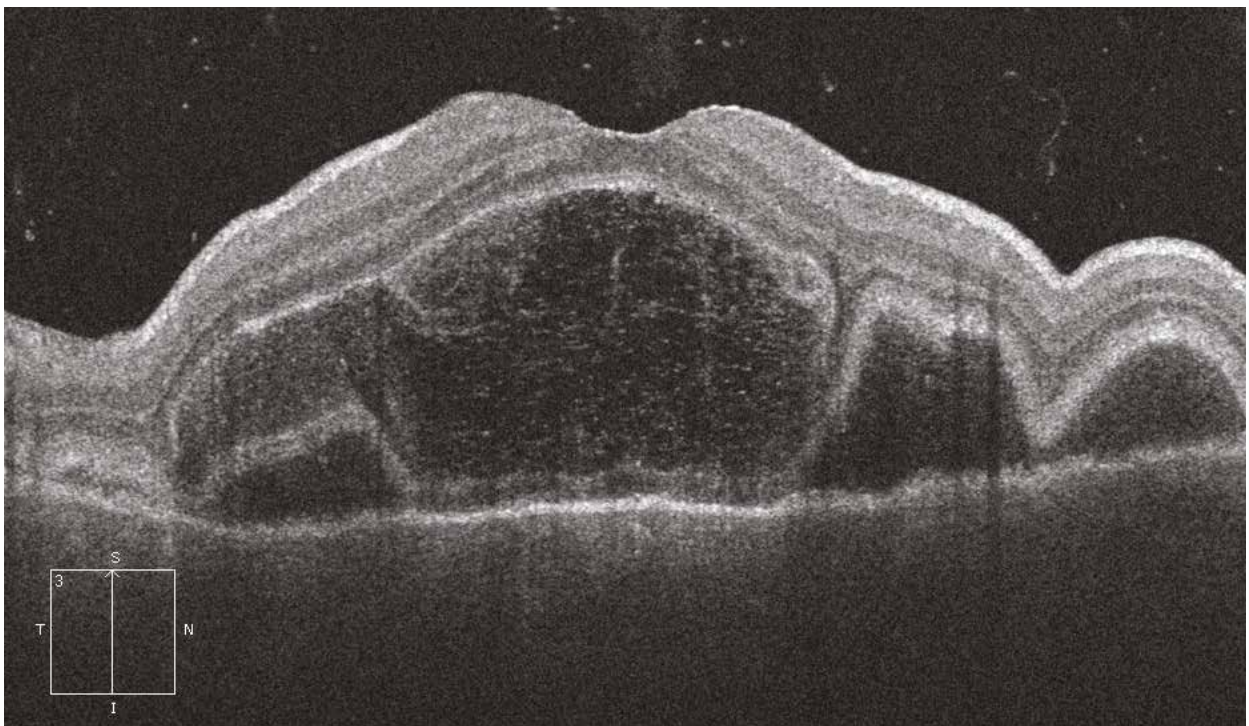
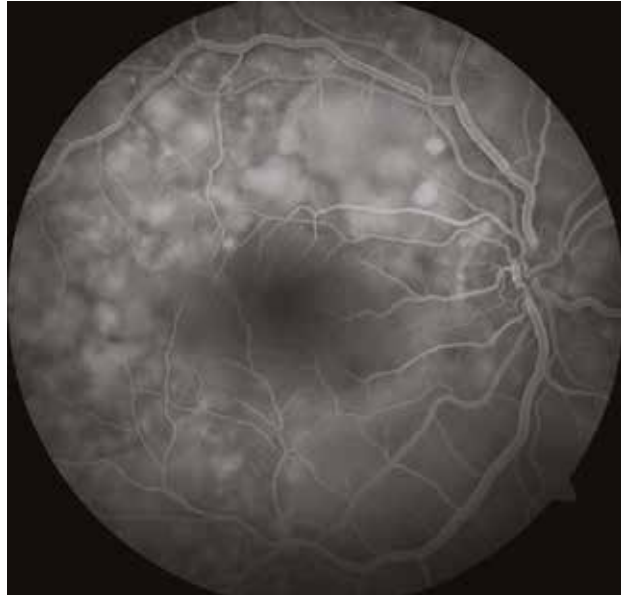
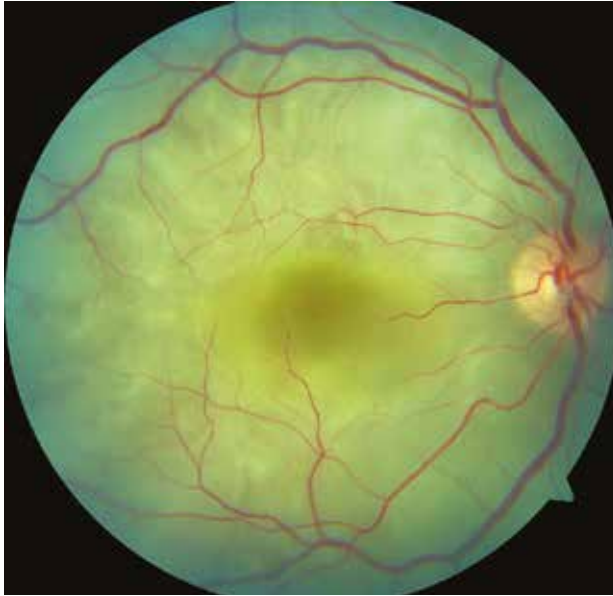FA 1st episodeLate phase FA 1st episodeAF 1st episodeICG 1st episodeOCT 1st episode

OCT after several recurrences

Vogt-Koyanagi-Harada's disease

During the acute phase of the disease, the most typical ocular sign is the presence of multiple serous retinal detachments (colour image) filling during angiography. These SRDs are associated with moderate hyalitis, vasculitis and papillitis.

The OCT reveals multiple SRDs with subretinal septa, leading to a polylobed pattern quite typical of the disease.



11. Chloroquine-induced maculopathy

Chloroquine-induced maculopathy

Case 1

Antimalarial intoxication is characterised by a bilateral, and relatively symmetrical, alteration of the macula. The lesions start in the perimacular area, leading to the classic bull's-eye pattern at the late stage, as clearly shown on autofluorescence.

In the case presented here, an annular disappearance of the perimacular autofluorescence is observed, predominantly visible in the inferior region, due to RPE atrophy (red arrow) contrasting with annular hyperautofluorescence in the peripheral region (yellow arrow).

The OCT section reveals a disappearance of the outer retina around the fovea (white arrows), leading to the characteristic “flying saucer” pattern.

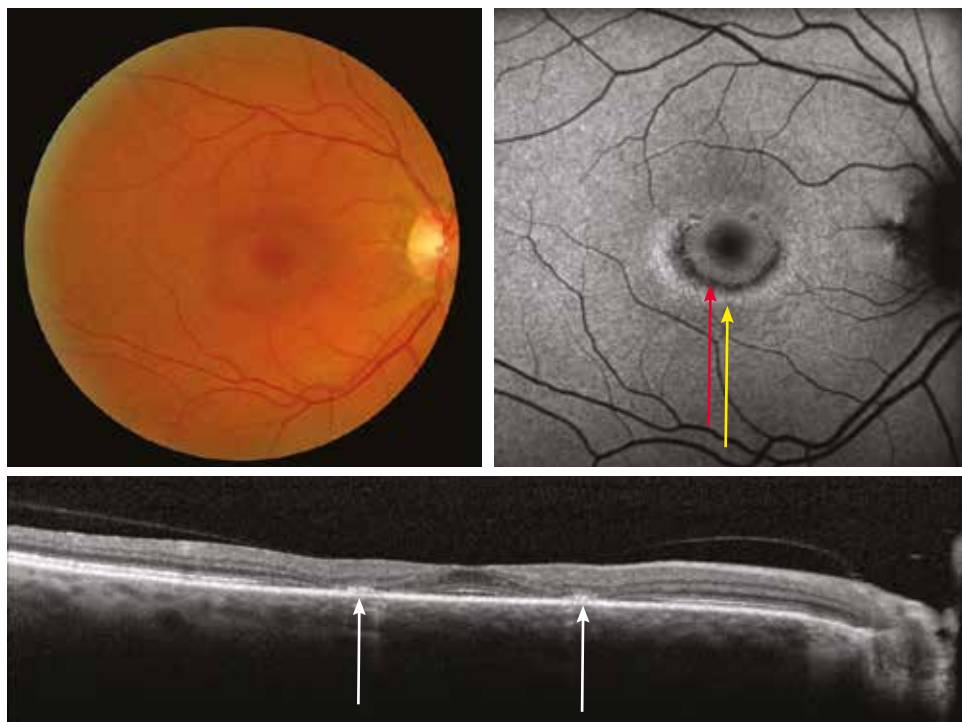
Case 2

Prior to the bull's-eye stage, during follow-up of long-term treatment, early signs of intoxication to antimalarial agents can be identified on OCT images while both fundus examination and autofluorescence imaging are not contributive.

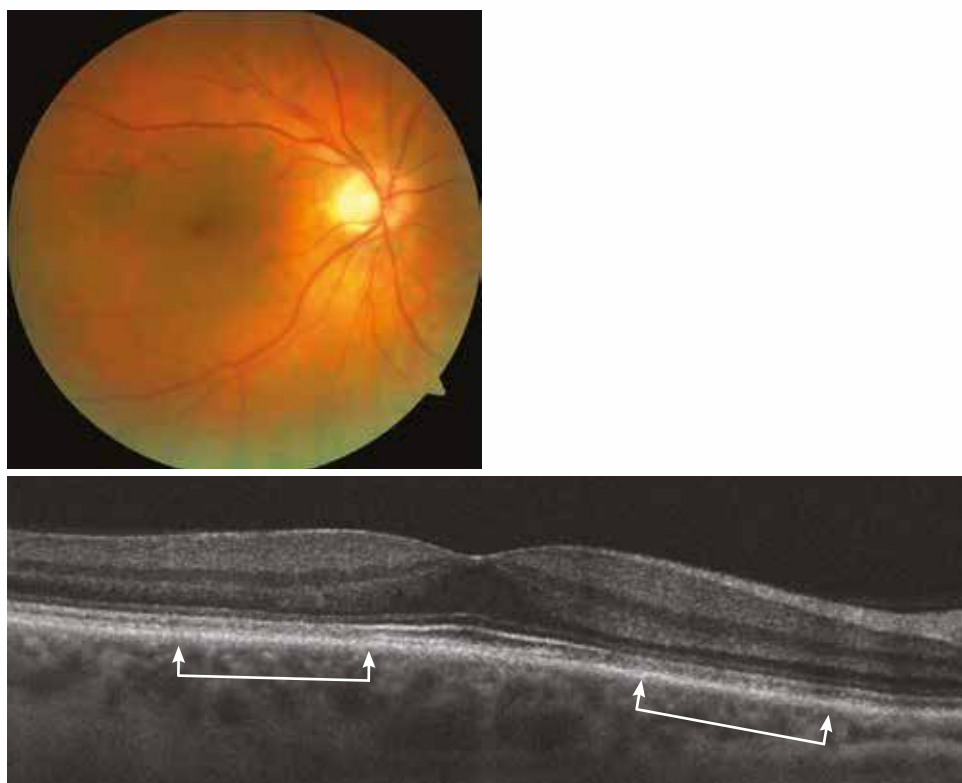
Here, the boundary line between the inner and outer segments of the photoreceptors is altered without being interrupted (section between arrows).

In addition, the central visual field and the multifocal ERG are abnormal.

Case 1



Case 2



12. Tumours

12.1. Choroidal naevus

12.2. Choroidal melanoma

12.3. Choroidal metastasis

12.4. Choroidal osteoma

Choroidal naevus

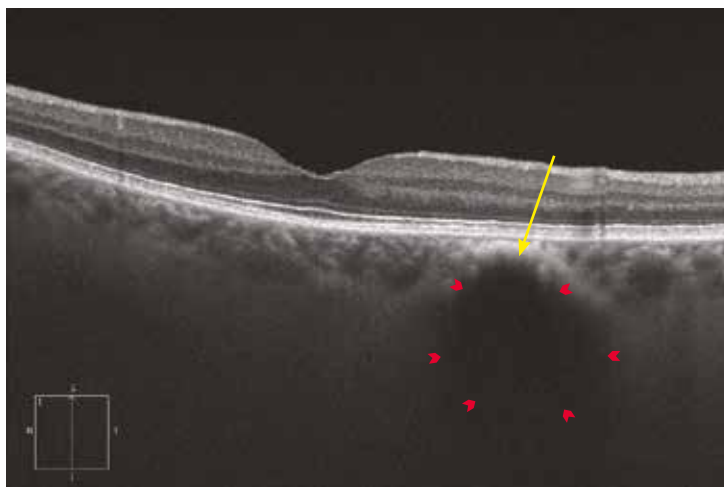
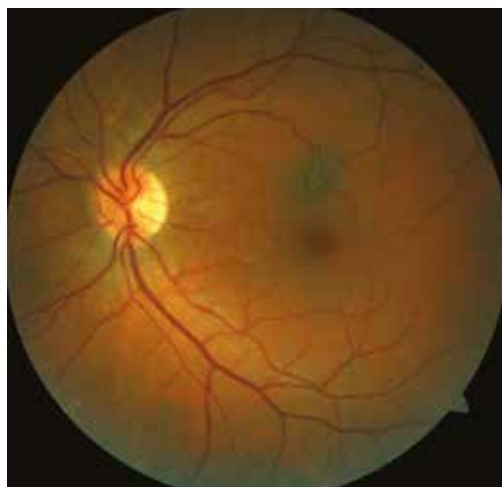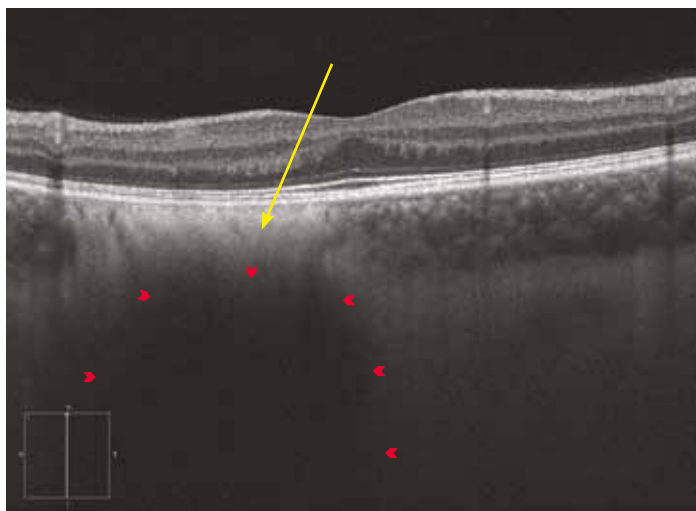
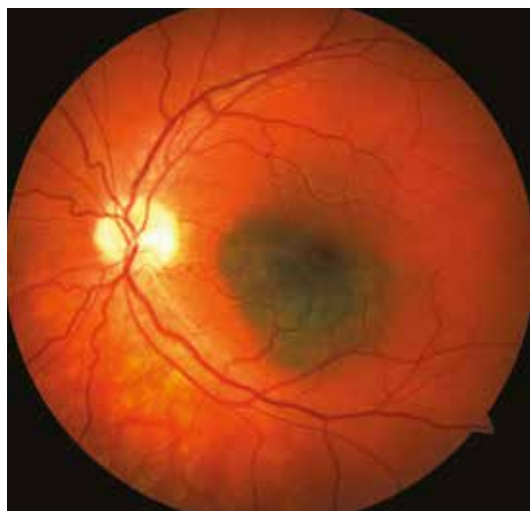The OCT analysis is a complement to the classical imaging of choroidal tumours. It enables the analysis of both the overlying retina and the choroid. For choroid analysis, the EDI mode is very relevant.

The monitoring of a naevus resides to look for a possible transformation into a choroidal melanoma. The risk factors are: thickness greater than 1.5 mm (2 mm in B-scan ultrasound), presence of subretinal fluid (not specific), presence of orange pigment, location close to the papilla and visual disturbances.

OCT enables screening for the first two above factors: lesion thickness and presence of subretinal fluid.

Typically, in the case of a pigmented tumour, OCT shows a hyperreflective line at the RPE/Bruch's membrane/choriocapillaris complex (yellow arrow). Because of a shadow effect produced by the pigment, the naevus appears as a hyporeflective lesion within the choroid (red arrows). The thickness may be difficult to measure because the image may be out of the field of the device. However, it should be kept in mind that for the smallest tumours OCT achieves measurements around 50% thinner than with B-scan ultrasound.

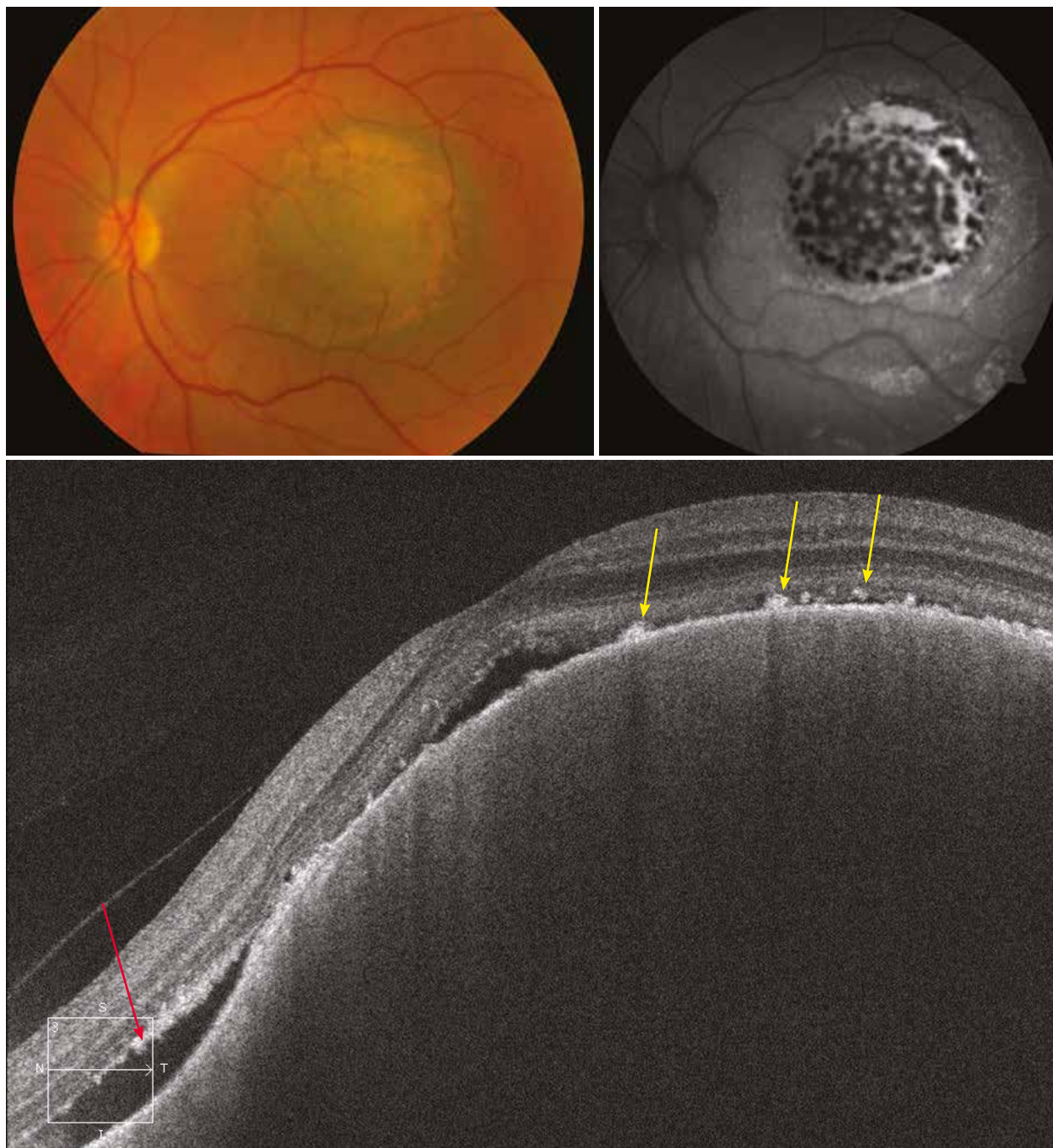
In both cases presented here, the overlying retina is normal.



Choroidal melanoma

When pigmented, the OCT appearance of a melanoma is comparable to that of a naevus regarding the shadow effect in the choroid and the possible presence of a SRD. In contrast, other abnormalities can be detected: greater thickness of the lesion, lipofuscin subretinal deposits corresponding to orange pigment, RPE atrophy, disorganised aspect of photoreceptors (irregular, elongated and oedematous) and overall disappearance of the different layers of the outer retina depending on the duration of the disease.

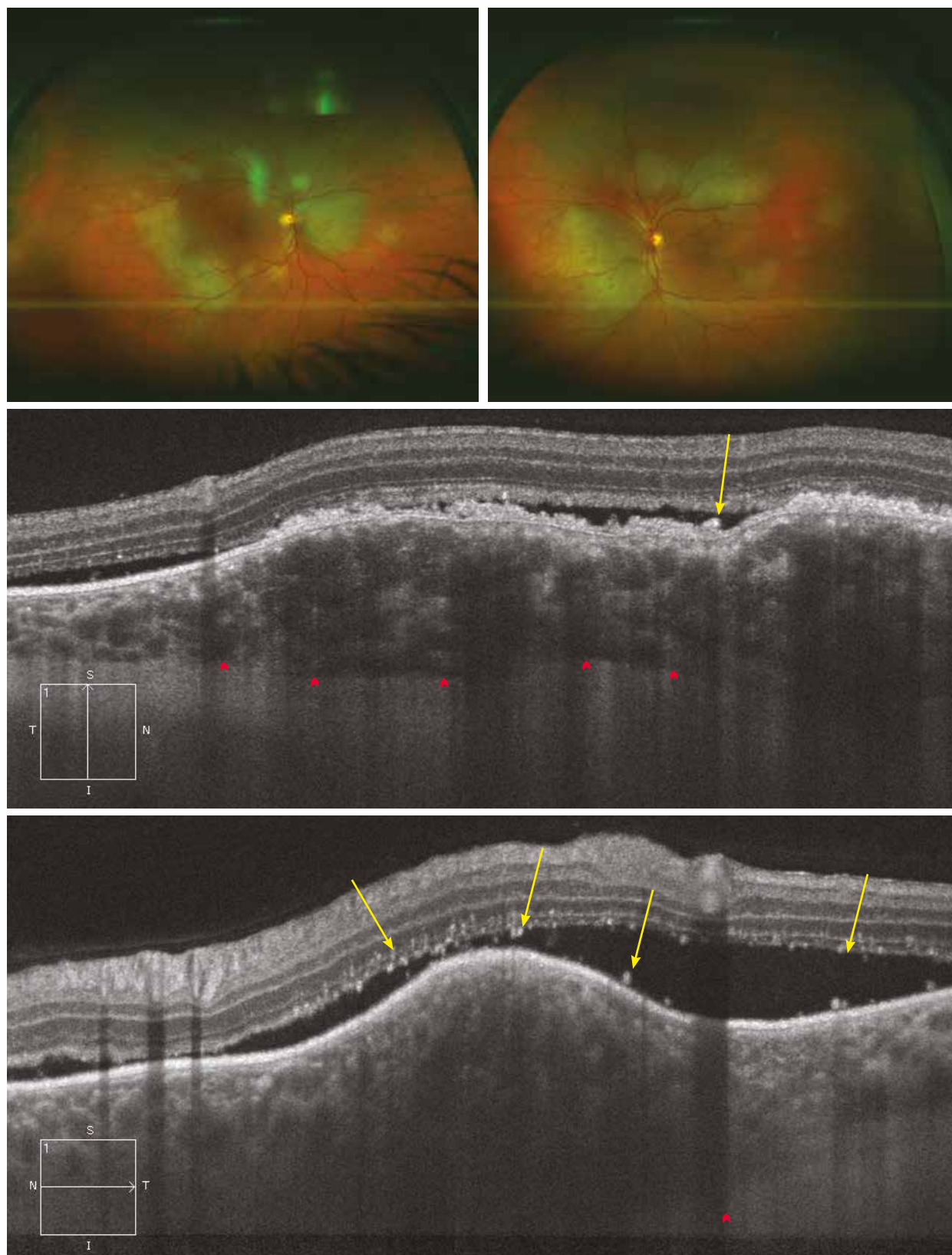
In the case presented here, the colour image shows a large choroidal melanoma with orange pigmentation. The autofluorescence image shows a leopard-like aspect corresponding to the orange pigment. On the OCT, in addition to the hyporeflectivity related to the shadow effect in the choroid region, there are a SRD, subretinal deposits (yellow arrows), RPE atrophy and a remodelling of photoreceptors (red arrow). The thickness overwhelms the capacities of the device to be measured.



Choroidal metastasis

The wide-field colour images show a multitude of metastases in both eyes.

EDI mode OCT is useful for the diagnosis and follow-up of choroidal metastases. The doming of the RPE and of the neurosensory retina associated with a SRD are shown. The reflectivity of the tumour is variable, but most often hyporeflective. There are also hyperreflective elements corresponding to subretinal deposits (yellow arrows). Here, the inner retina is preserved, but intraretinal oedema may develop. The outer retina adjacent to the tumour is remodelled with an atrophic RPE. Finally, the posterior limit of the tumour is readily visible, enabling the size of the tumour to be measured (red arrows).



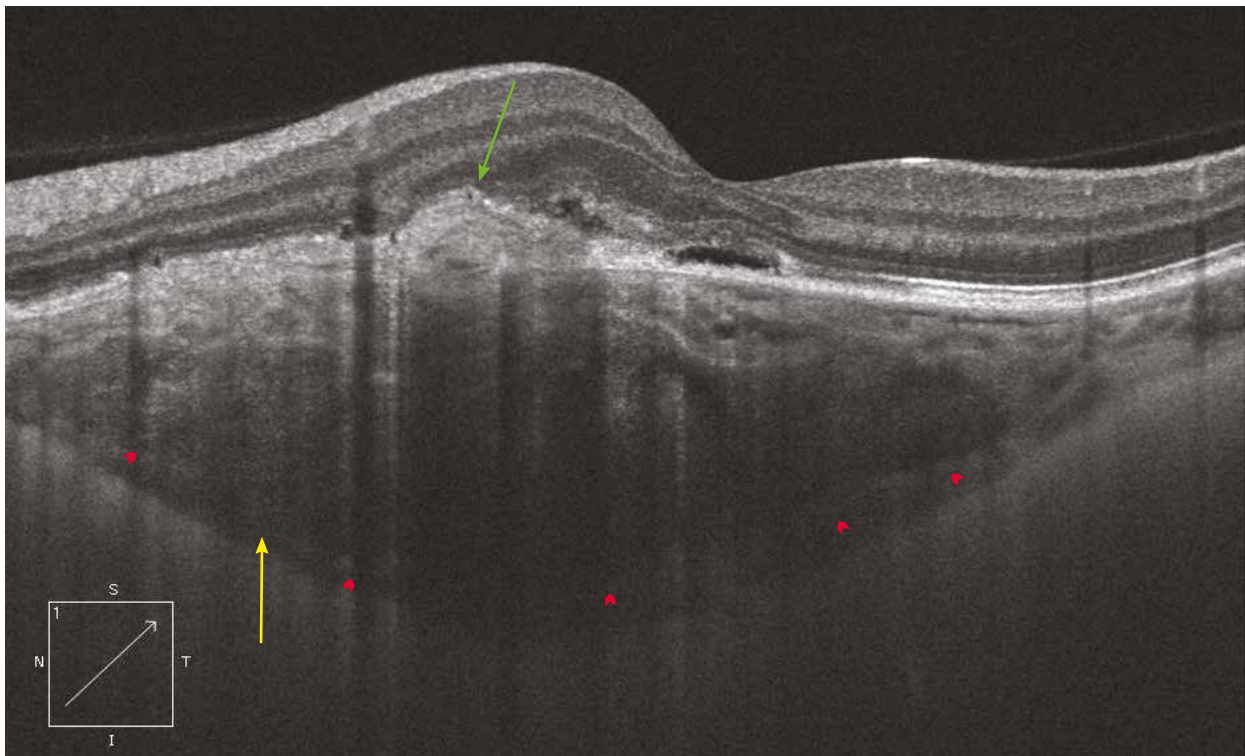
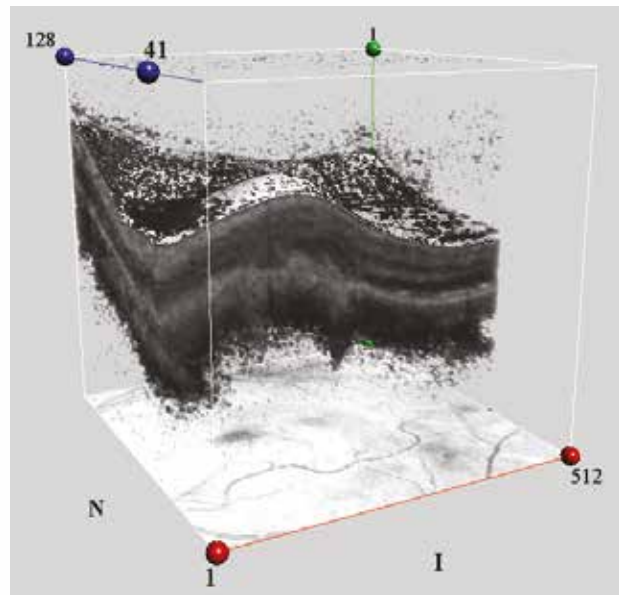
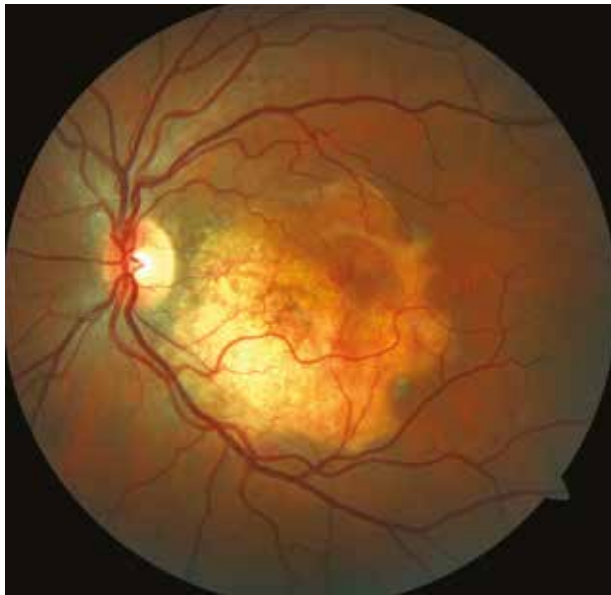Choroidal osteoma

Choroidal osteoma is a rare bone tumour. At the beginning, it is yellowish-orange, but can appear white as it becomes decalcified (as presented here). This decalcification is associated with a poor visual prognosis. It may be complicated by a SRD as well as by choroidal neovascularisation.

Here, the colour image shows a decalcified osteoma associated with pigment migrations and diffuse RPE atrophy.

Due to the decalcification, the entire tumour is easily visible on the OCT section (anterior and posterior margins) within the choroid as a moderately reflective lesion perfectly well delimited (solid red arrows). There is also a hyporeflective space that separates the tumour from the sclera (yellow arrow). The RPE-Bruch's membrane-choriocapillaris complex disappears in the protruding region into the neurosensory retina (green arrow). A limited SRD is observed beneath the overlying retina. Besides the external limiting membrane, which is interrupted, the different retinal layers are well preserved.

The 3D image clearly illustrates the protrusion of the lesion into the neurosensory retina.



Edition

Edited by:
Laboratoires Théa
12 Rue Louis Blériot
63000 Clermont-Ferrand - France
Tel: +33 (0)4 73 98 14 36

Carl Zeiss Meditec France SAS
100 Route de Versailles
78160 Marly-le-Roi - France
Tel: +33 (0)1 34 80 21 00

